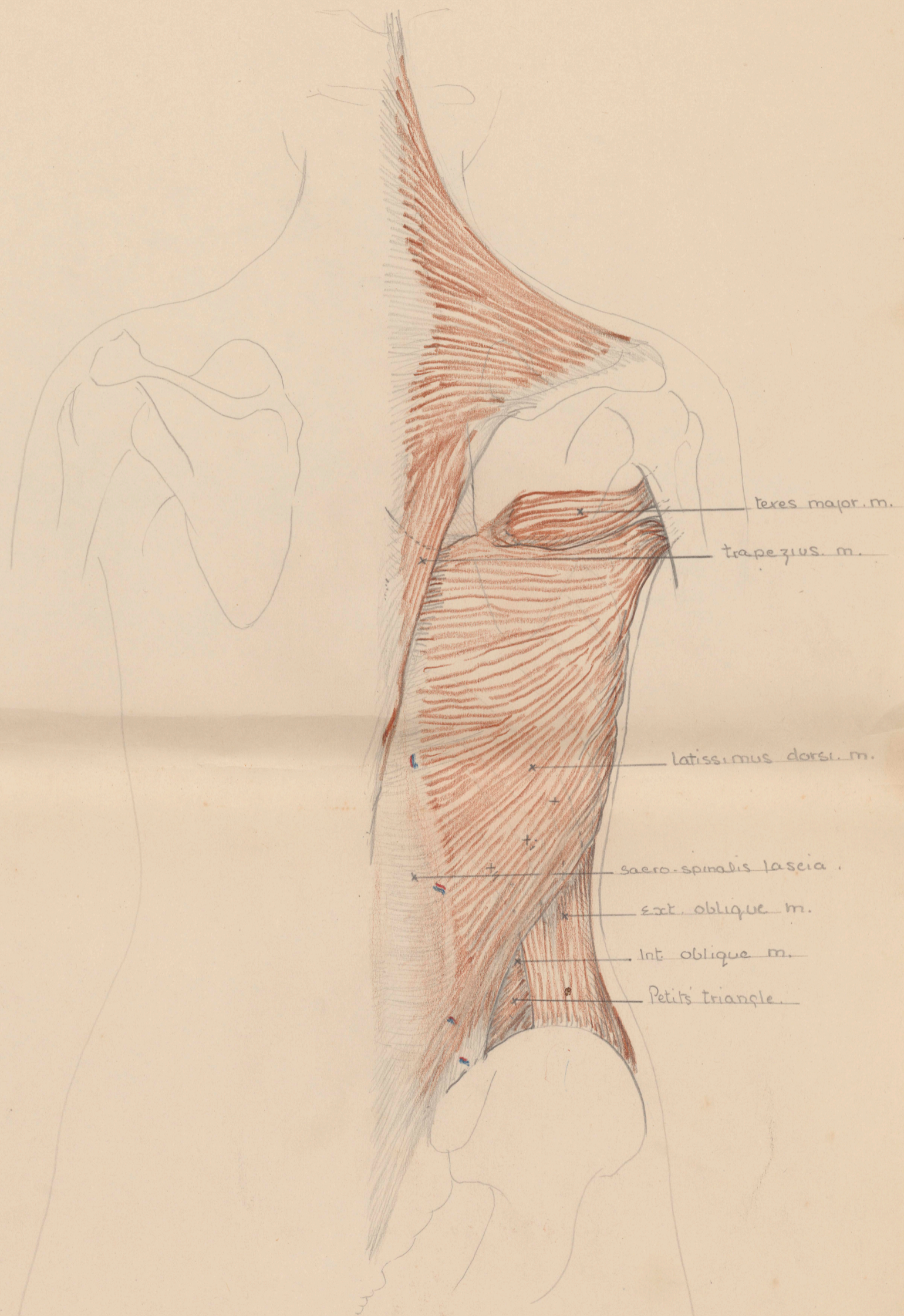

Teres major. m.

trapezius. m.

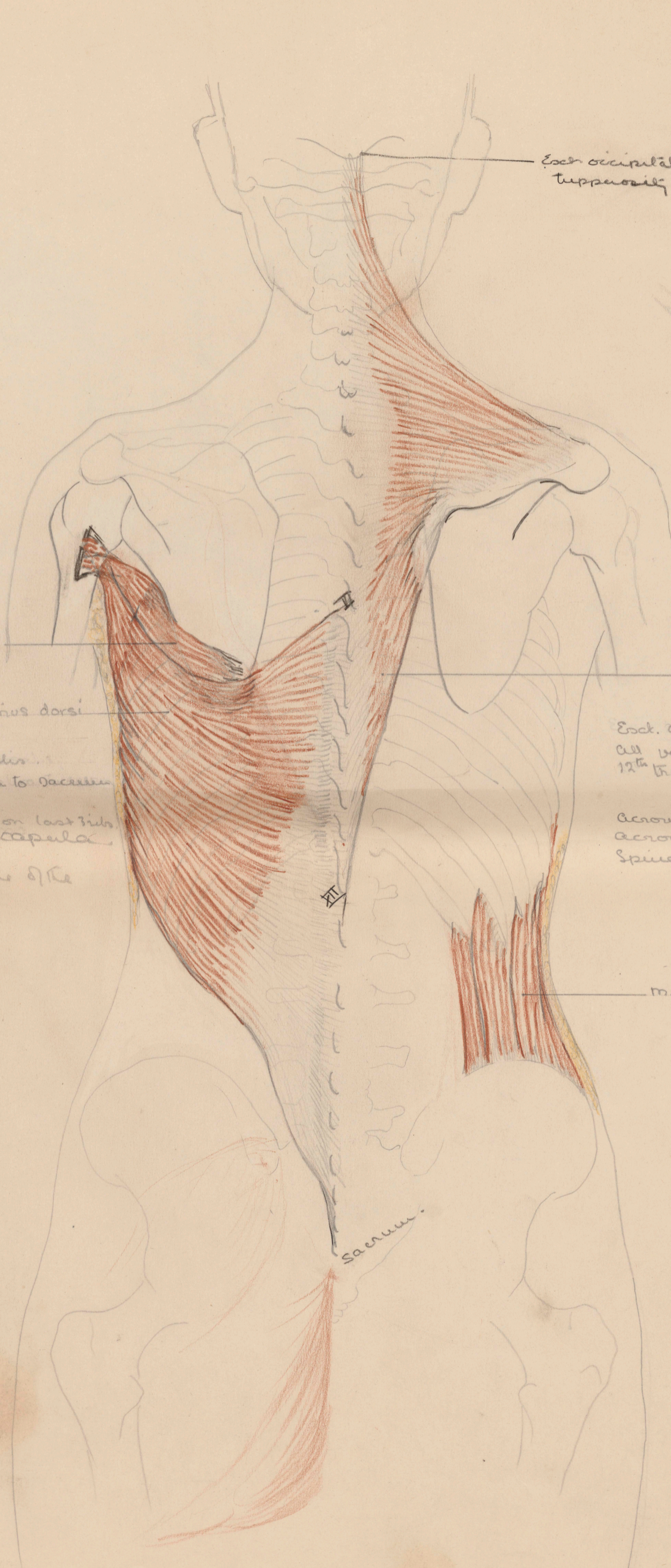
latissimus dorsi. m.

sacro-spinalis fascia.

ext. oblique m.

Int. oblique m.

Petit triangle.



Extr. occipital tuberosity

m. Teres major.

m. latissimus dorsi

m. trapezius.

origin.

Extr. occipital tuberosity.
All vertebra from first cervical to 12th Thoracic.

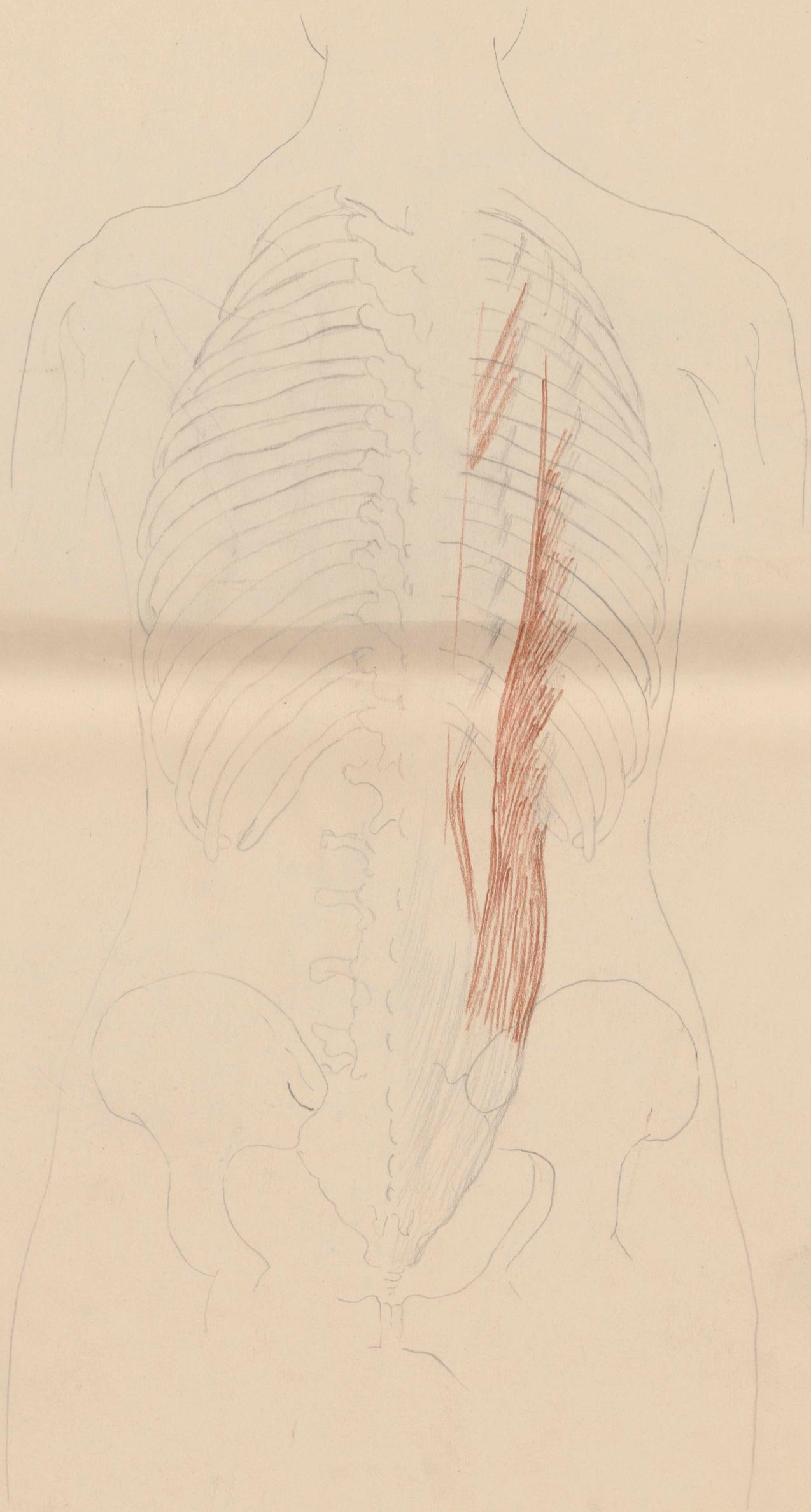
Insertions.

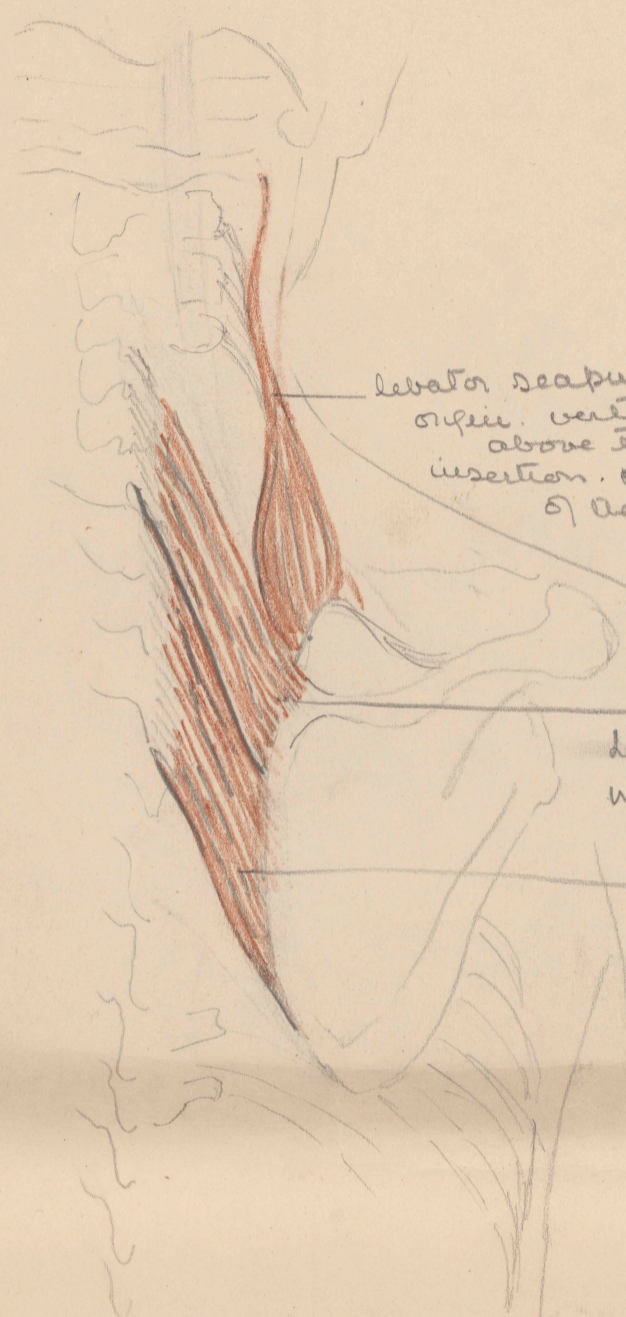
Acromial proximity of clavicle
acromion.
Spine of scapula.

origin.
Fascia humeroscapularis.
6th Thoracic vertebra to Sacrum
crest of ilium.
Fleshy dilatations on last ribs
& lower edge of scapula
Insertion.
The lesser tubercle of the
humerus.

m. external oblique.

Sacrum.





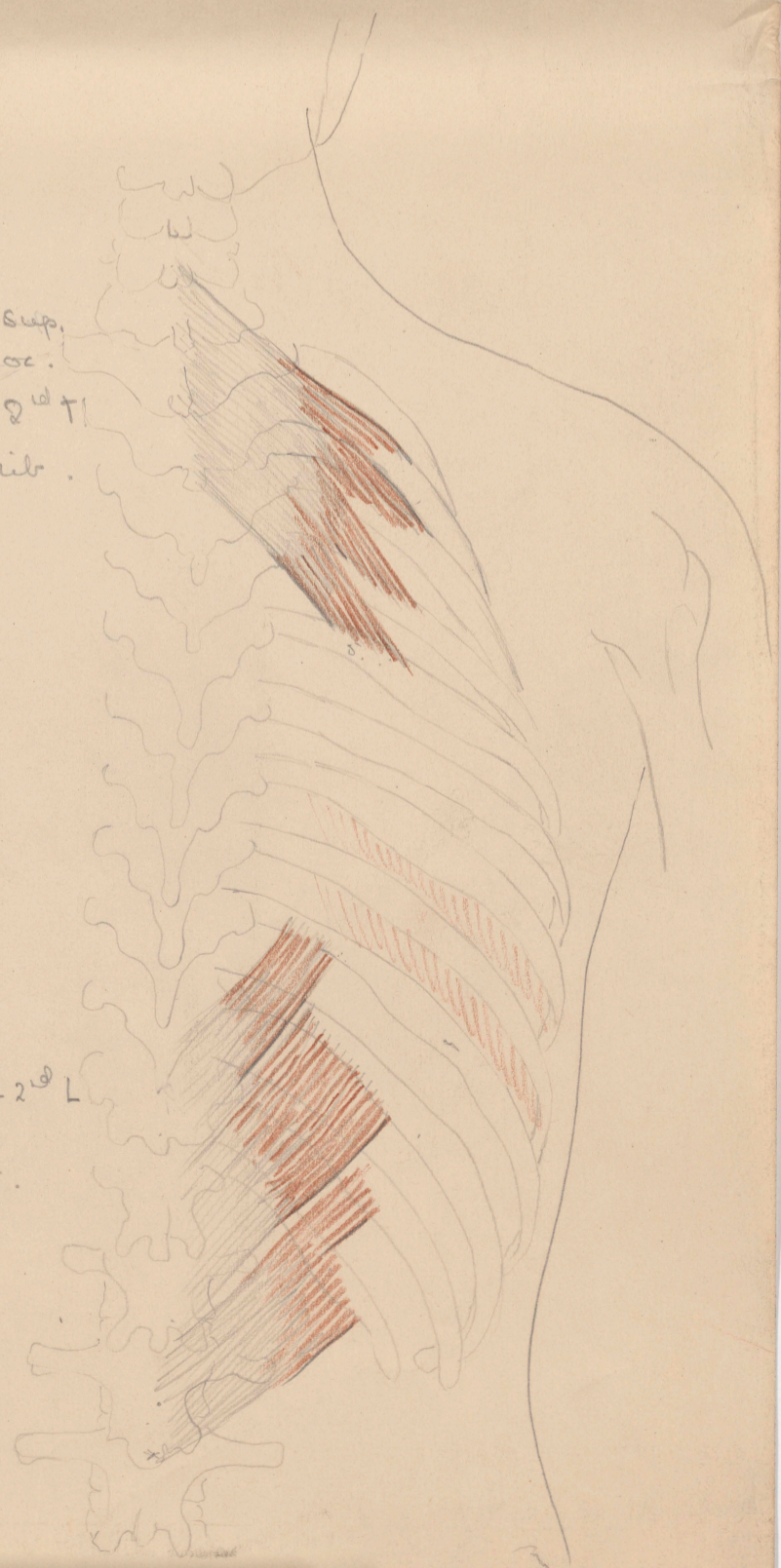
levator scapulae.
 origin. vertebral margin of the scapula
 above the ~~triangular~~ ^{trigonum} spinozi
 insertion. post. tubercles of the transverse processes.
 of the 1st - 4th C. vertebra.

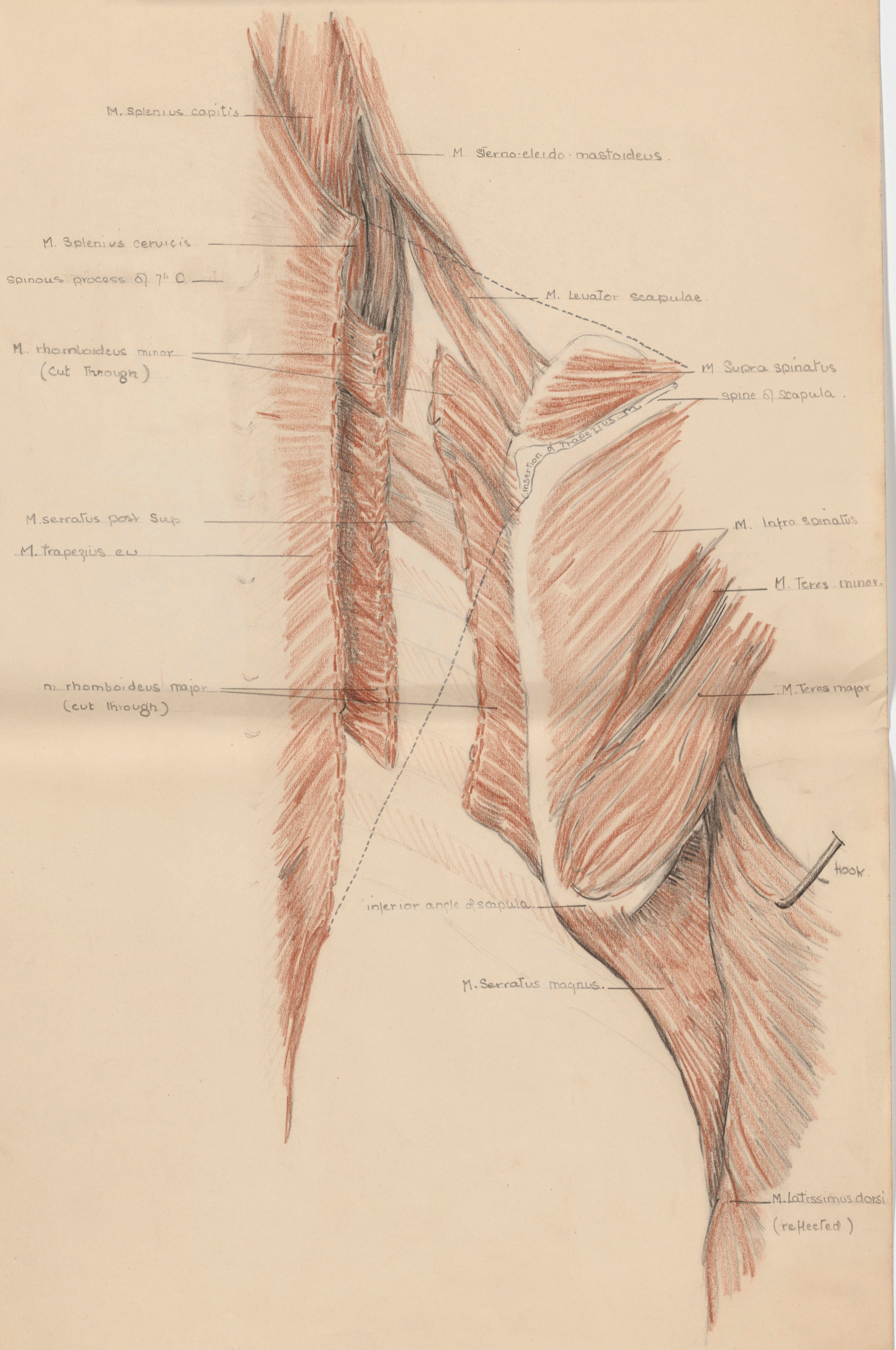
Rhomboides minor
 tip neck + 6th + 7th vertebra spinous processes
 insertion. vertebral border of scapula. & ~~trigonum~~ ^{trigonum} spinozi

Rhomboides major.
 Spinous processes. of 1st - 4th Thoracic vertebra.
 insertion. lower half of the vertebral border of the scapula

Serratus post. sup.
 origin - spinous proc.
 of 6th + 7th C. + 1st + 2nd T
 insertion. 2nd - 5th rib.

Serratus post. inf.
 origin. 10th - 12th T + 1st - 2nd L
 fascia lumbodorsalis.
 insertion. 9th - 12th rib.





M. Splenius capitis

M. Sternocleidomastoideus

M. Splenius cervicis

Spinous process of 7th C

M. Levator scapulae

M. rhomboideus minor
(cut through)

M. Supra spinatus
spine of scapula

insertion of Trapezius m.

M. serratus post Sup

M. Infra spinatus

M. Trapezius ev

M. Teres minor

M. rhomboideus major
(cut through)

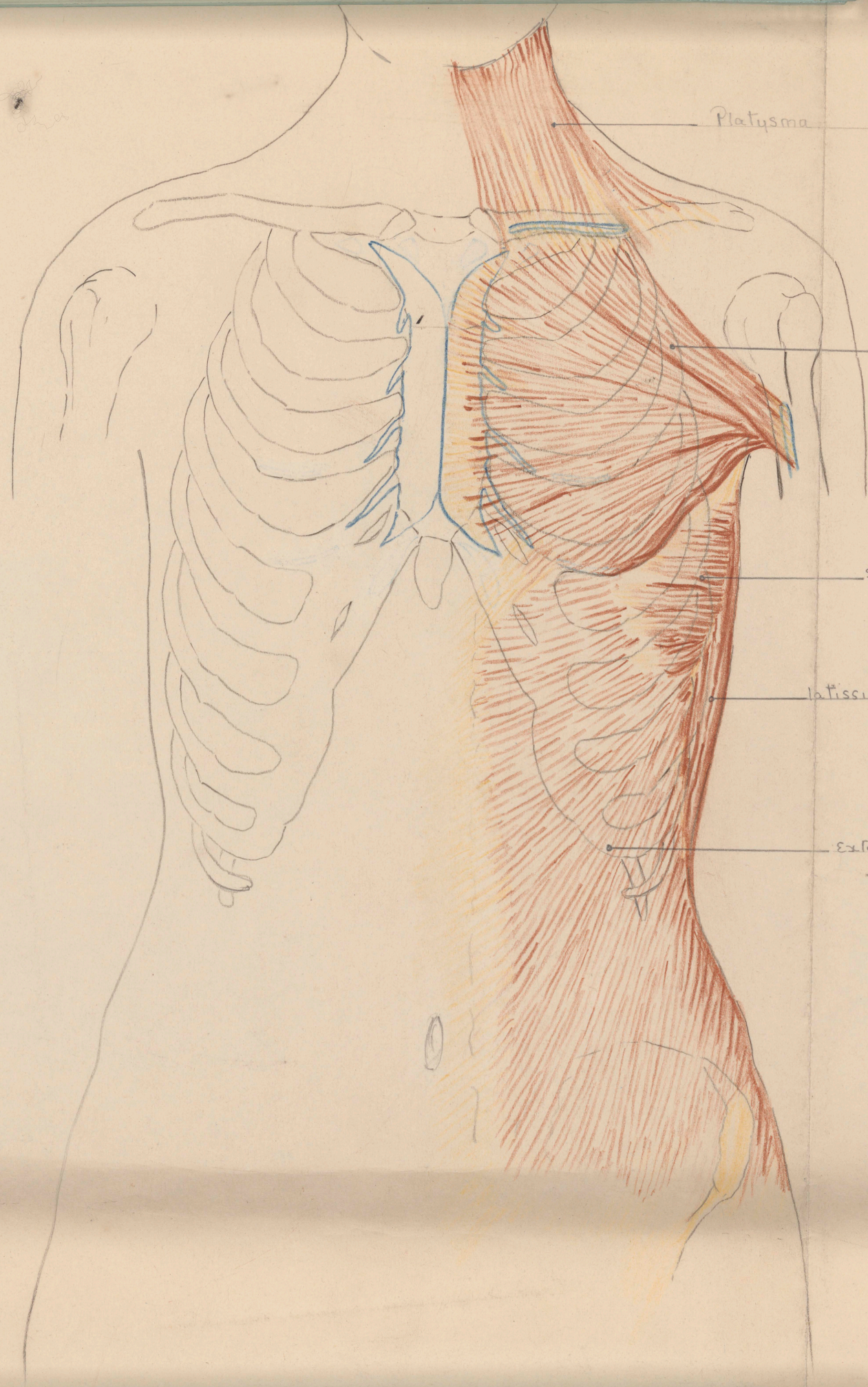
M. Teres major

inferior angle of scapula

hook

M. Serratus magnus

M. latissimus dorsi
(reflected)



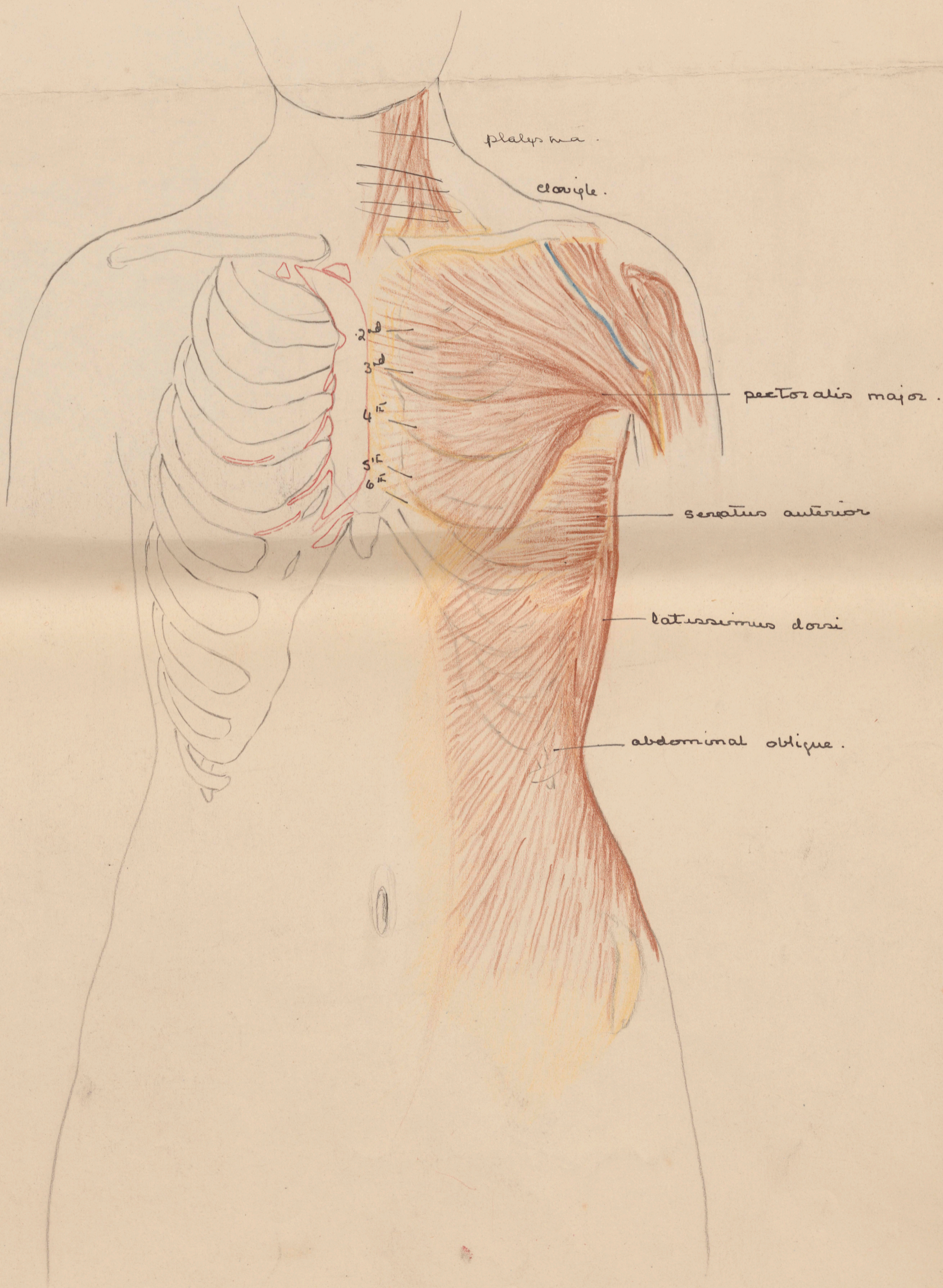
Platysma

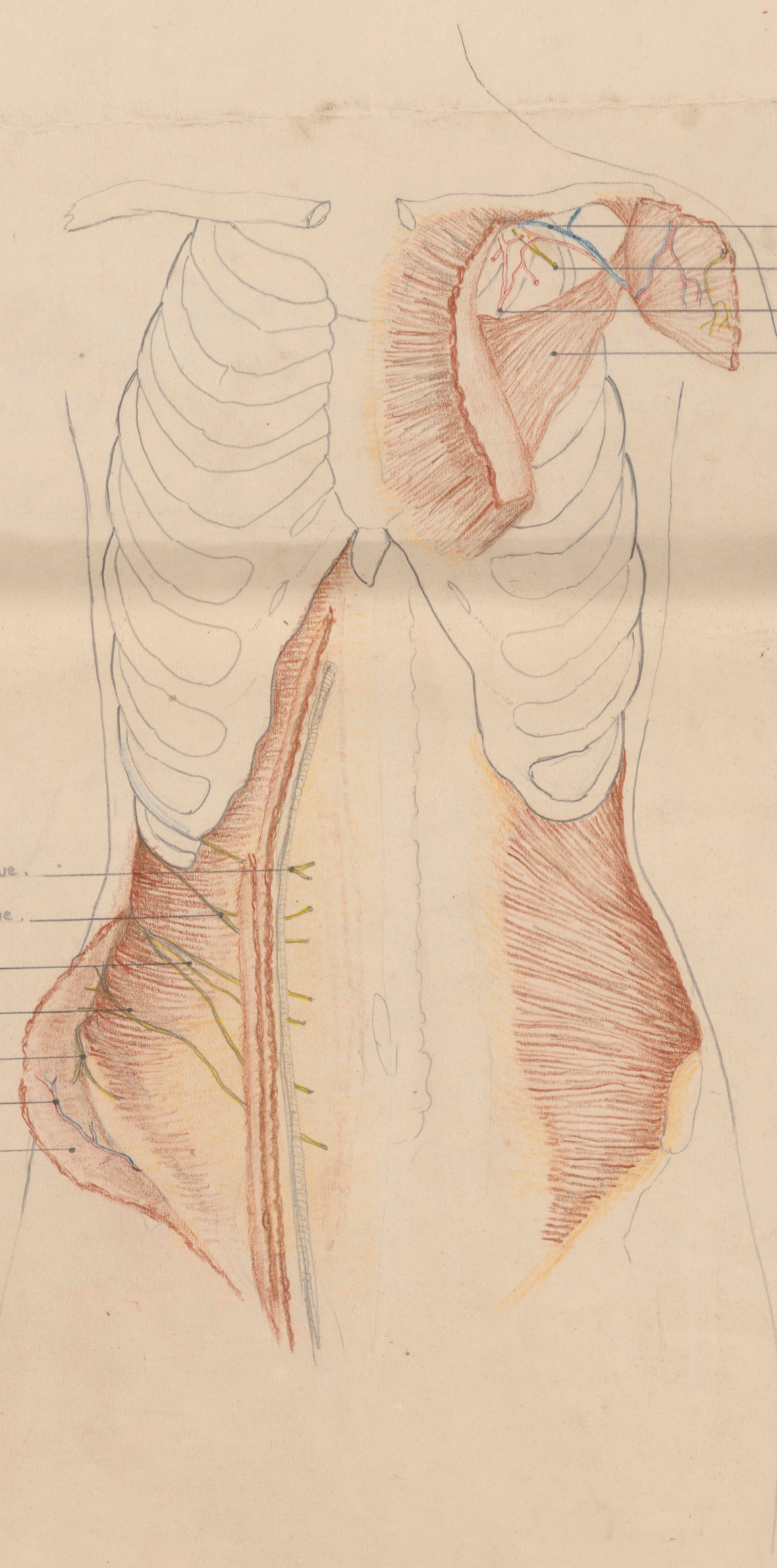
Pectoralis major.

Serratus anterior

latissimus dorsi

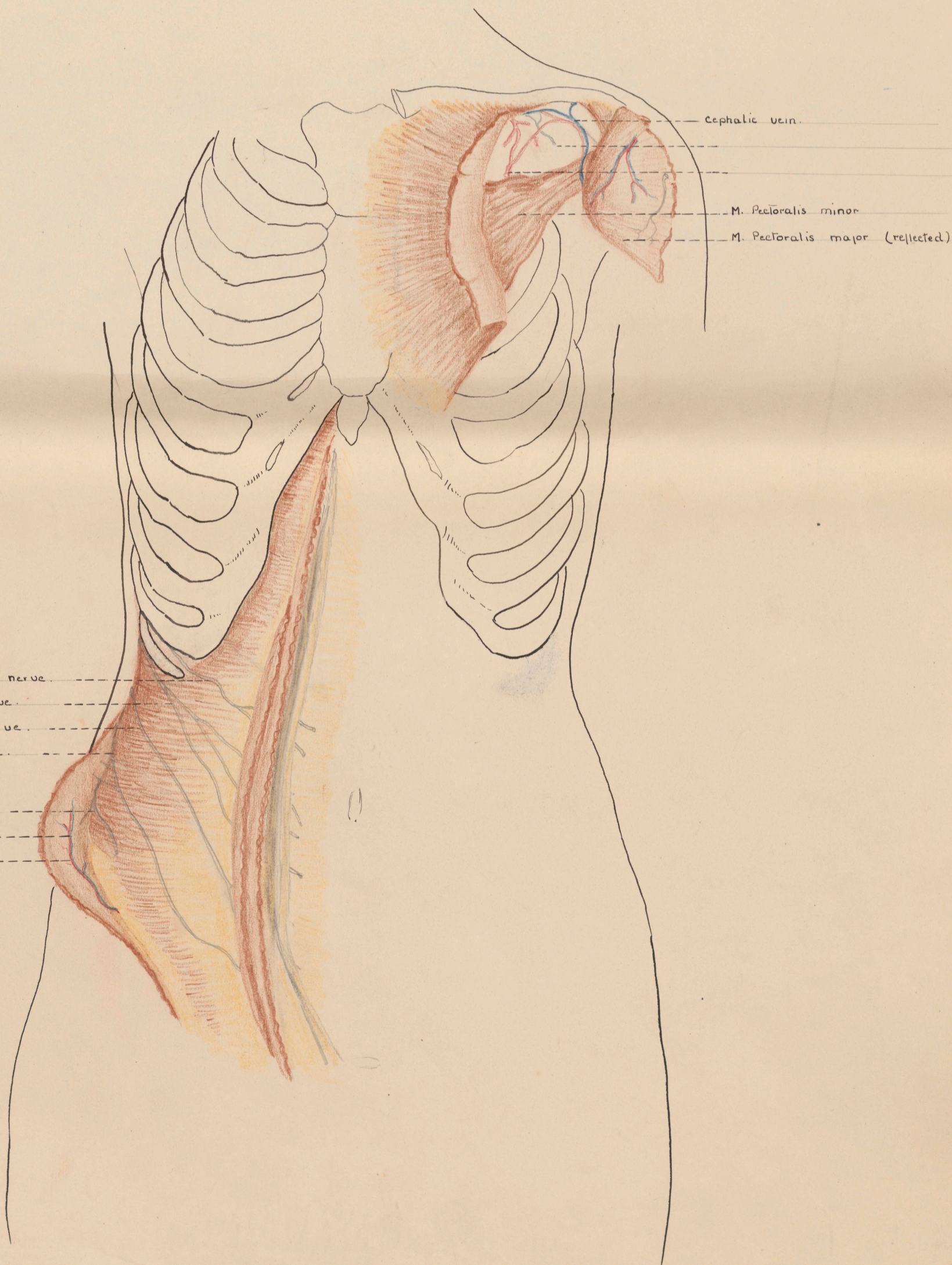
External oblique.





Cephalic vein
anterior thoracic nerve
Thoracic nerve
pectoralis minor

ninth intercostal nerve
Tenth intercostal nerve
eleventh intercostal nerve
twelfth intercostal nerve
first lumbar nerve
circumflex iliacus profundus
M. Internal oblique



cephalic vein

M. Pectoralis minor

M. Pectoralis major (reflected)

ninth intercostal nerve

tenth intercostal nerve

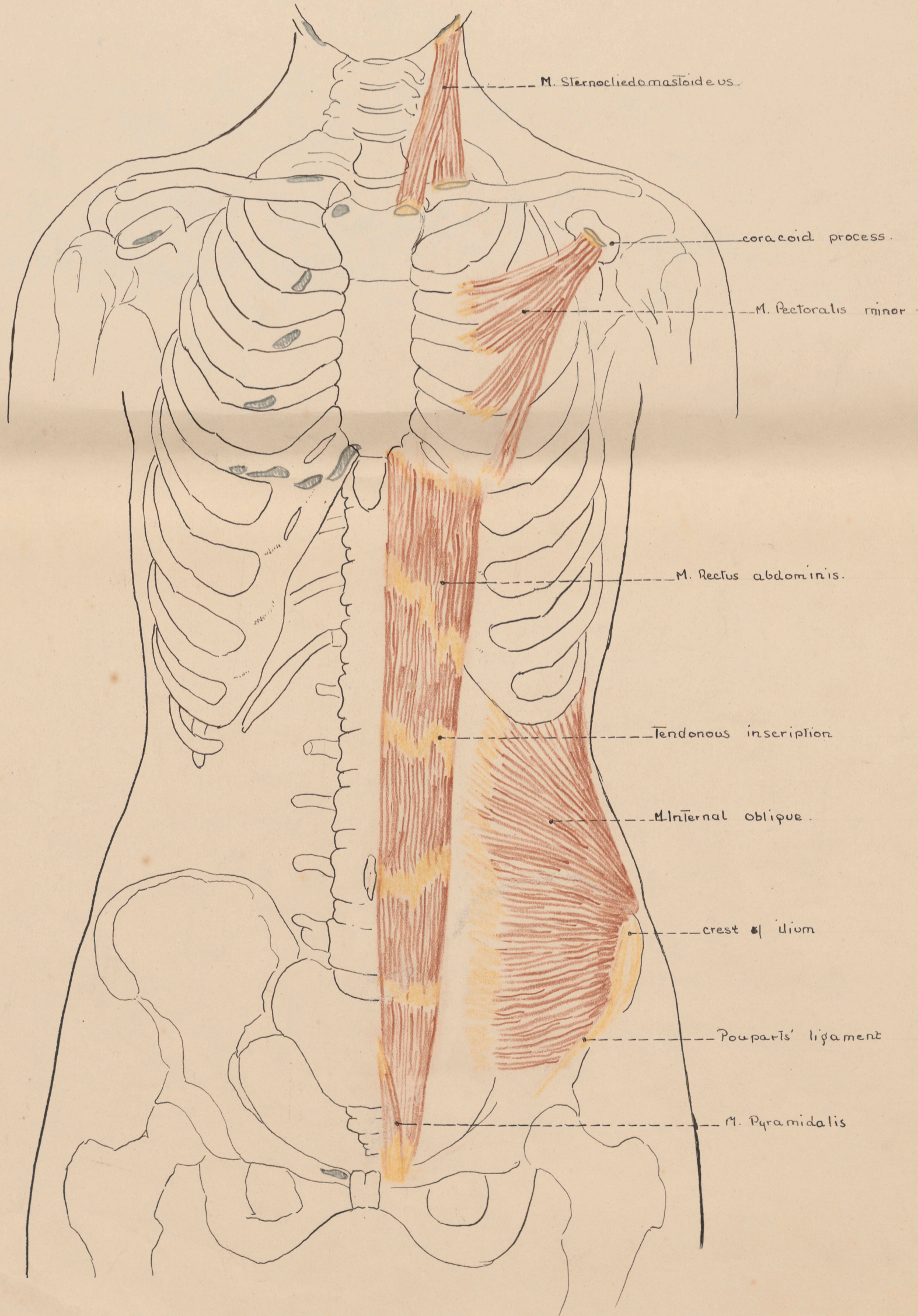
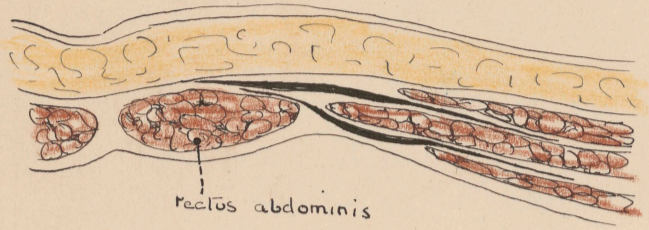
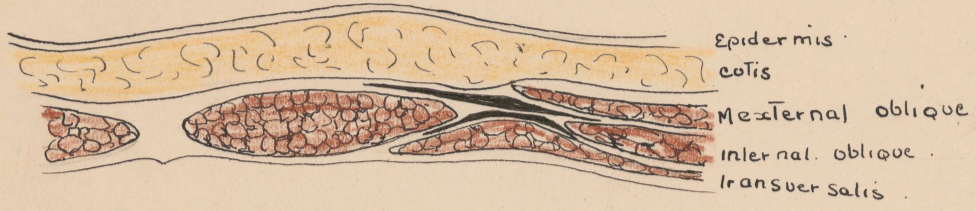
eleventh intercostal nerve

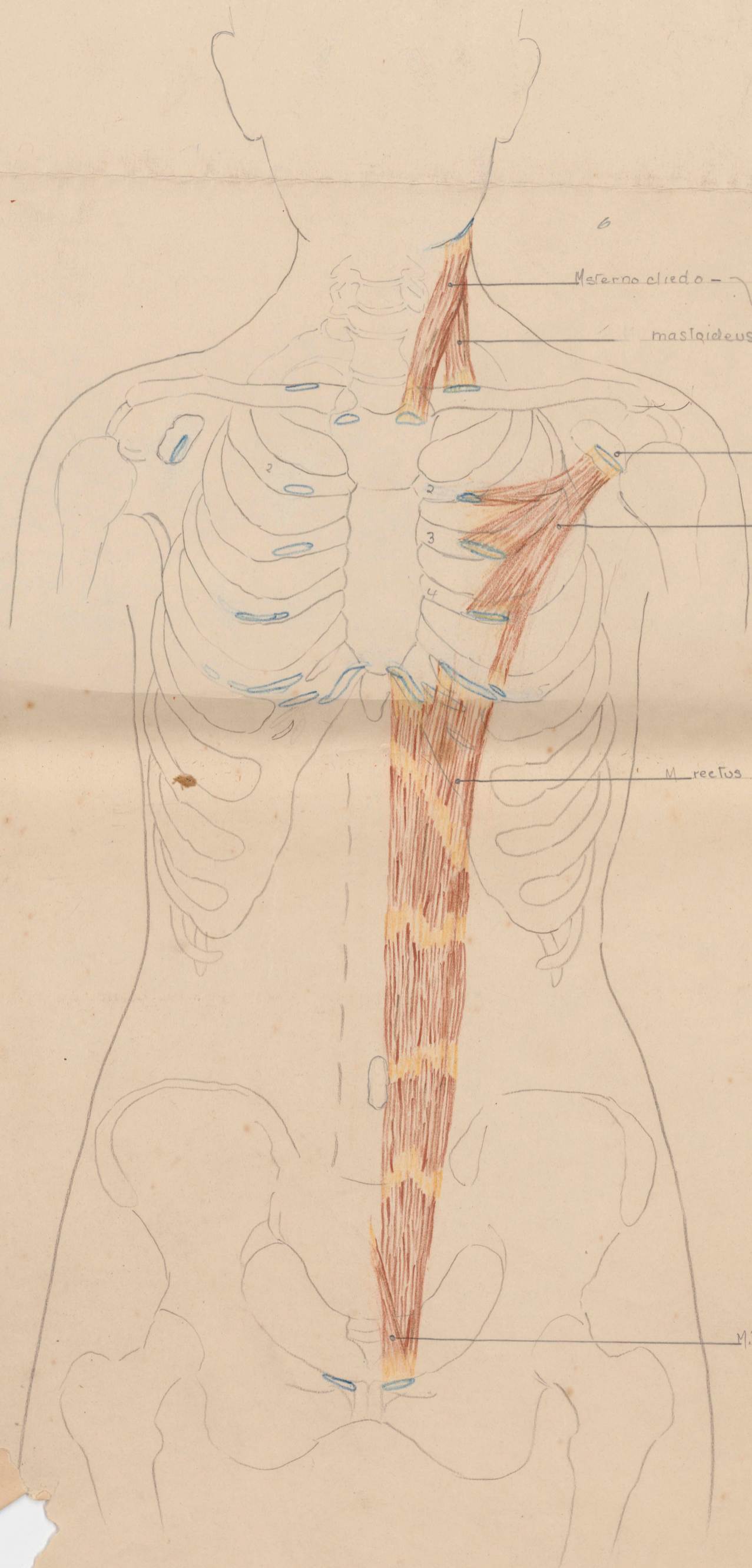
twelfth intercostal nerve

first lumbar nerve

circumflex iliacus profundus

M. Internal oblique (reflected)





6

Sternocleido -

masloideus

coracoid process

M. Pectoralis minor

M. rectus abdominis

M. Pyramidalis

1

2

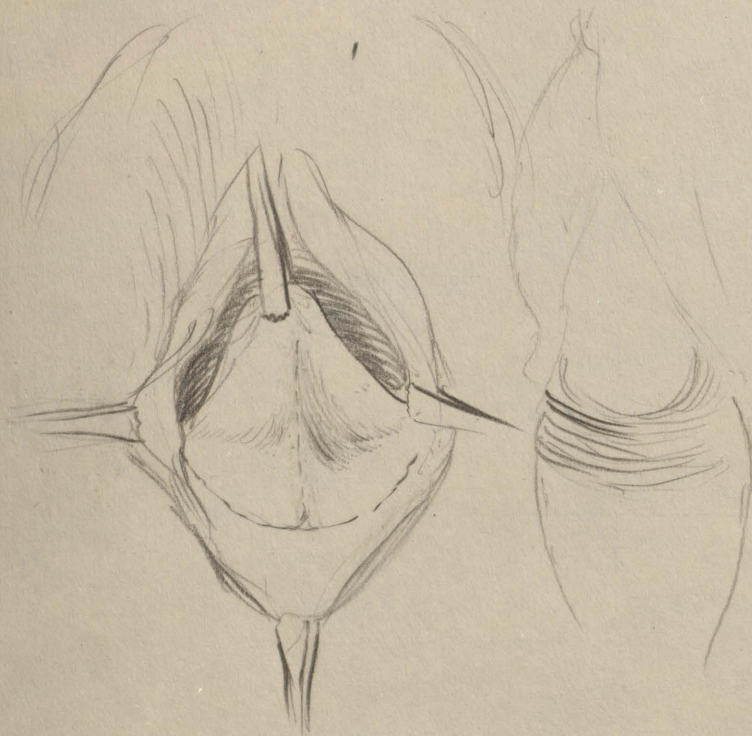
3

4

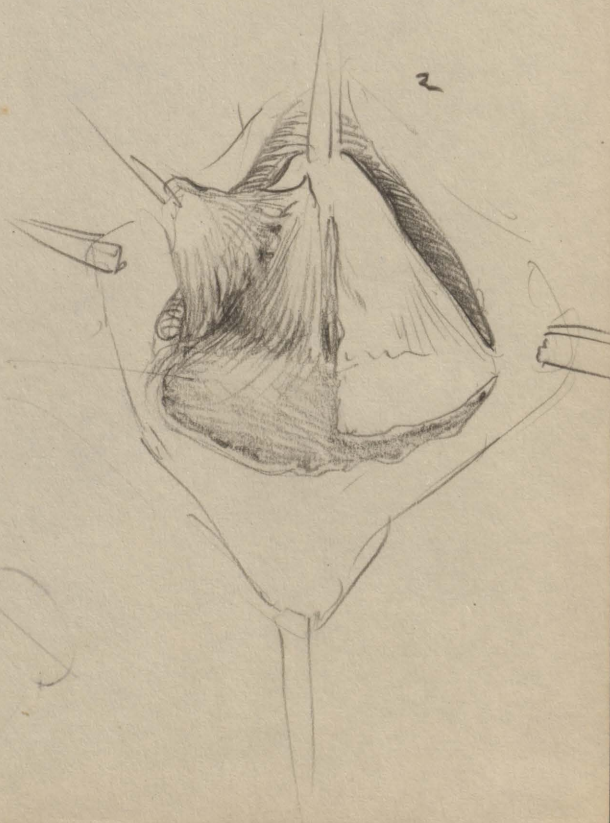
repair of relaxed vaginal outlet.

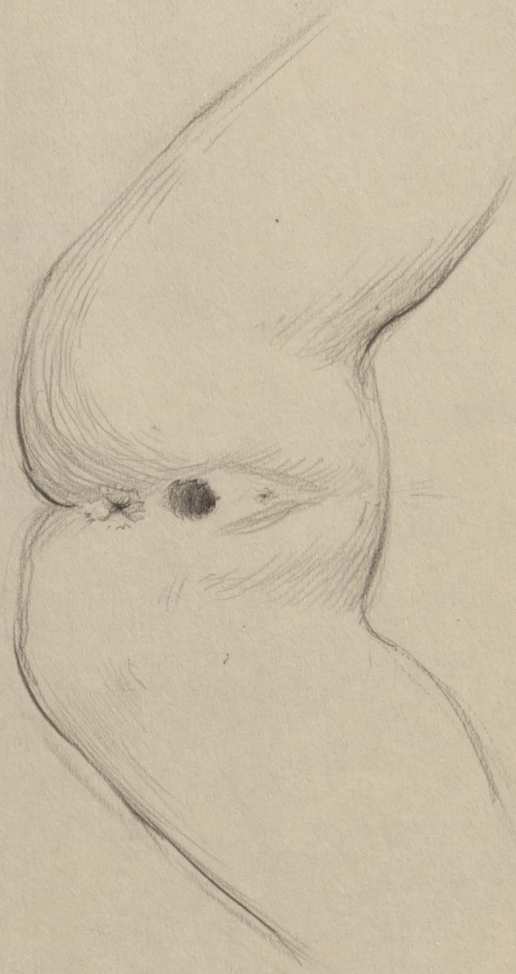
Oct. 95.

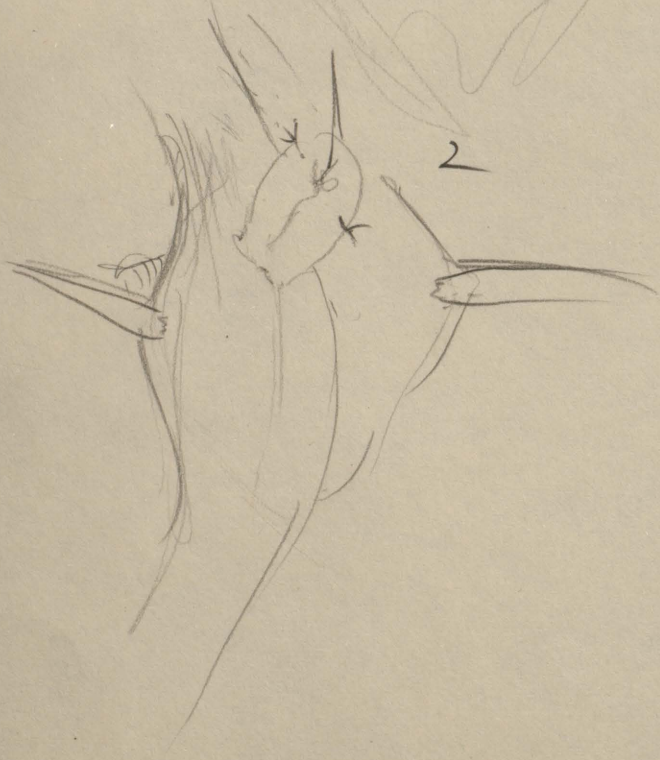
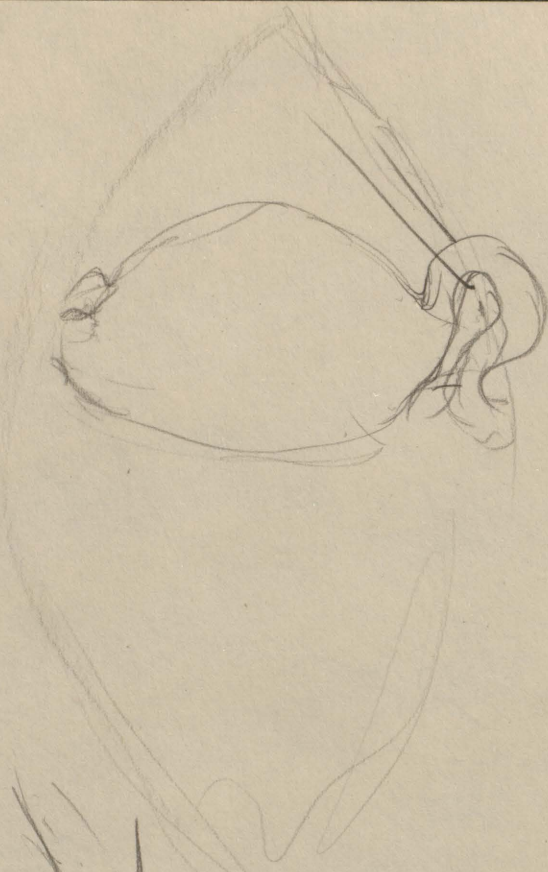
Dr. Richardson.



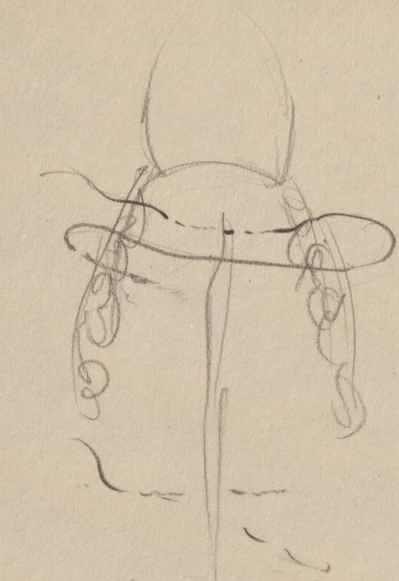


law area

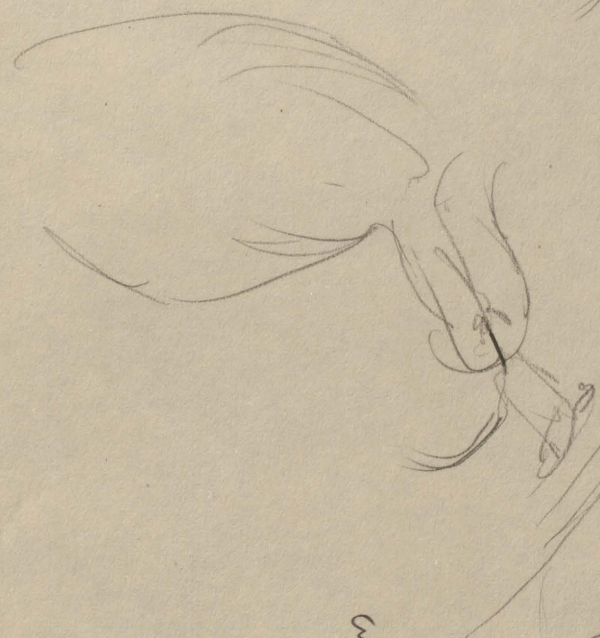
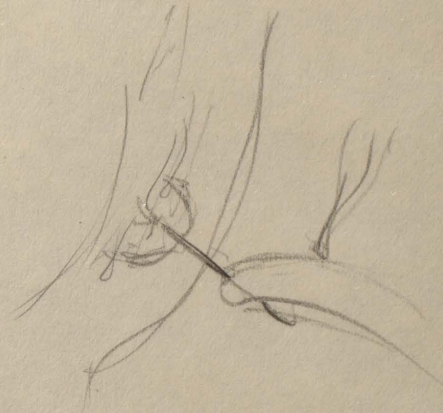







F



3




Oct. 12th - 33.

Dr. Lewis -

Carcinoma of stomach.

inoperable - primary in
liver. nodules in head & tail
of pancreas.

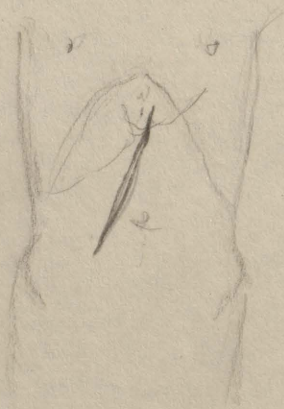

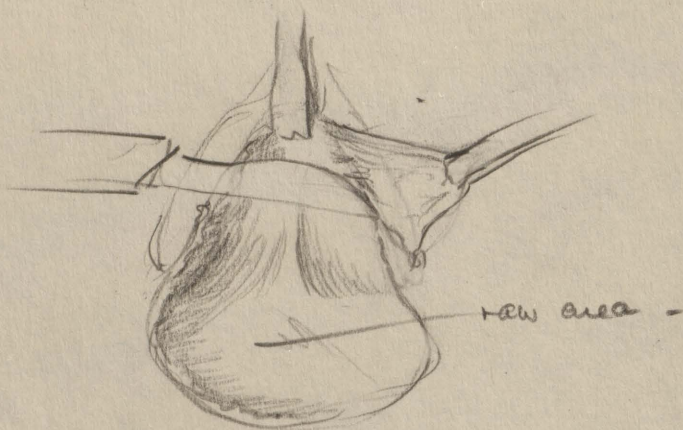
Oct. 12th - 33.

Dr. Lewis.

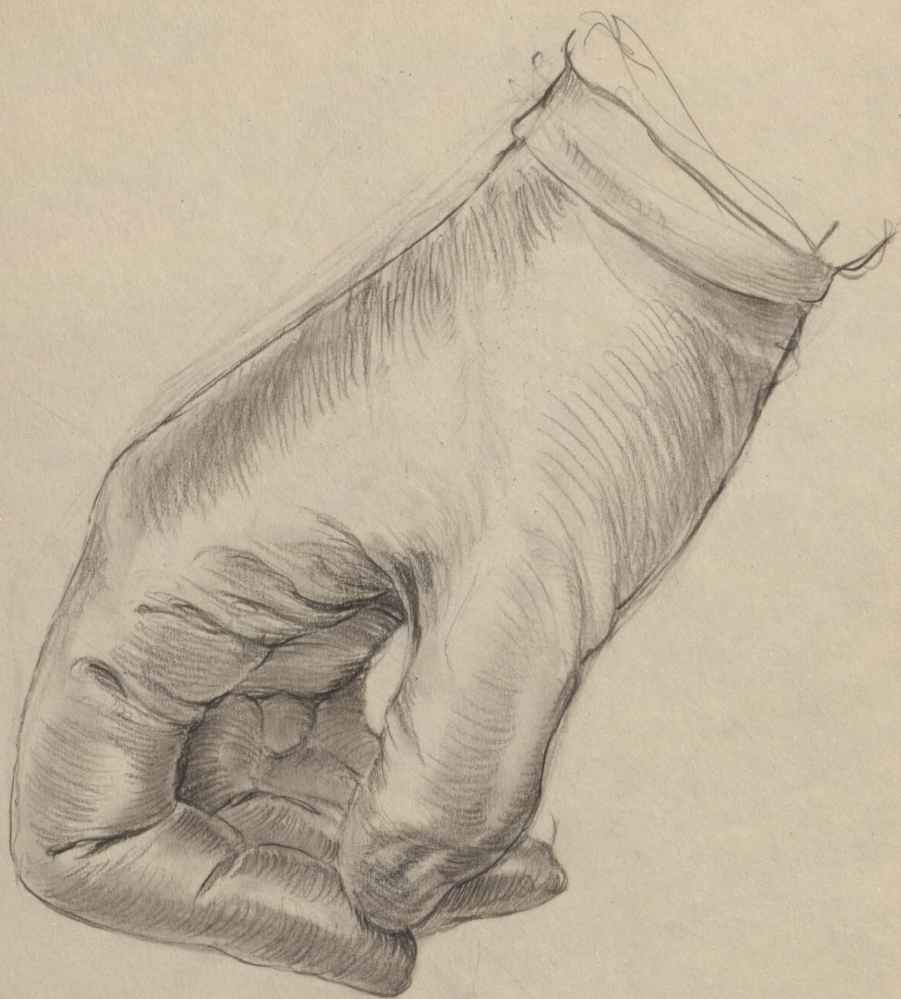Dr. Campbell.

Carcinoma of stomach.





two rows of catgut sutures one on top of
the other.

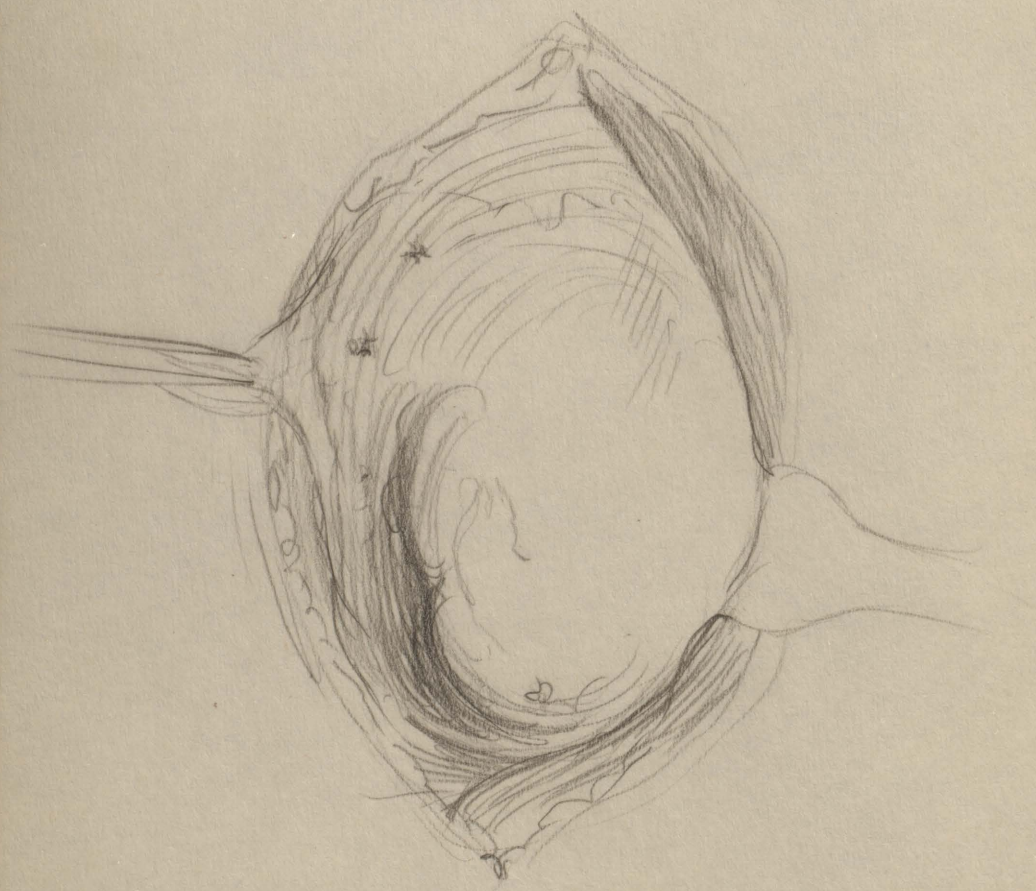


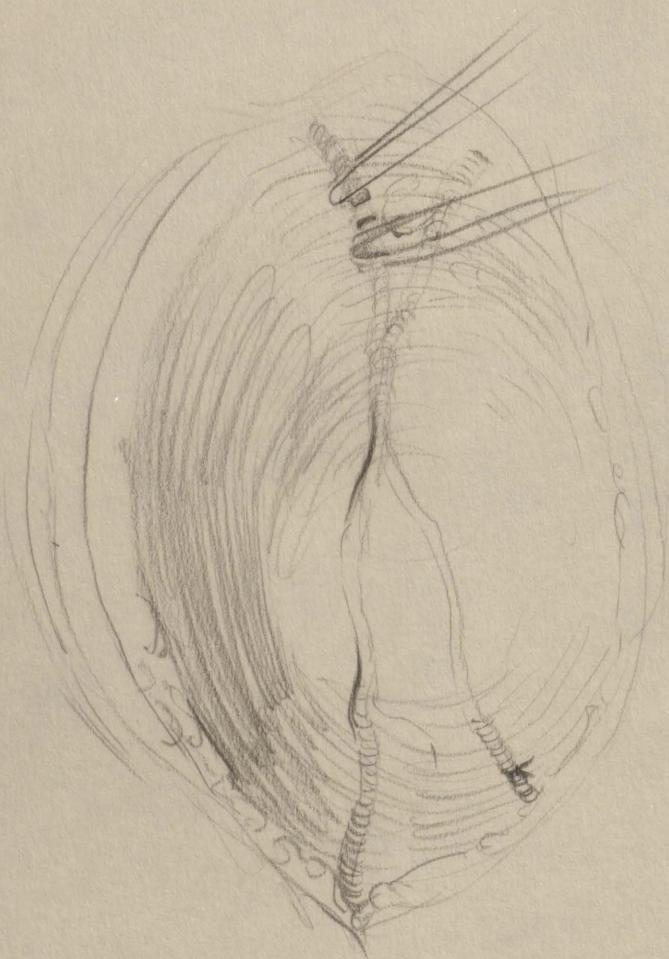left leg.

tumor in
popliteal space

Knee cap.

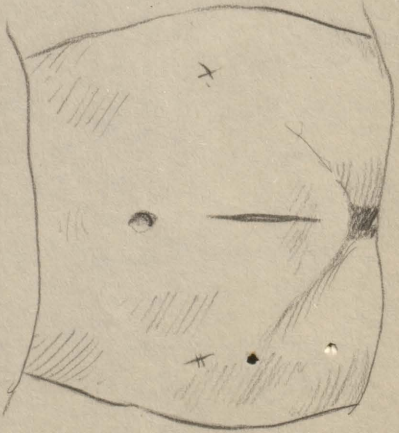
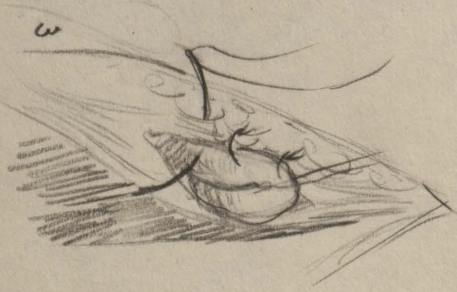

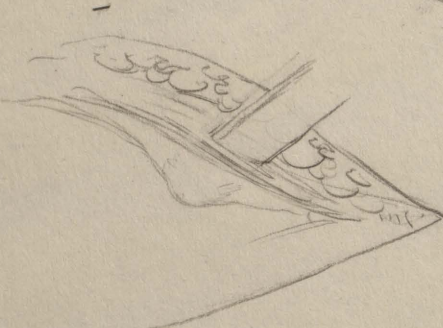
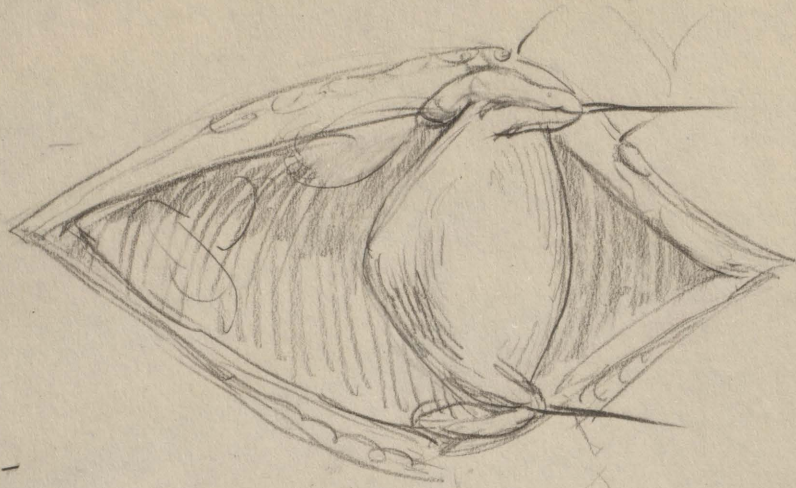
Dr. Tremples 23rd.
March 23rd.



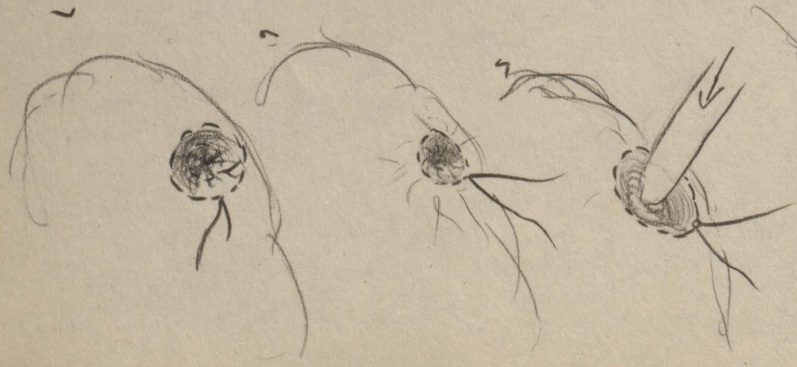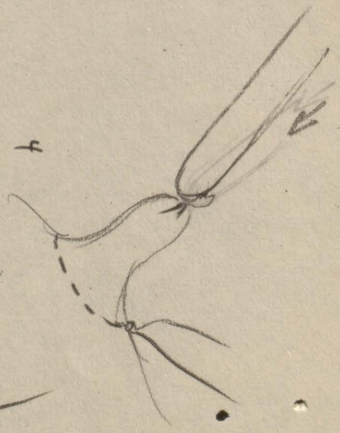
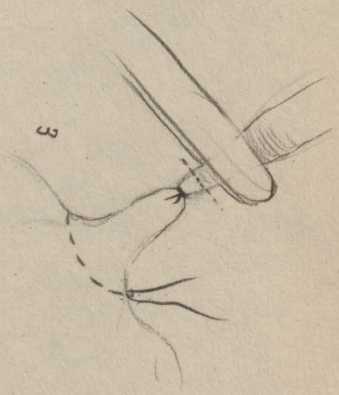
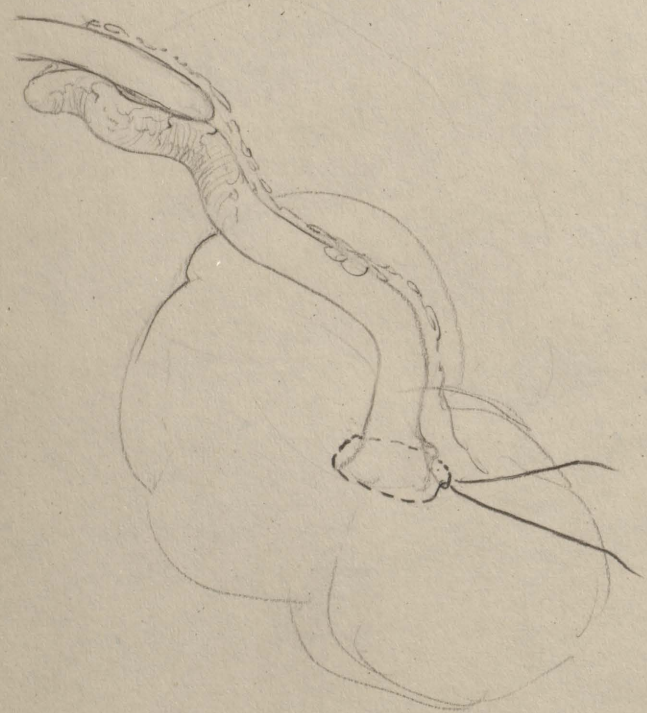
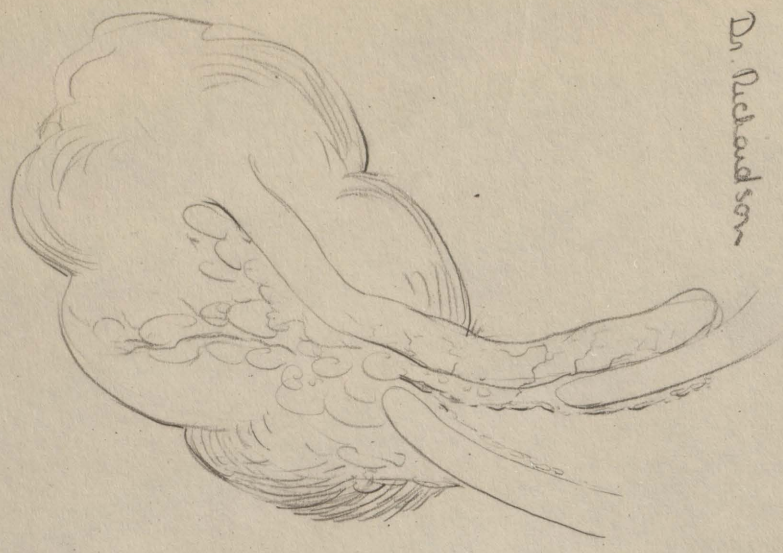


Relative position of Uterus
and appendages.

Dr. Neiland son.
— April 24.



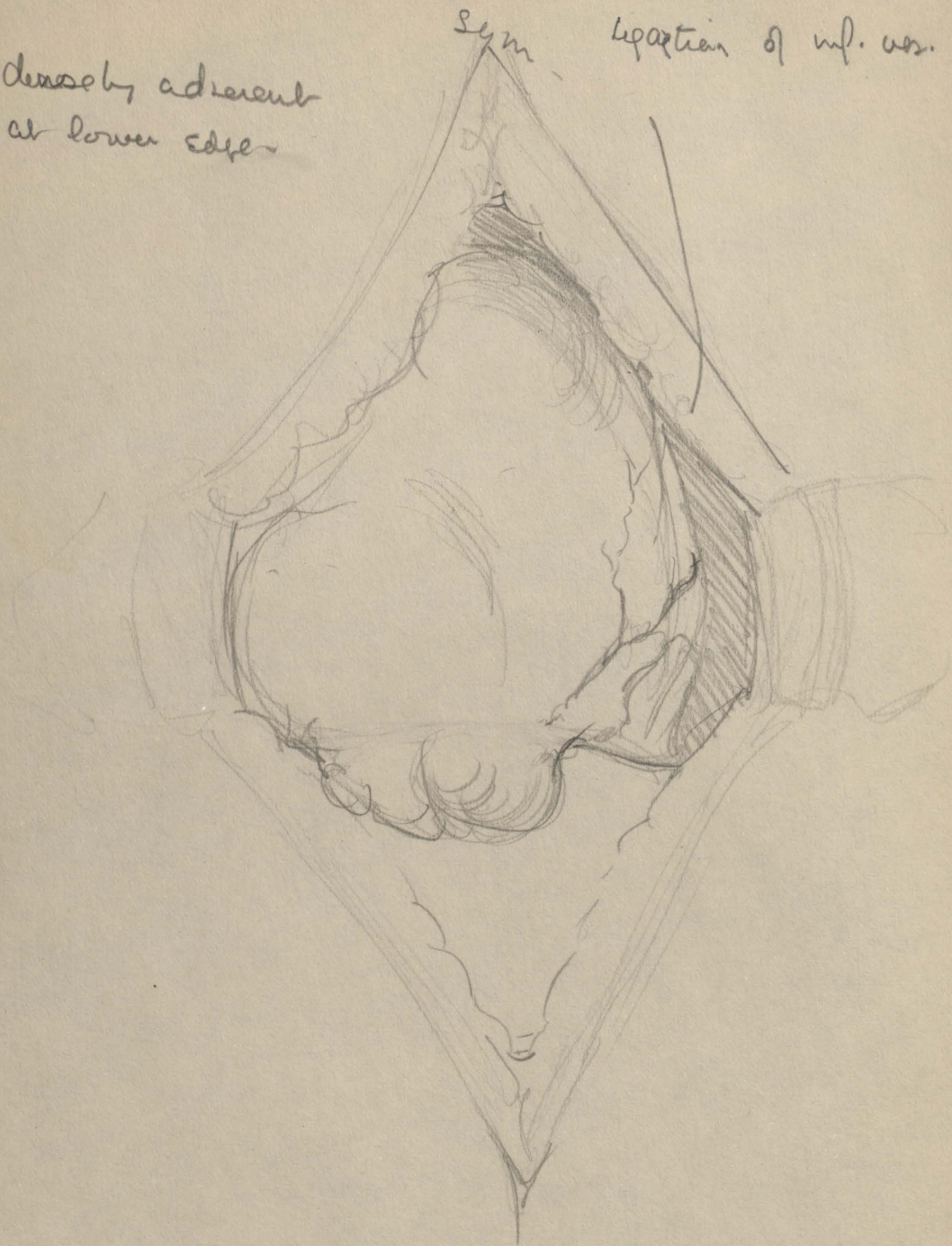
verruval appendice
removed during operation for
Retro position of uterus.
Dr. Richardson



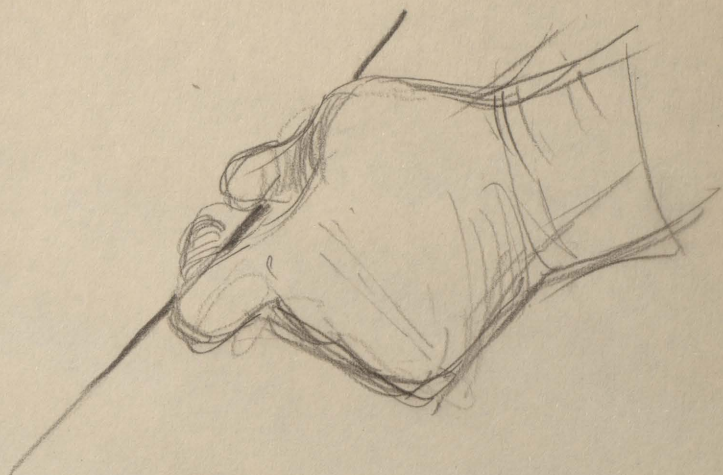
densely adherent
at lower edge

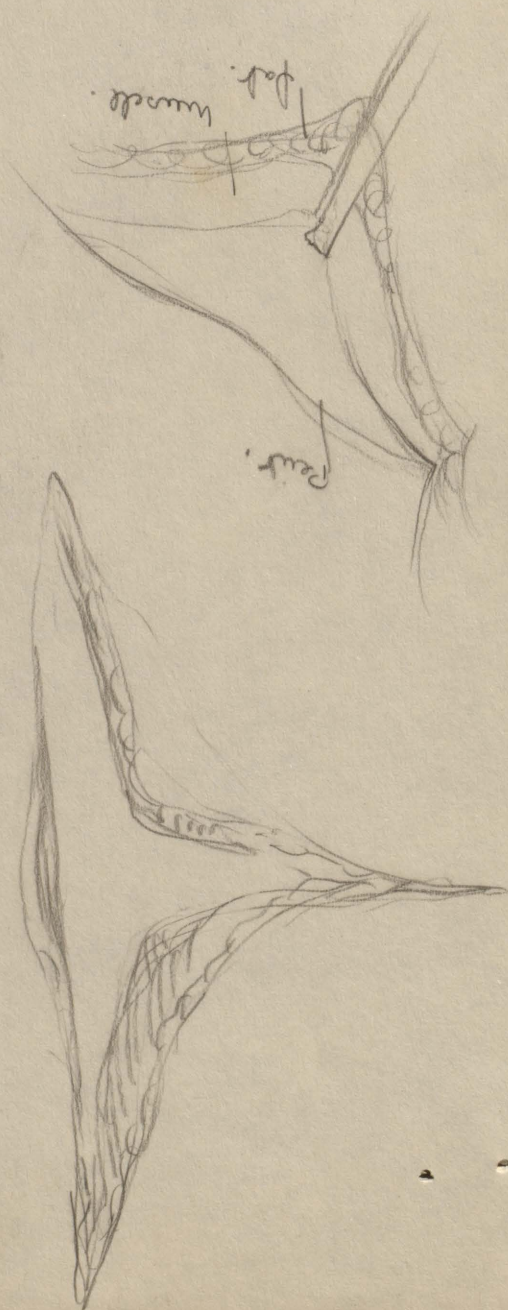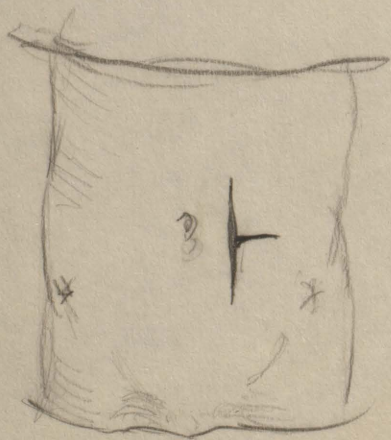Sym

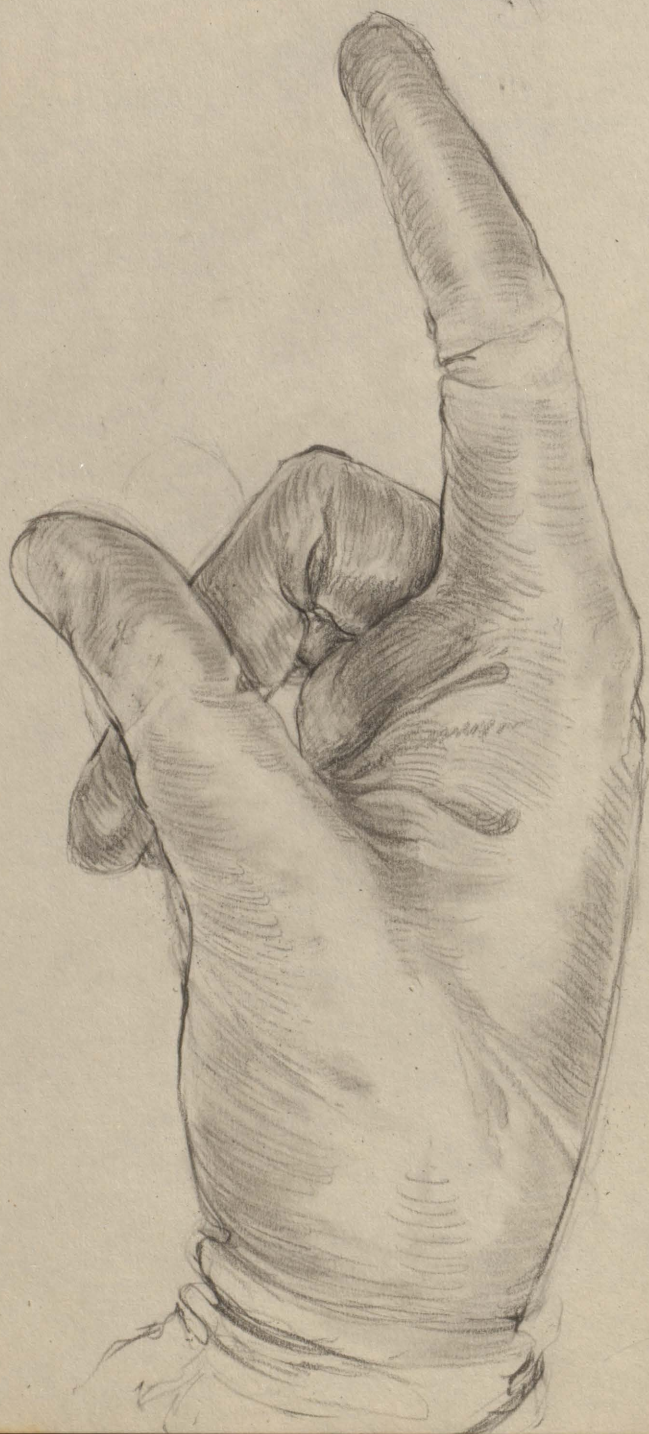location of inf. ves.

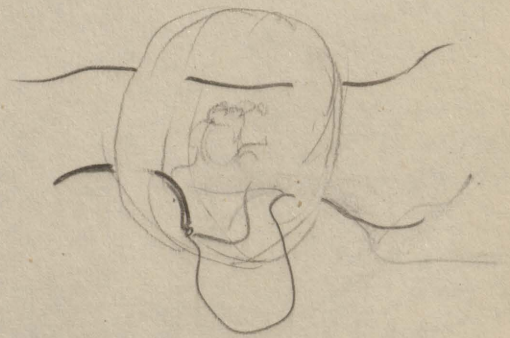
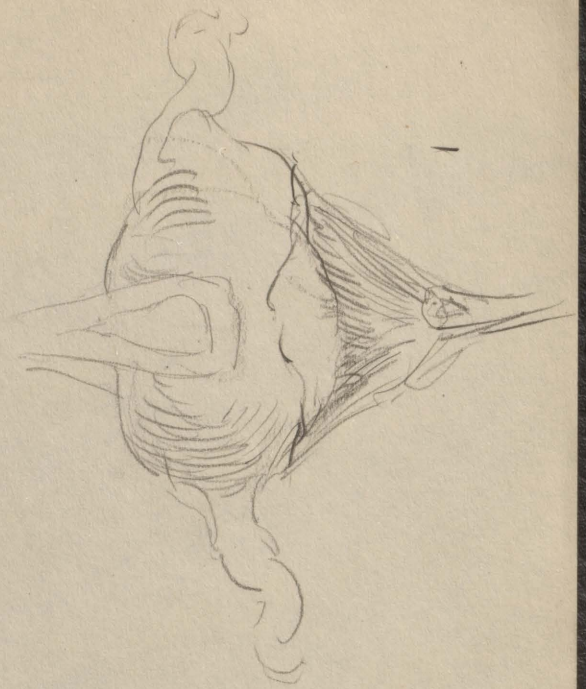




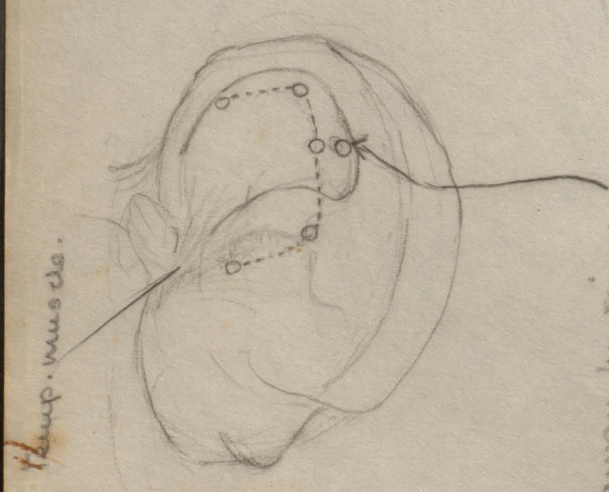
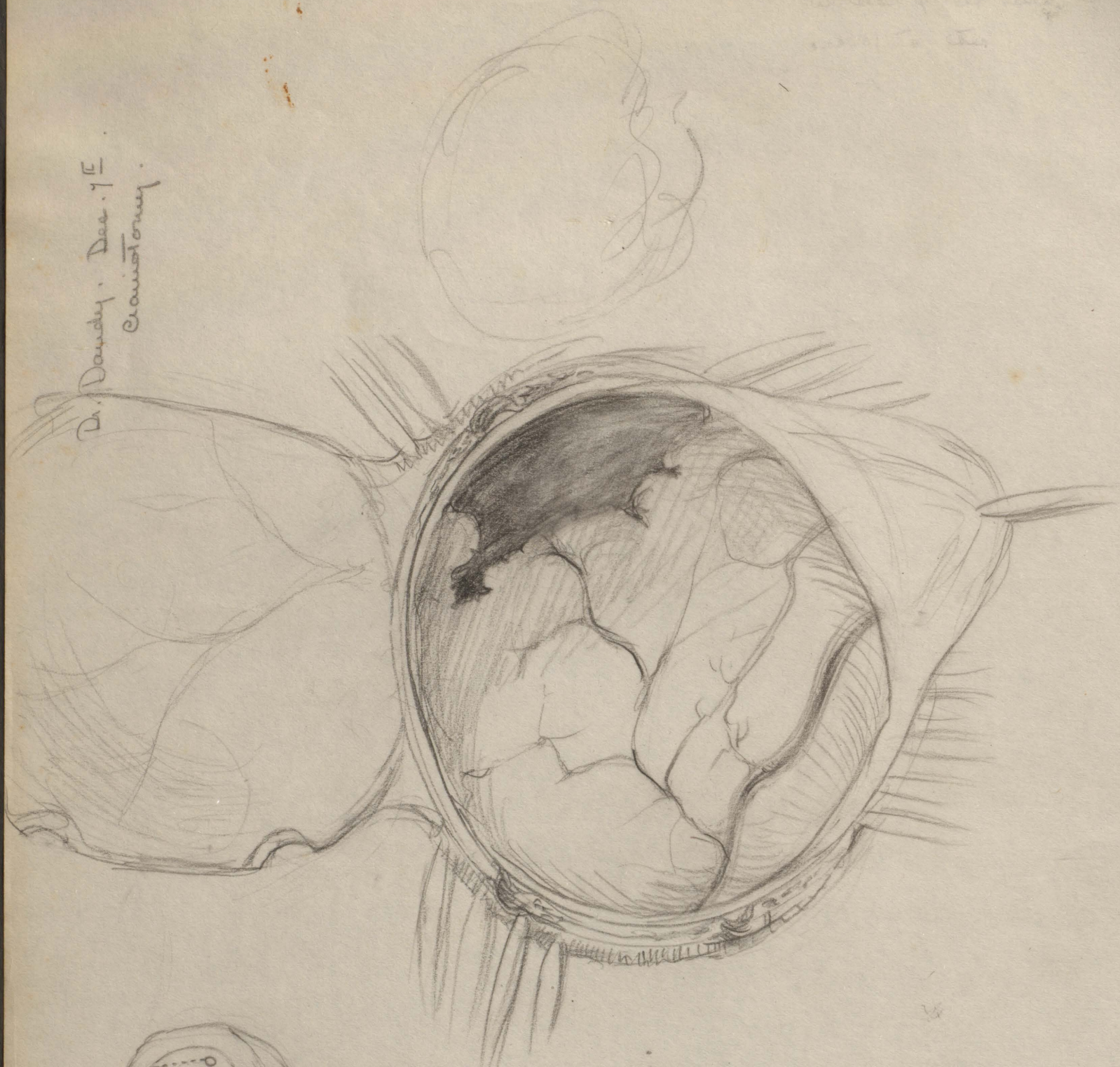








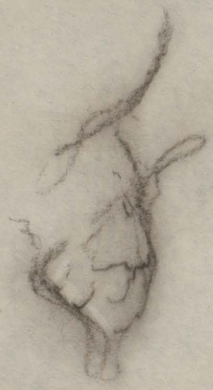
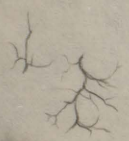
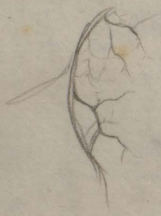
D. Dandy, Dec. 1st
Craniotomy.


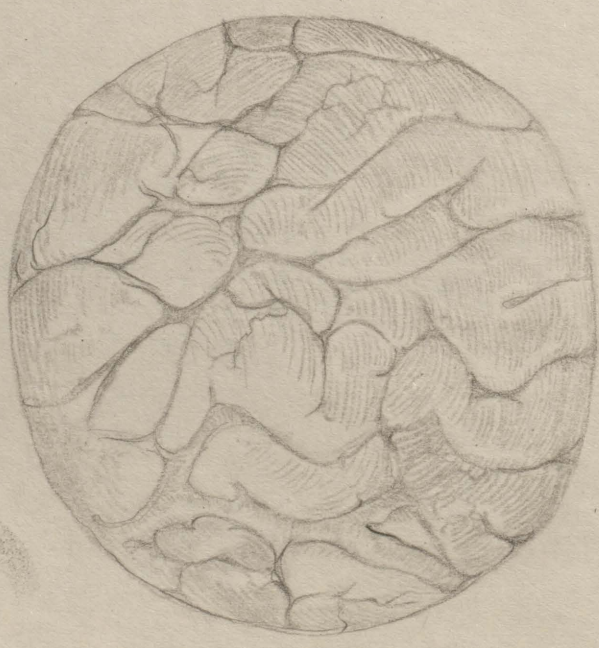
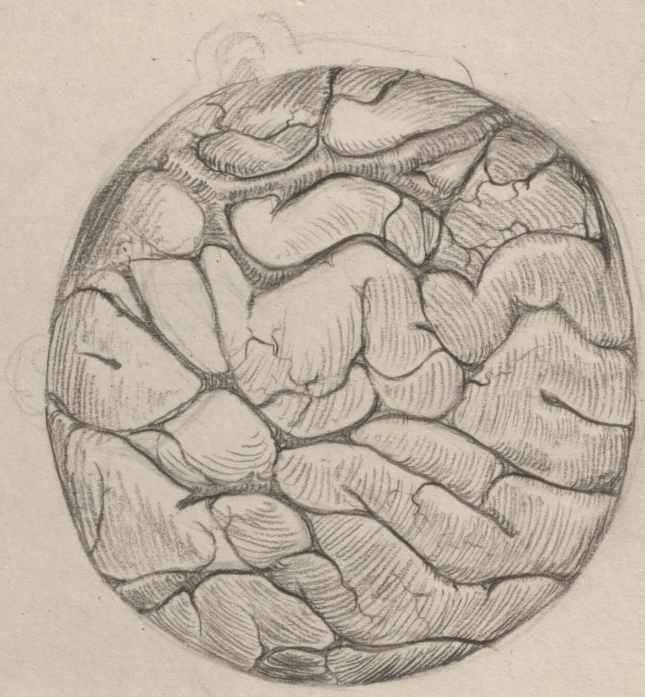


Temp. muscle.


bone taken away by sinus
struck here

preopium removed - used each
of rollands - to tension of fibre.

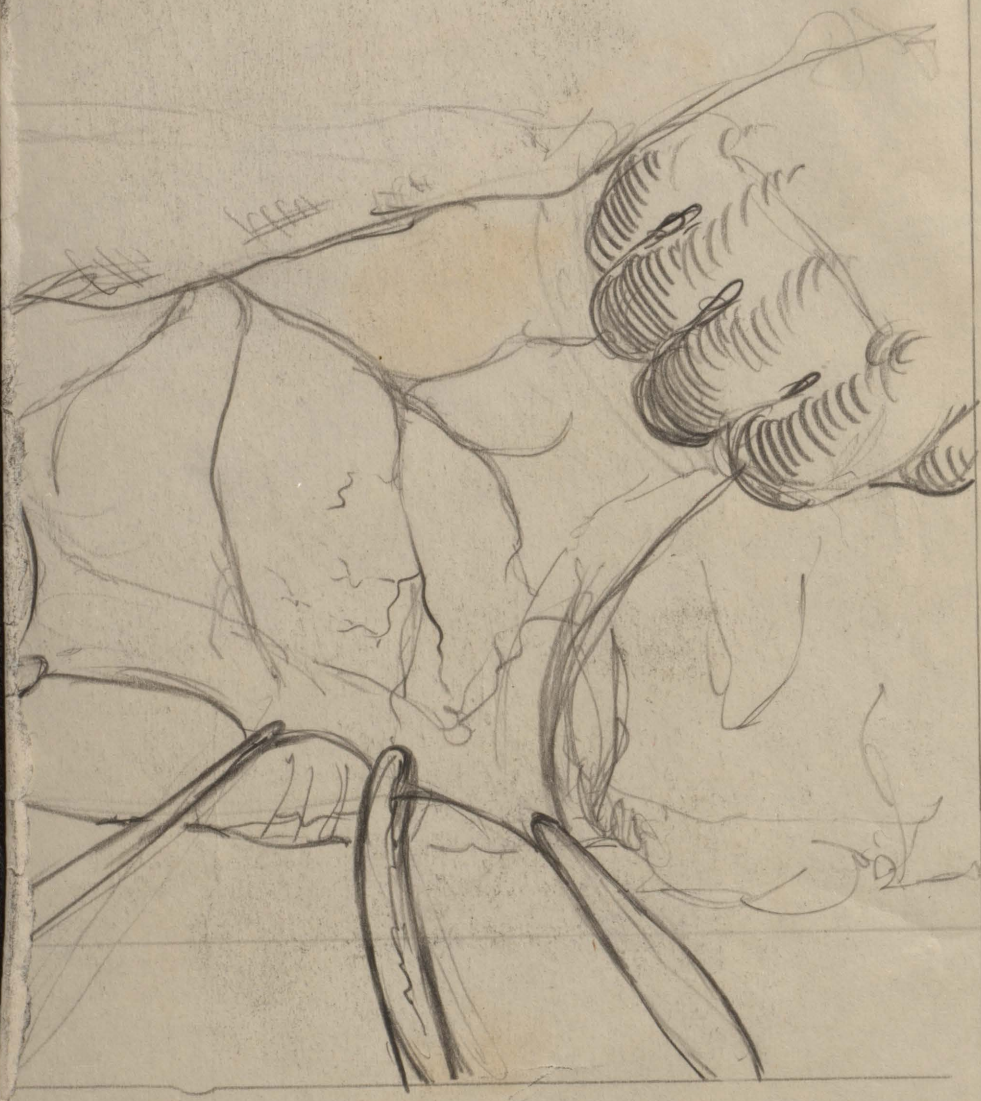




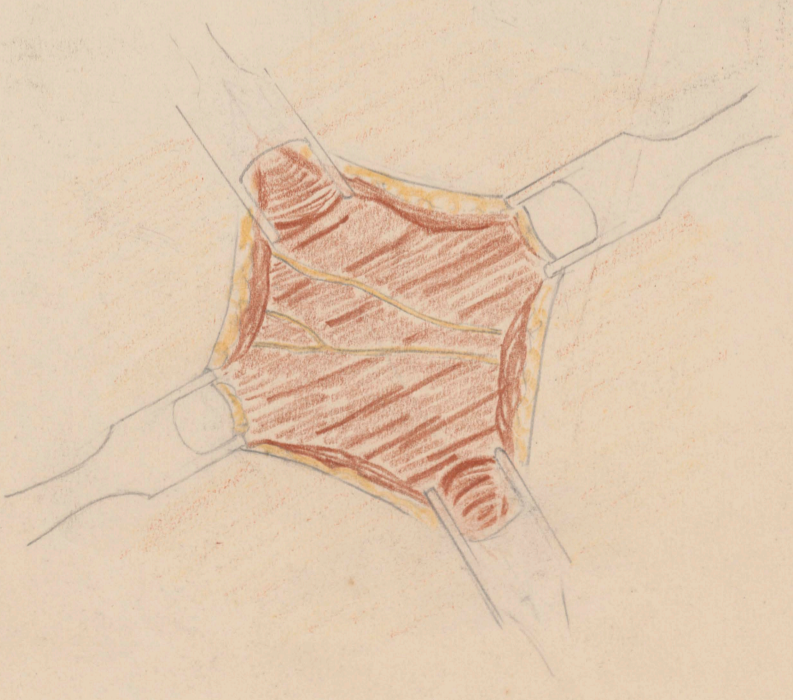
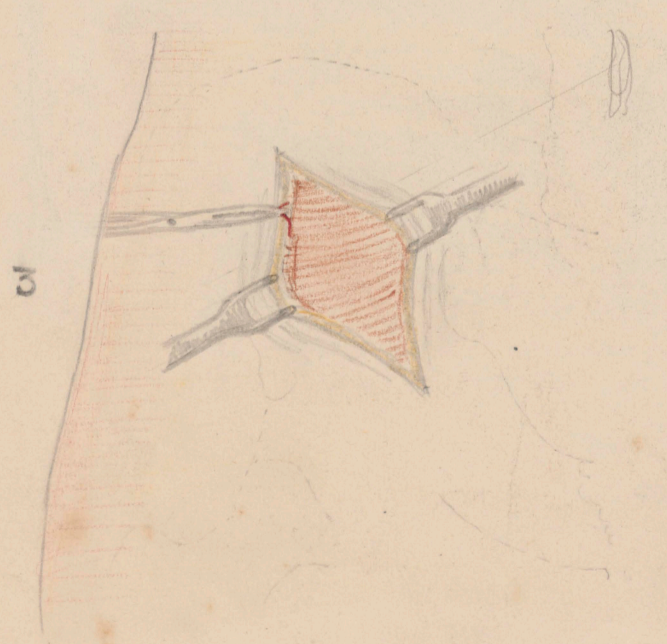
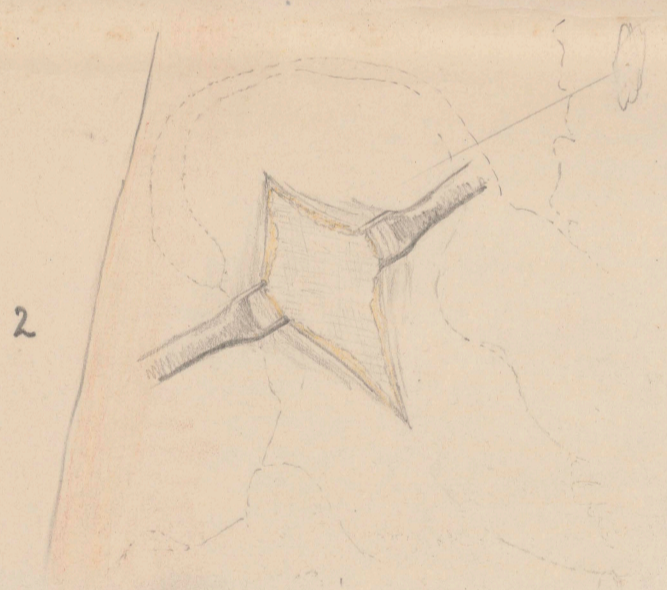
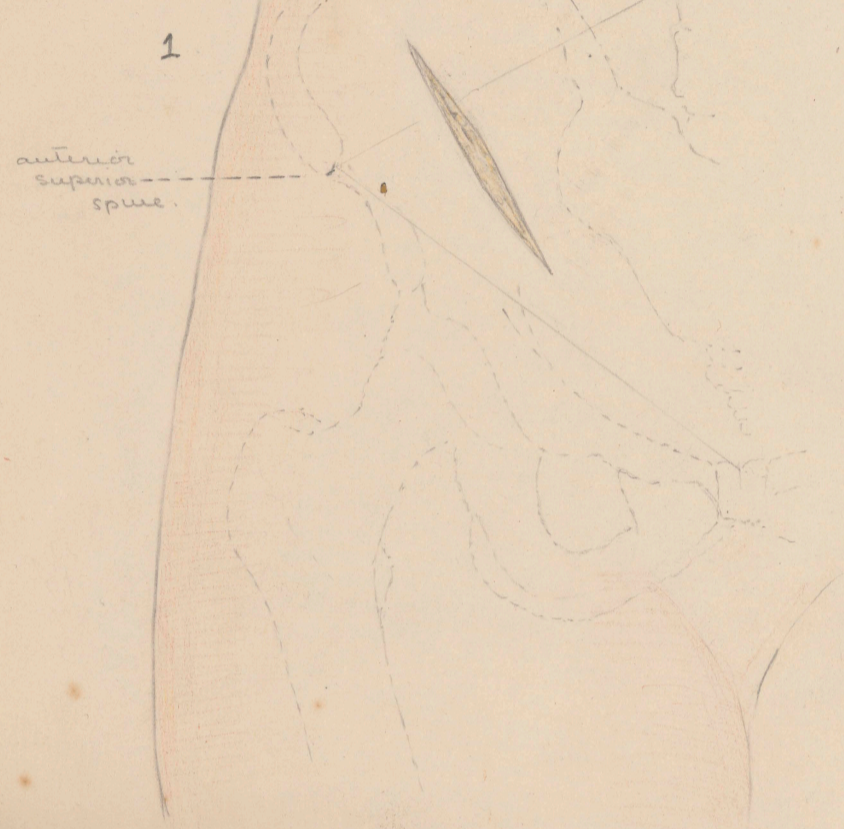Seated
burial -
H.H. Powell
L.R.
S.R.

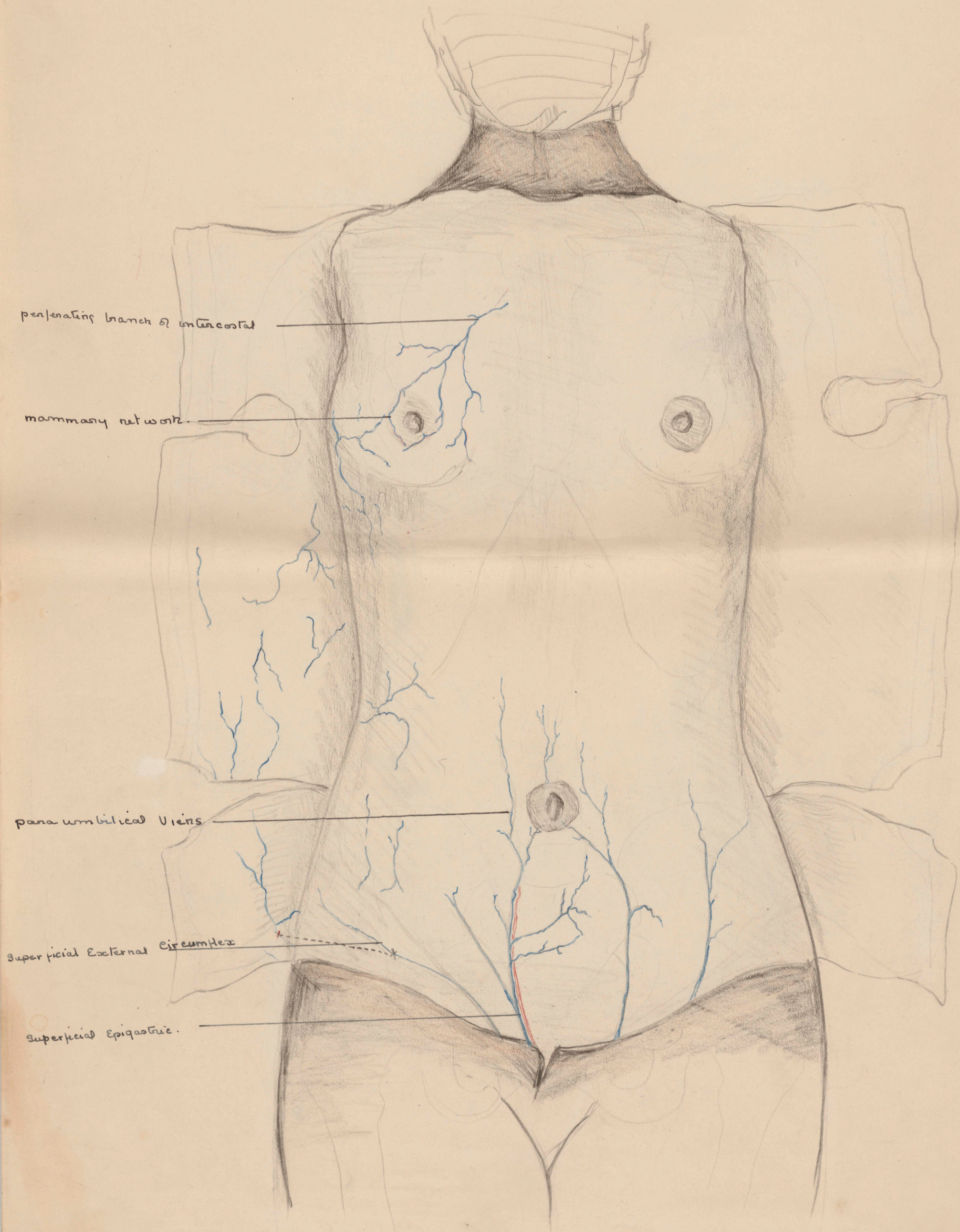






MacBurrus point is found on the line drawn from the anterior superior spine of the ilium to the umbilicus, an inch and a half from the spine. The incision runs parallel with the fibres of the external oblique, an inch above and three inches below MacBurrus point.





penetrating branch of intercostal

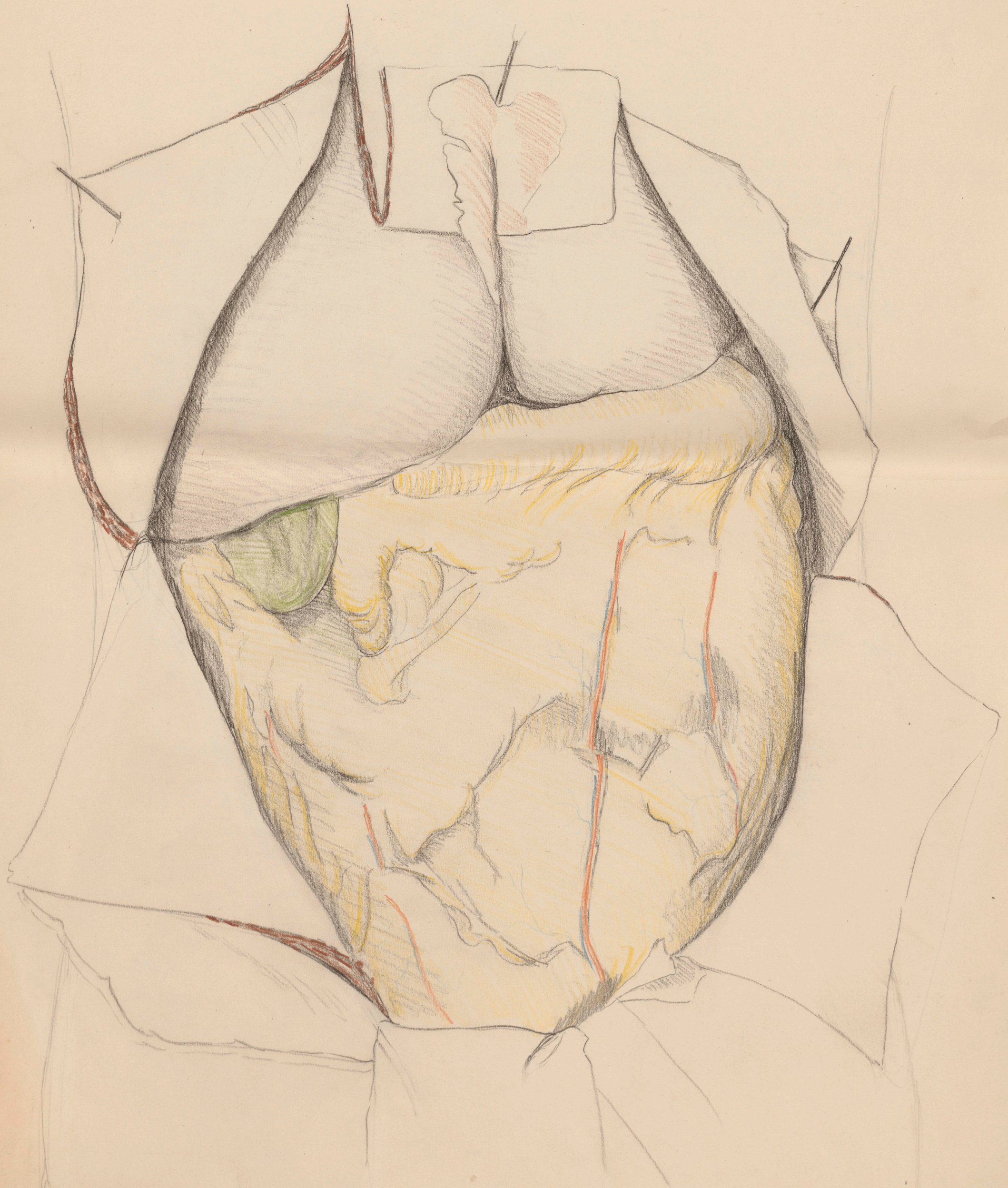
mammary network

para umbilical veins

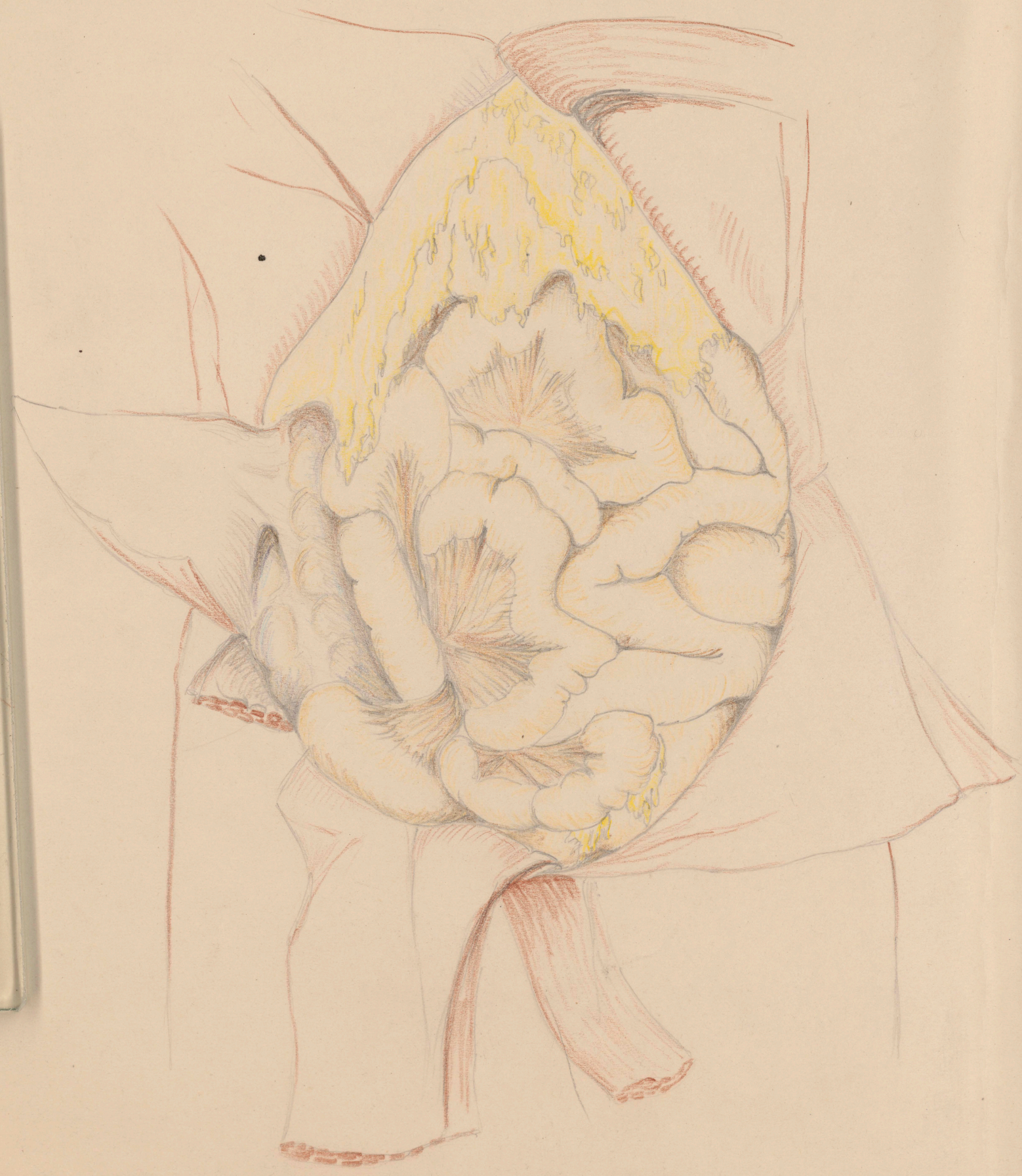
superficial External Circumflex

superficial Epigastric

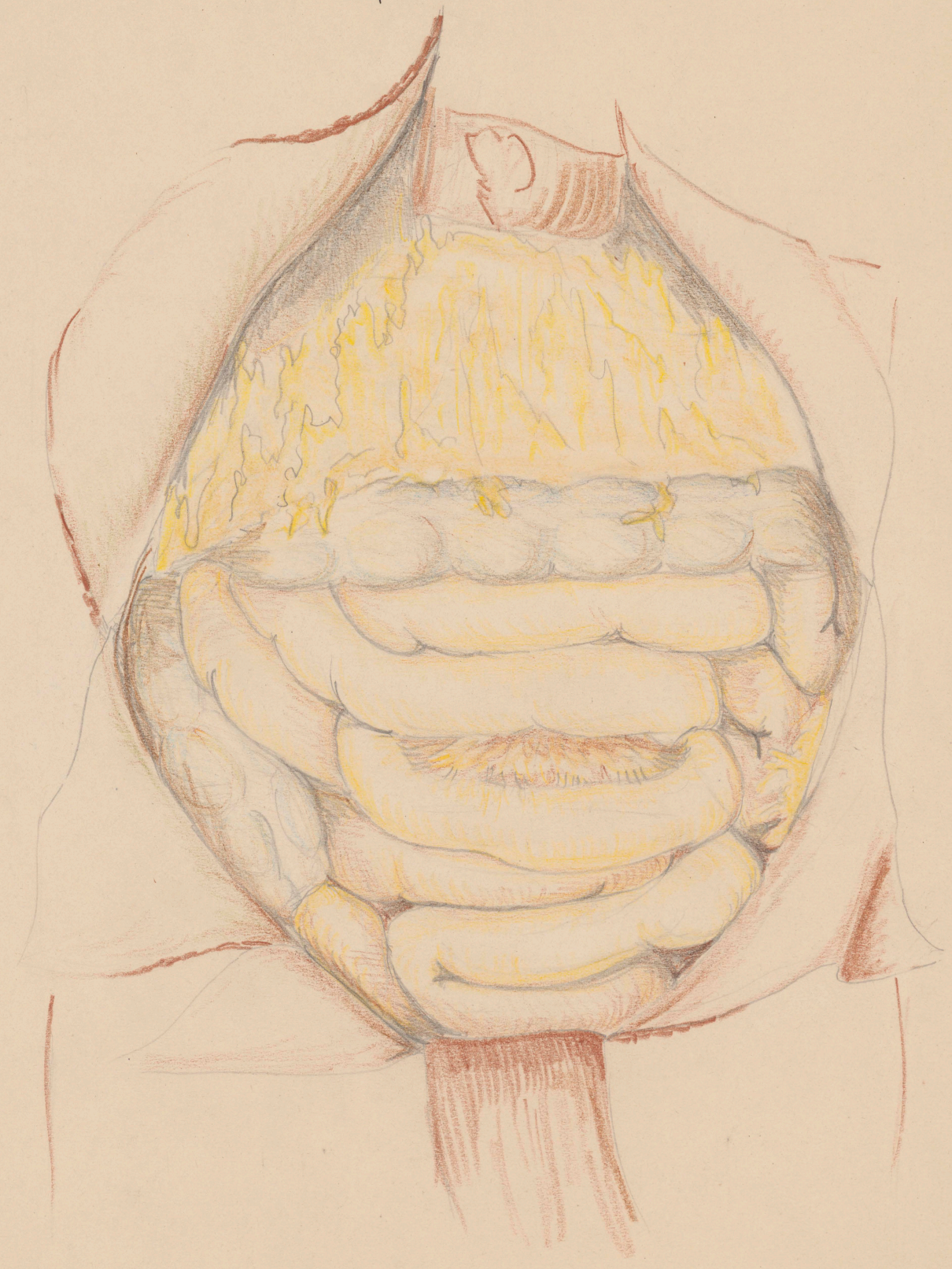S. Spodick

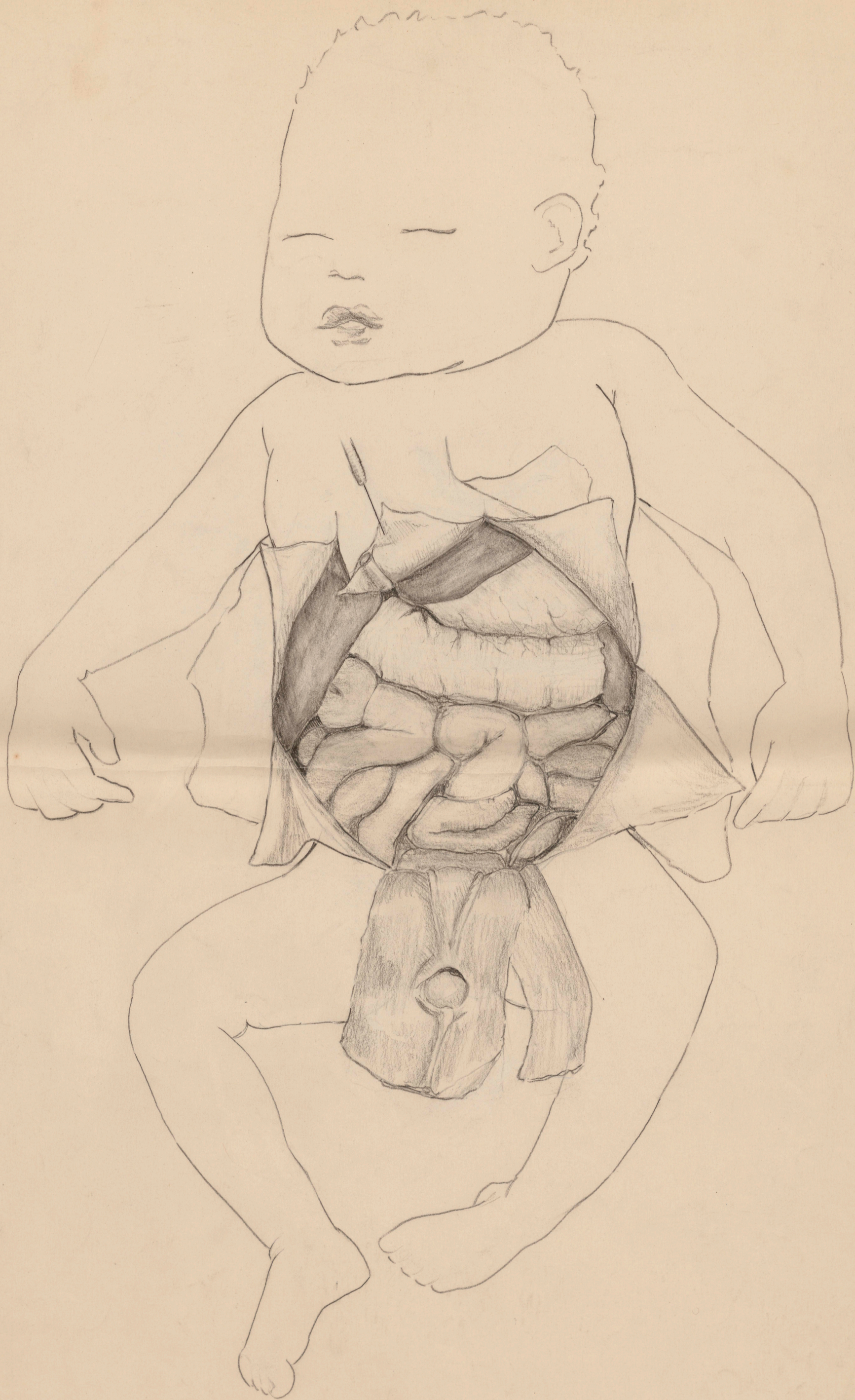


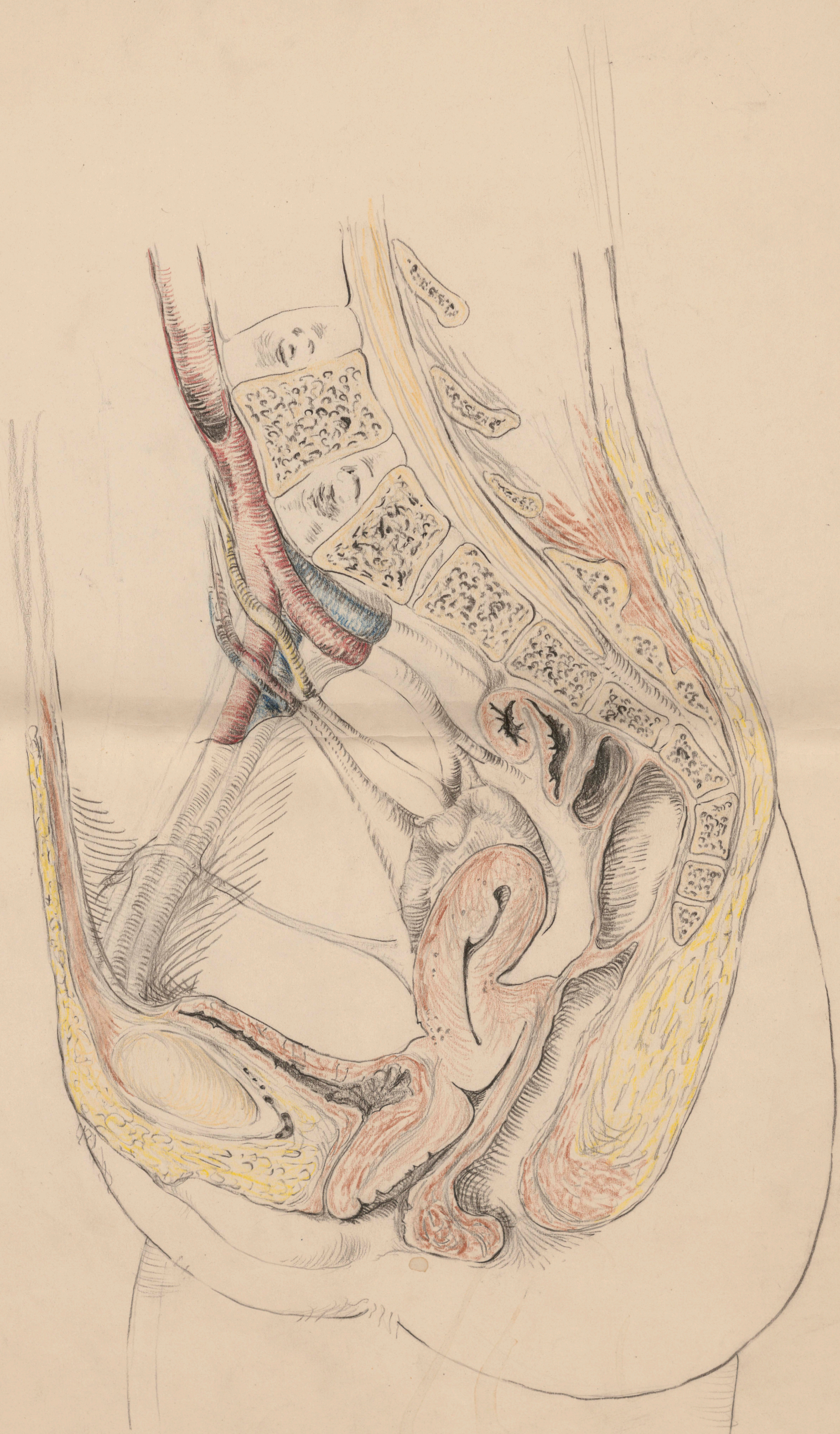
male - intestines.

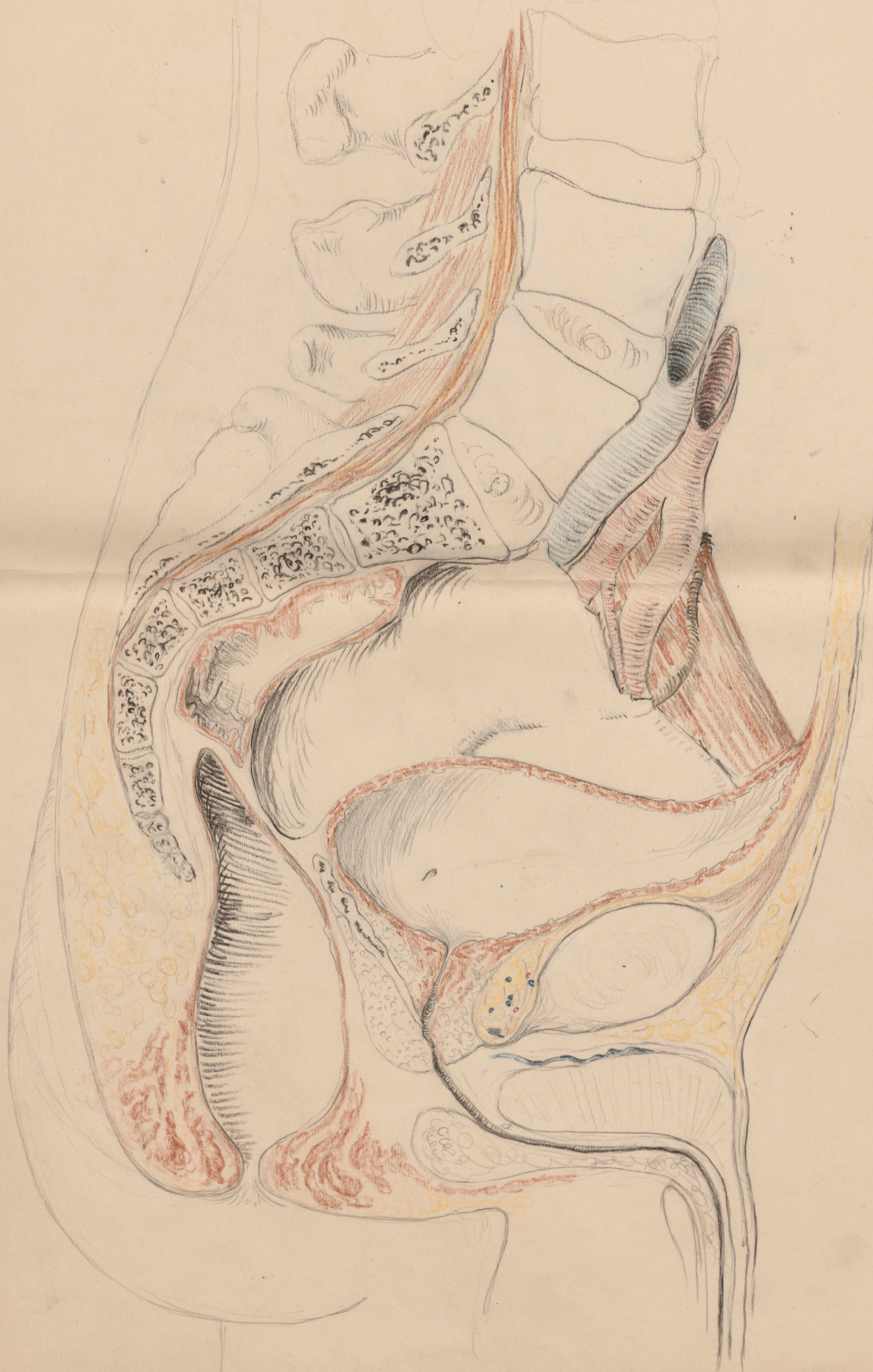

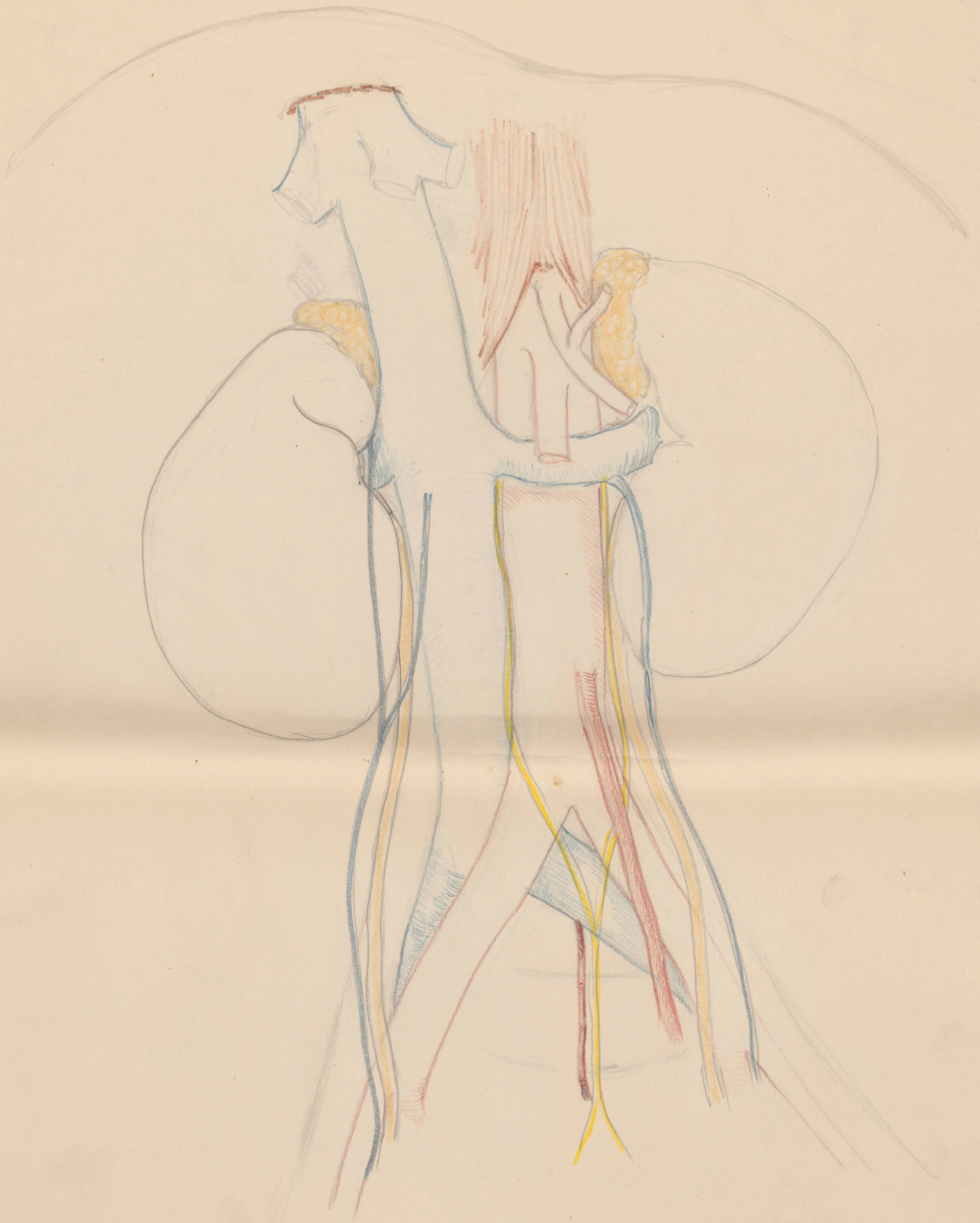female.

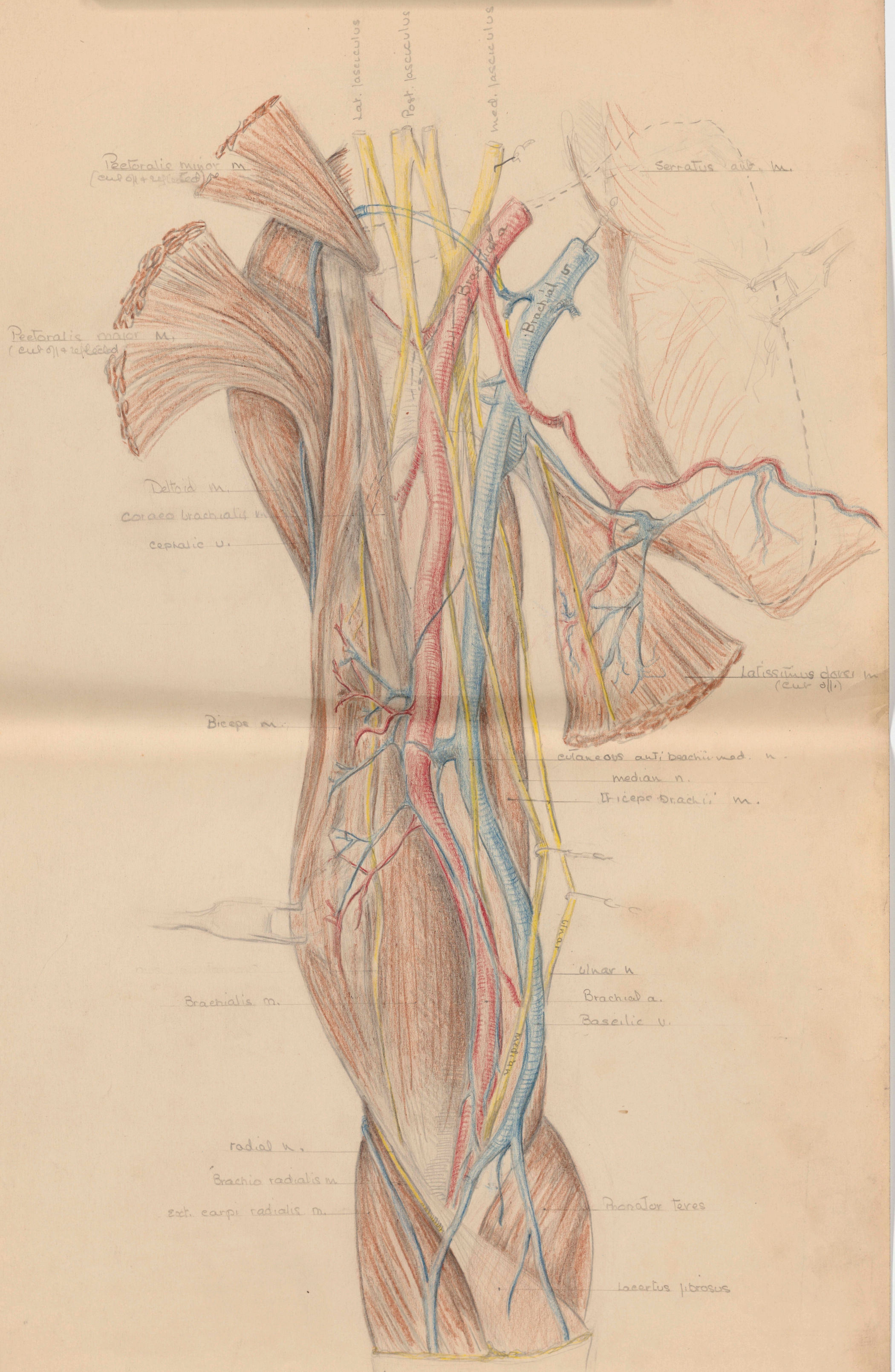












Pectoralis minor m.
(cut off + reflected)

Pectoralis major m.
(cut off + reflected)

Deltoid m.
Coraco brachialis m.
cephalic v.

Biceps m.

Brachialis m.

radial n.
Brachio radialis m.
ext. carpi radialis m.

Lat. fasciculus
Post. fasciculus
med. fasciculus

Serratus ant. m.

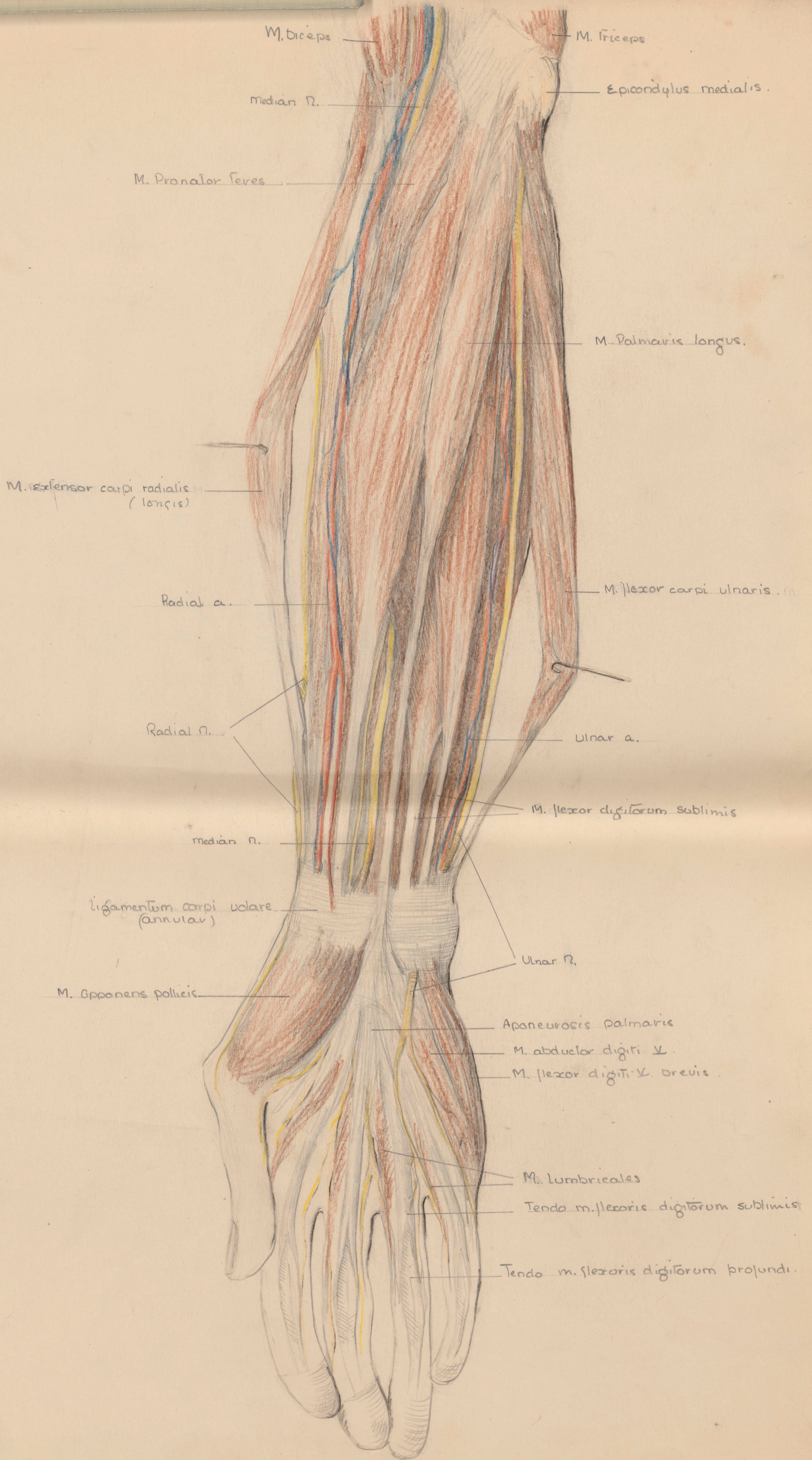
latissimus dorsi m.
(cut off)

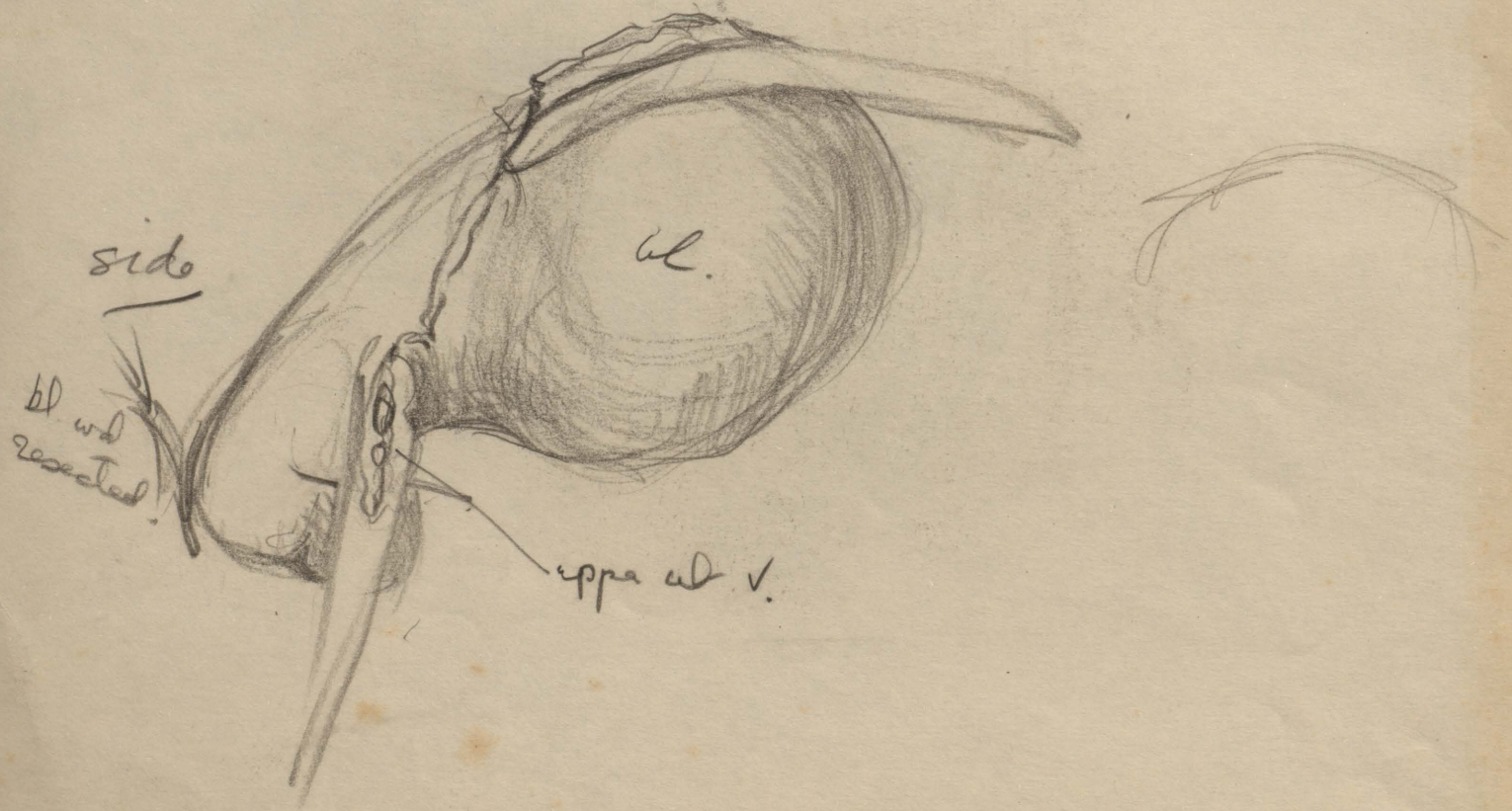
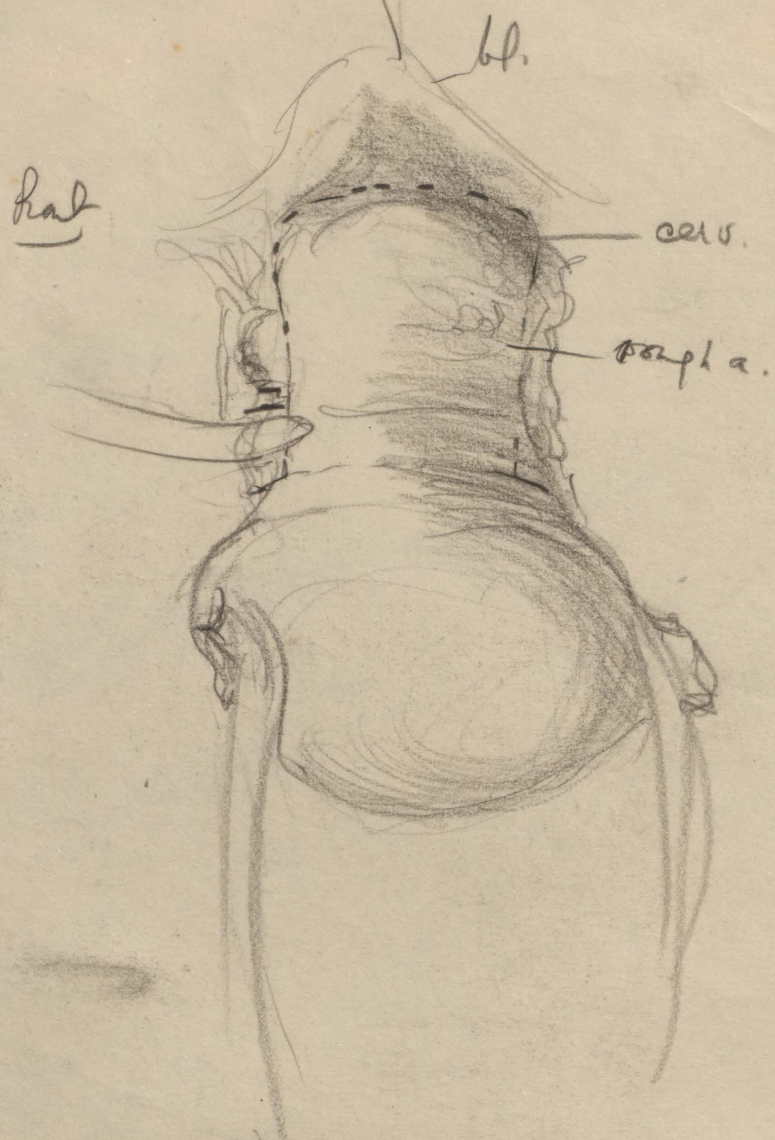
cutaneous ant. brachii med. n.
median n.
Triceps brachii m.


ulnar n.
Brachial a.
Basilic v.

Pronator teres

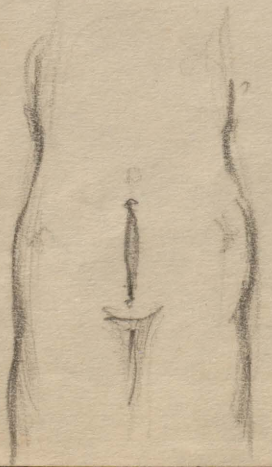

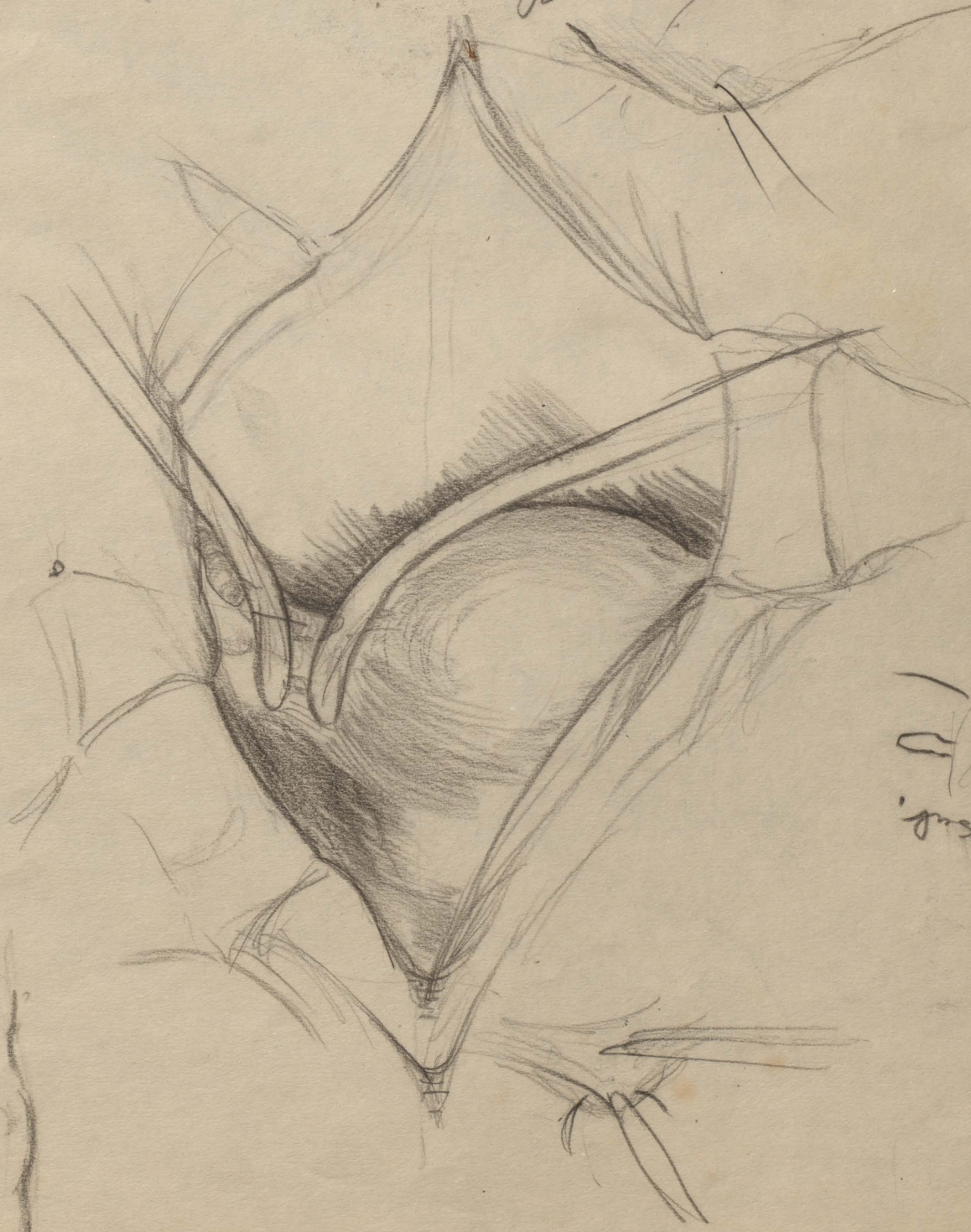
lacertus fibrosus








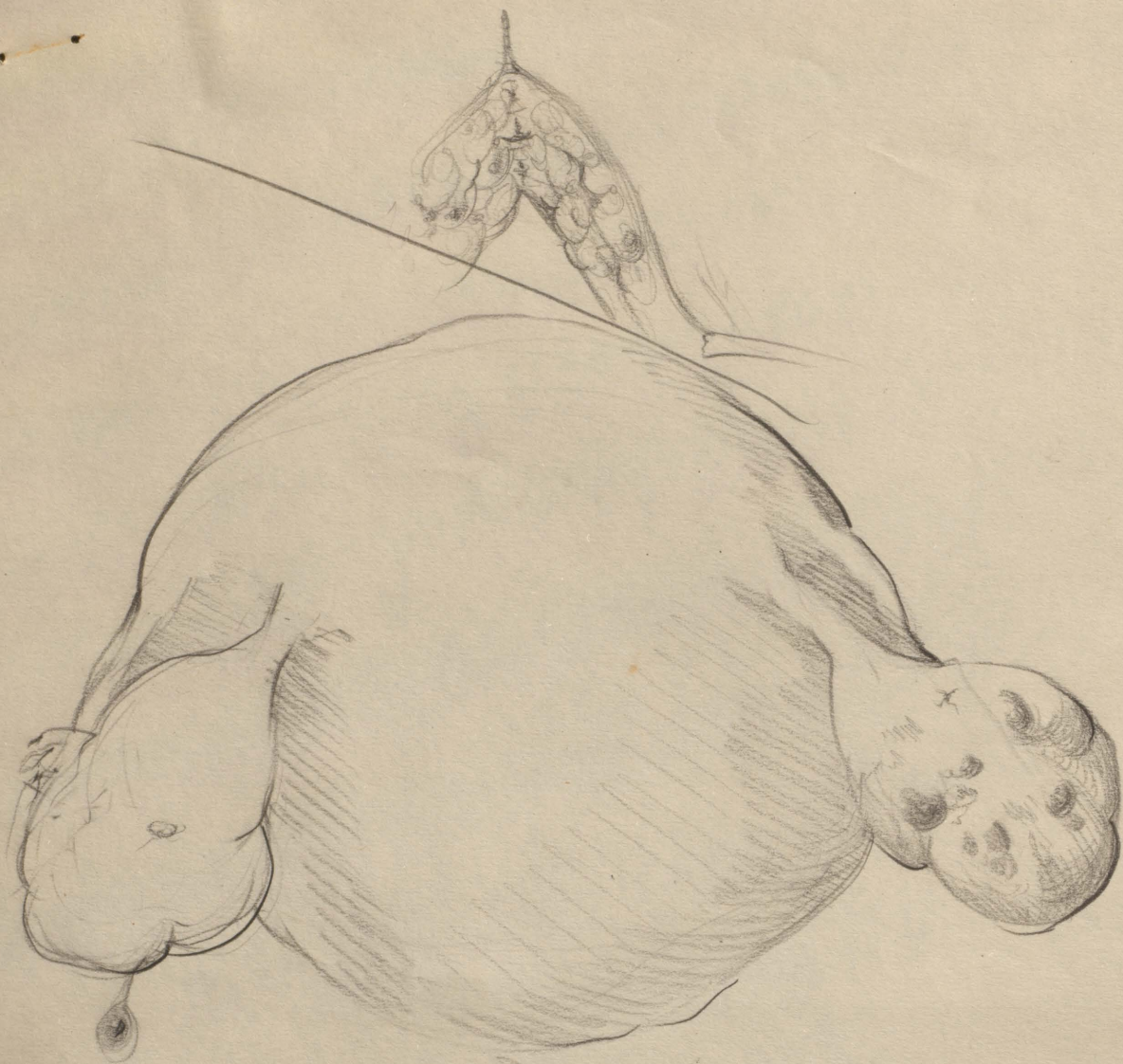
2



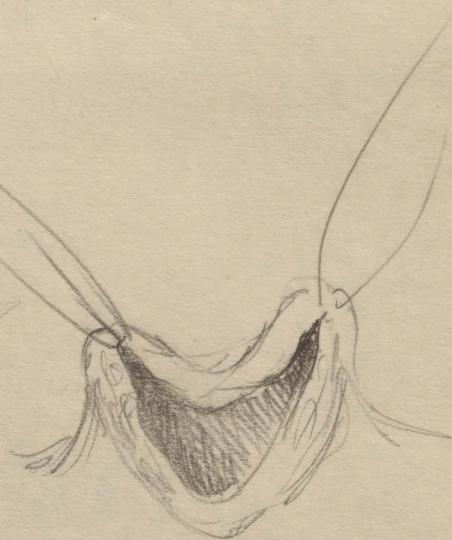March 21st 35

March. 16th

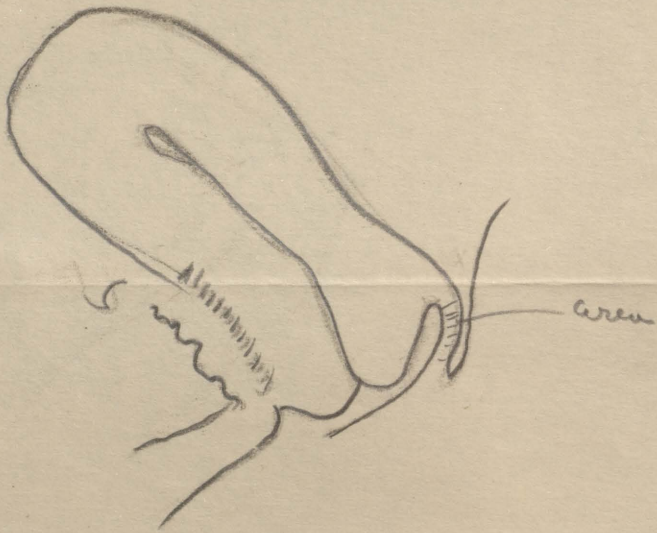
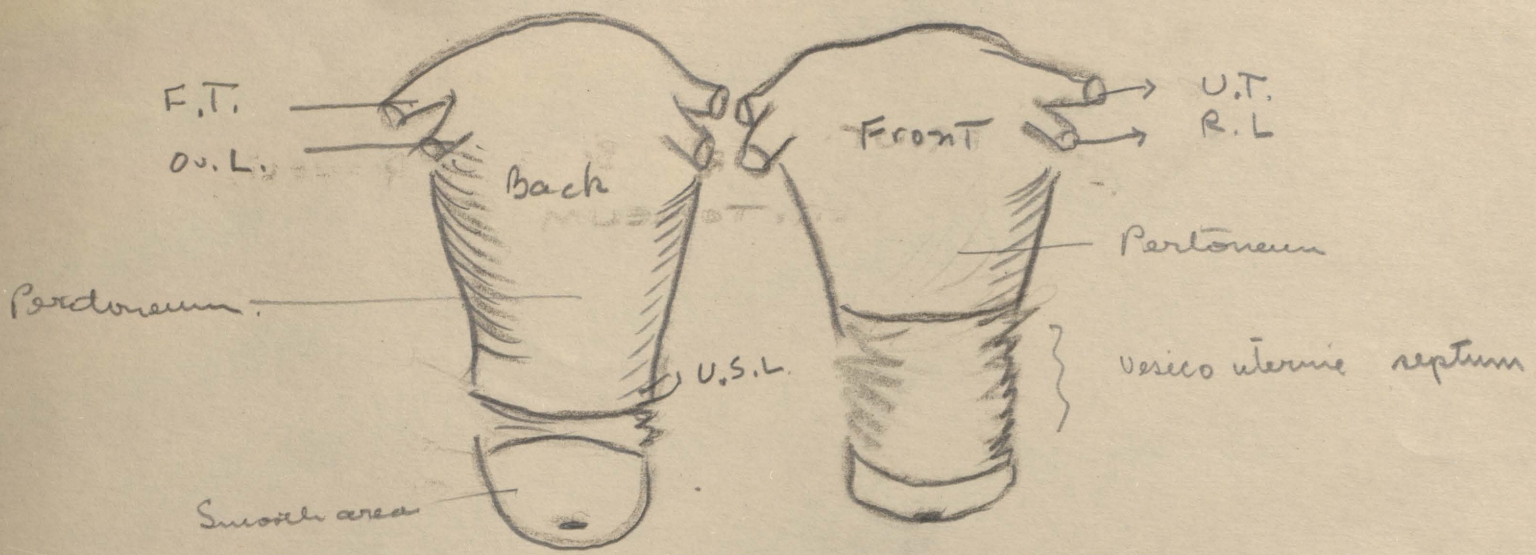
Hysterectomy.

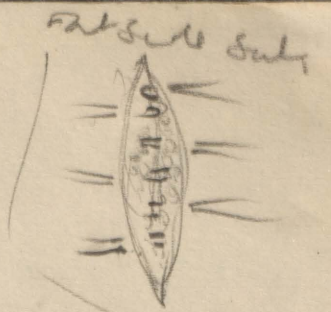


uterus sac - ligo

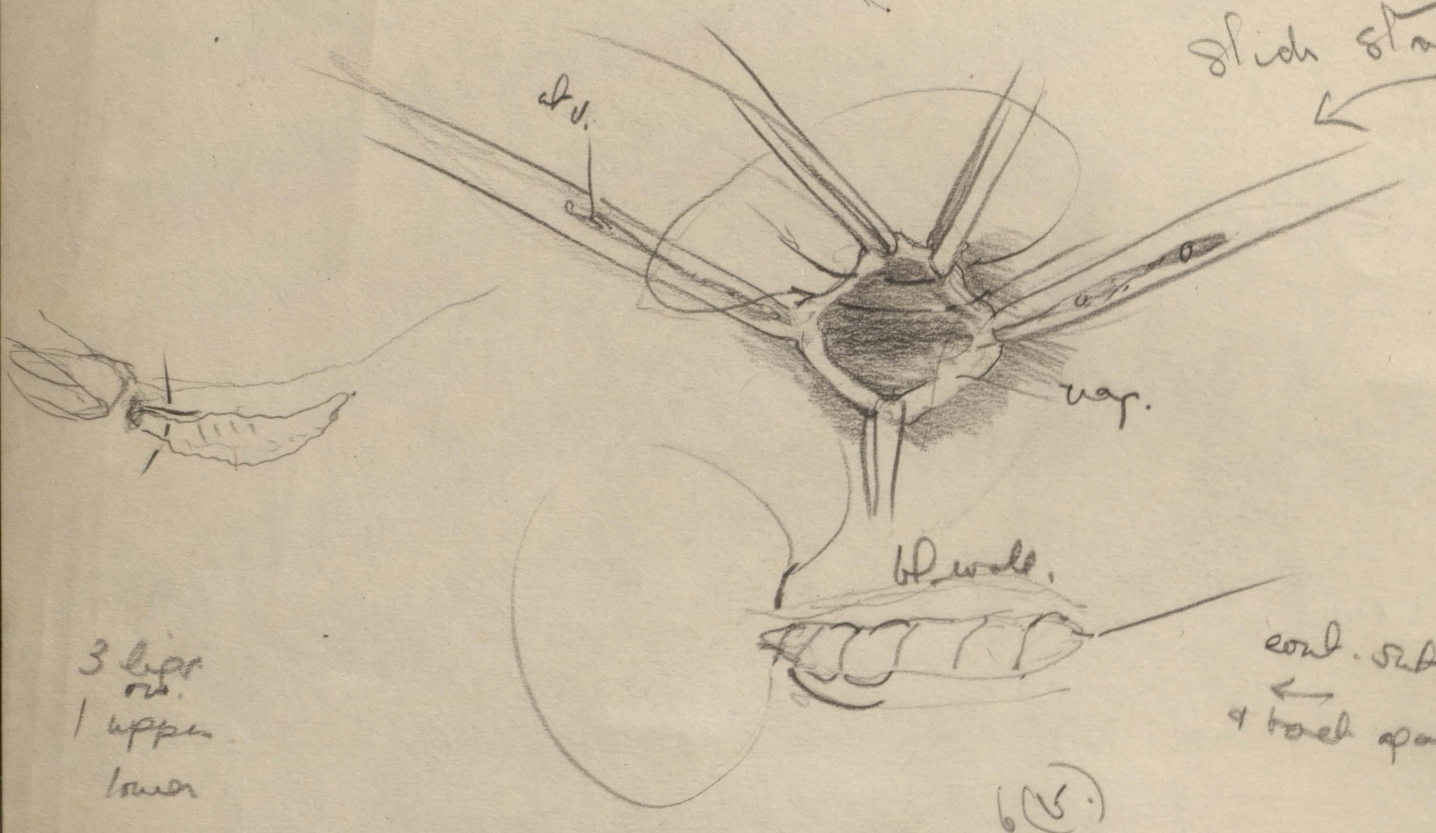


Vag. held up



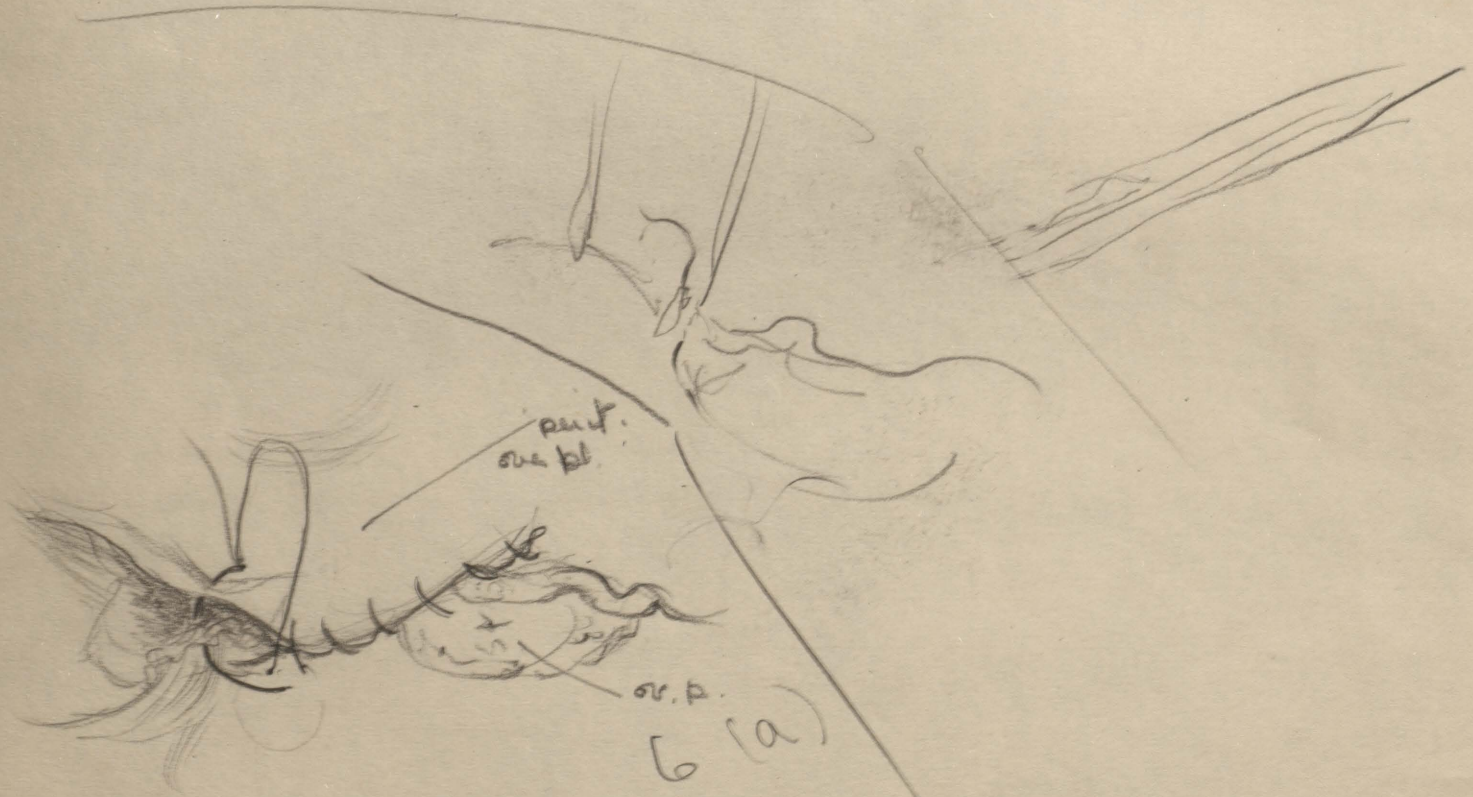

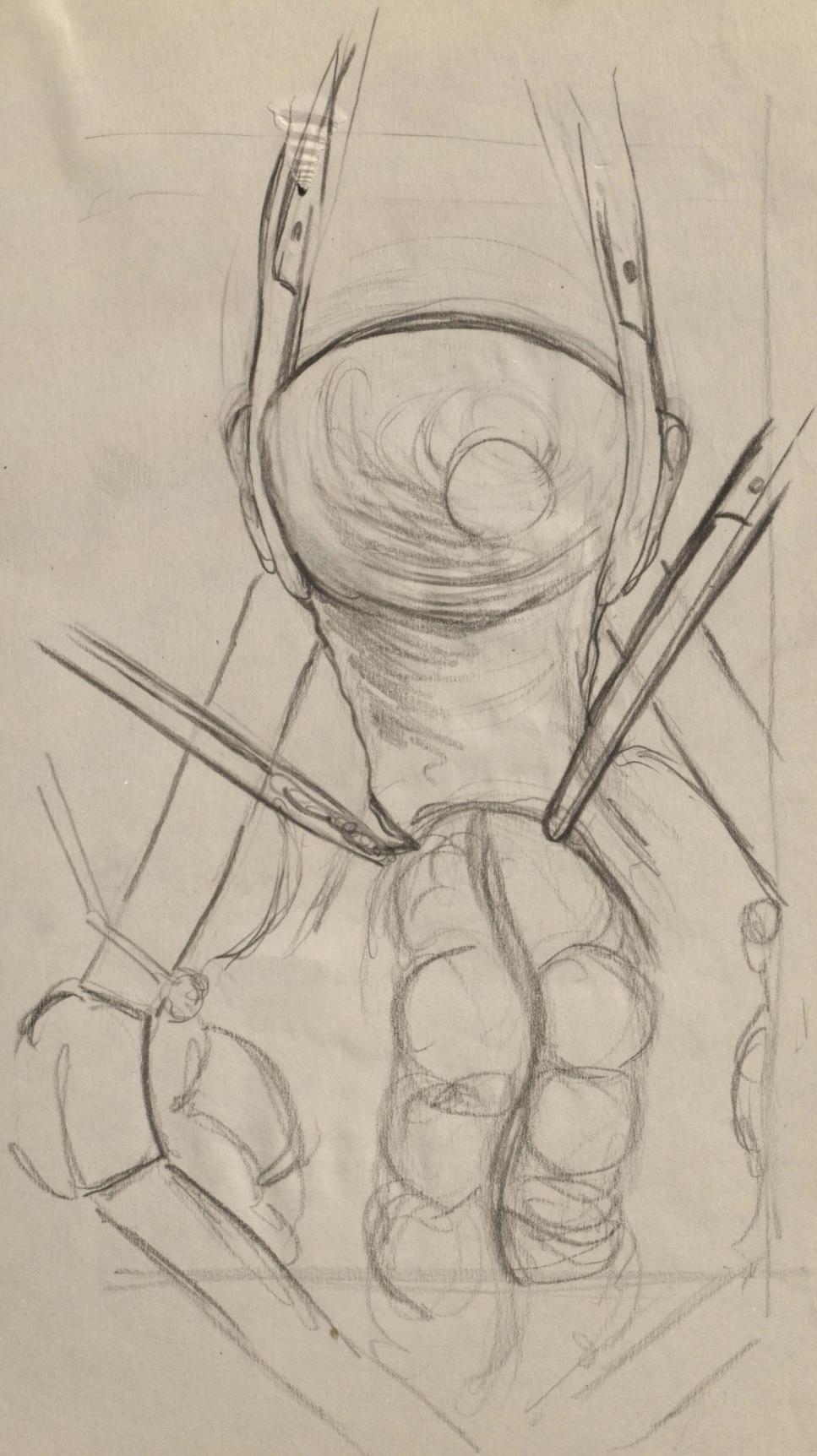
5
slide staining
←

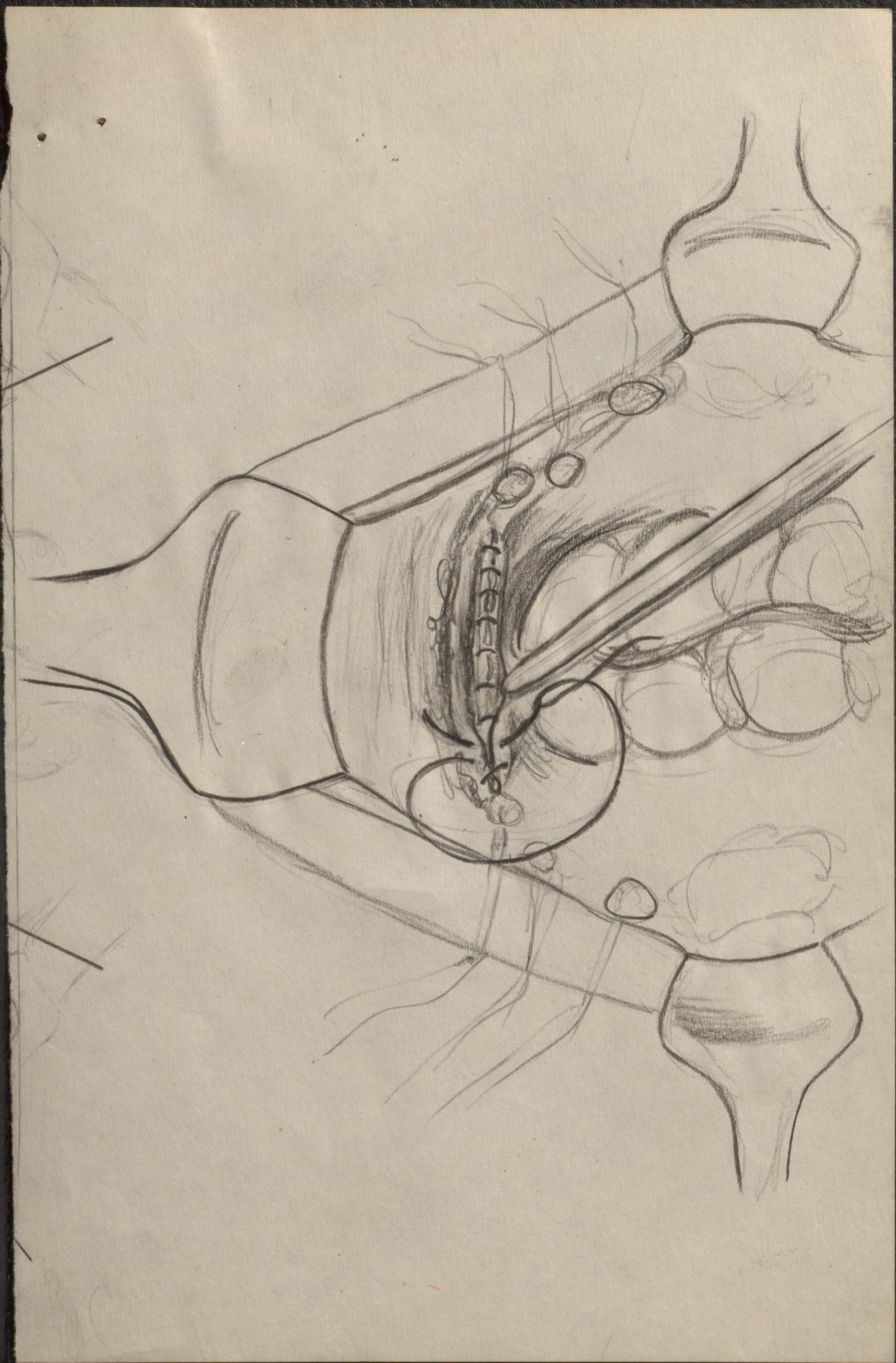


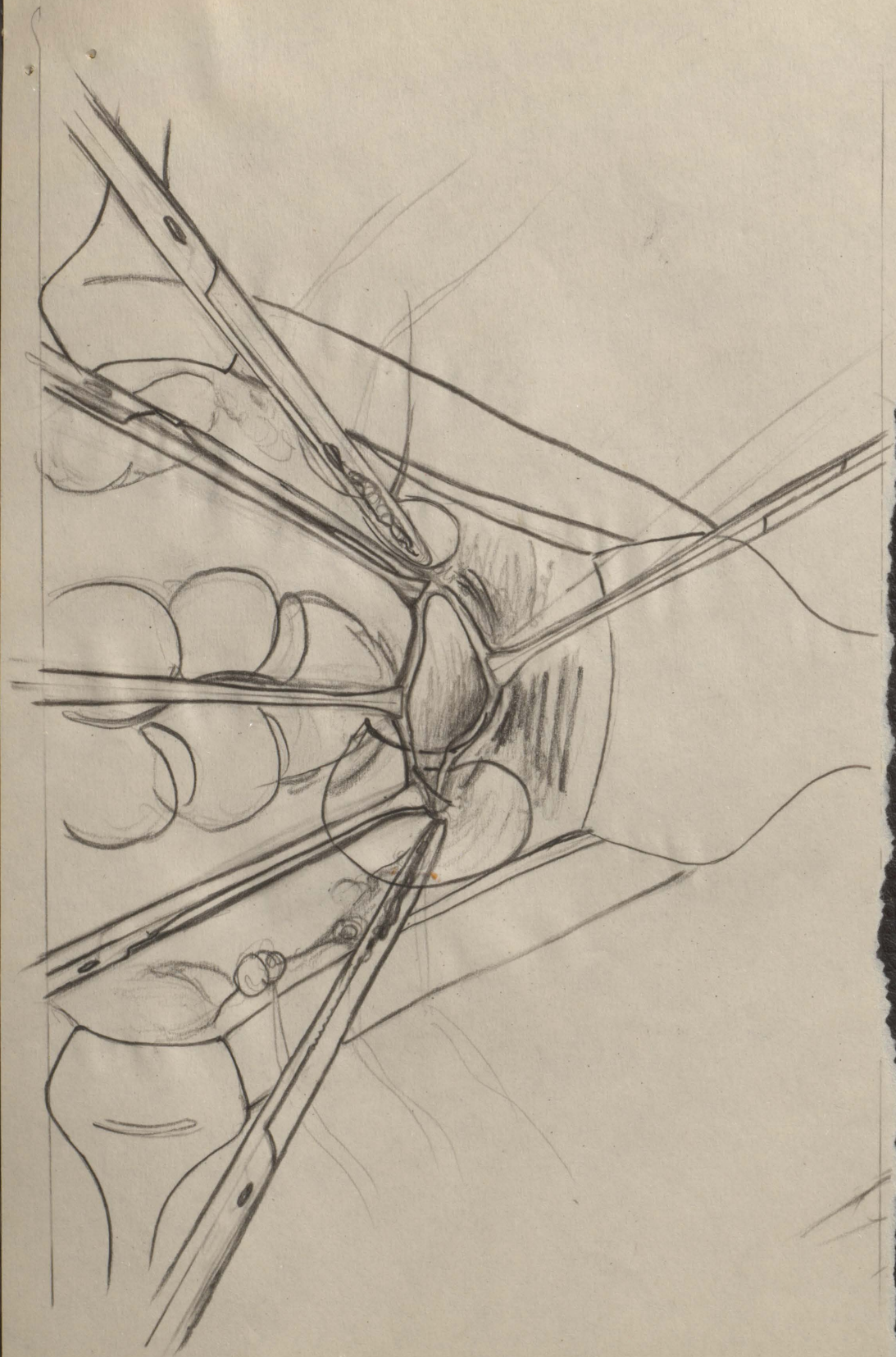
3 lips
1 upper
1 lower

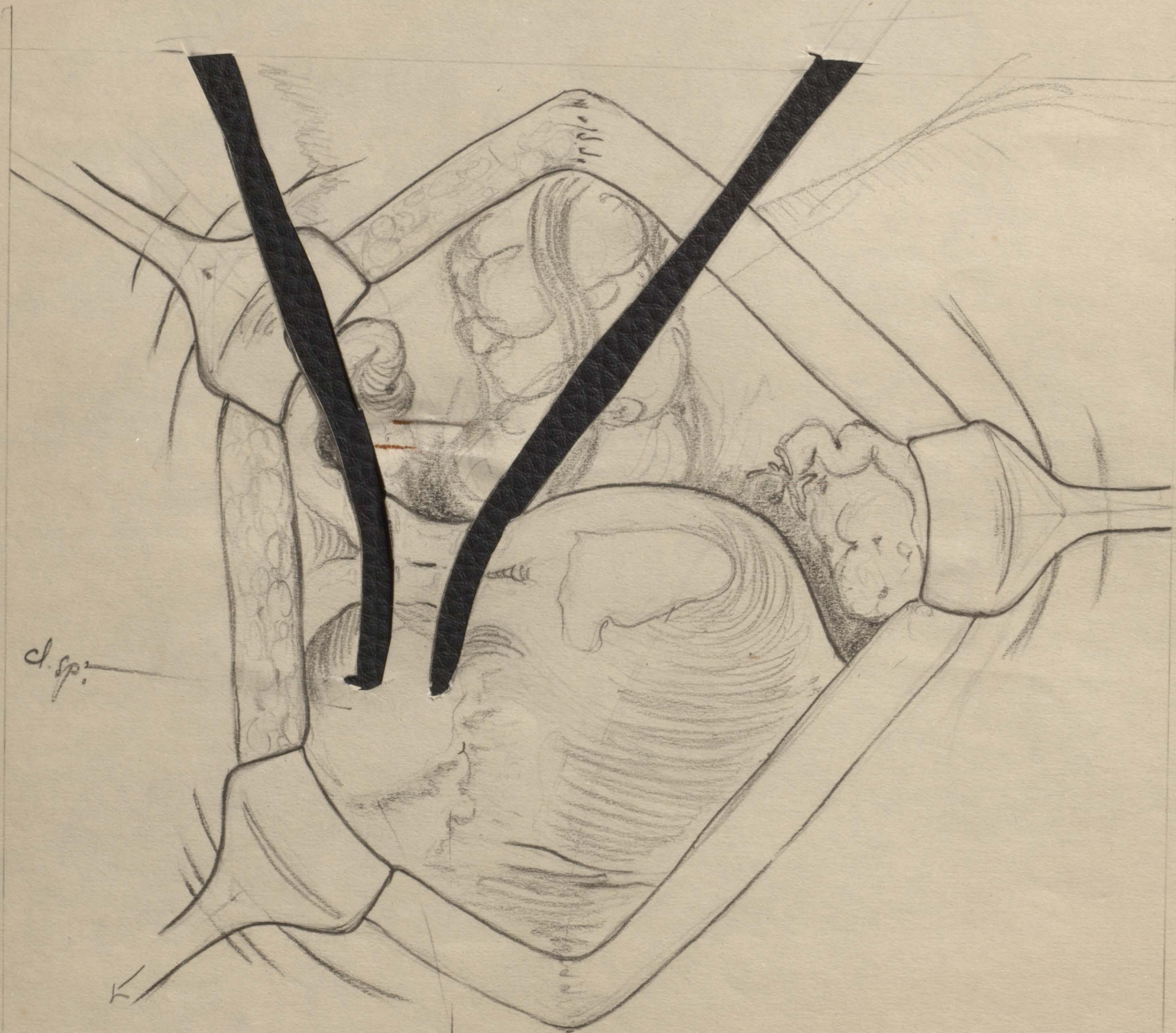
cont. sub.
←
4 tooth spines + tip







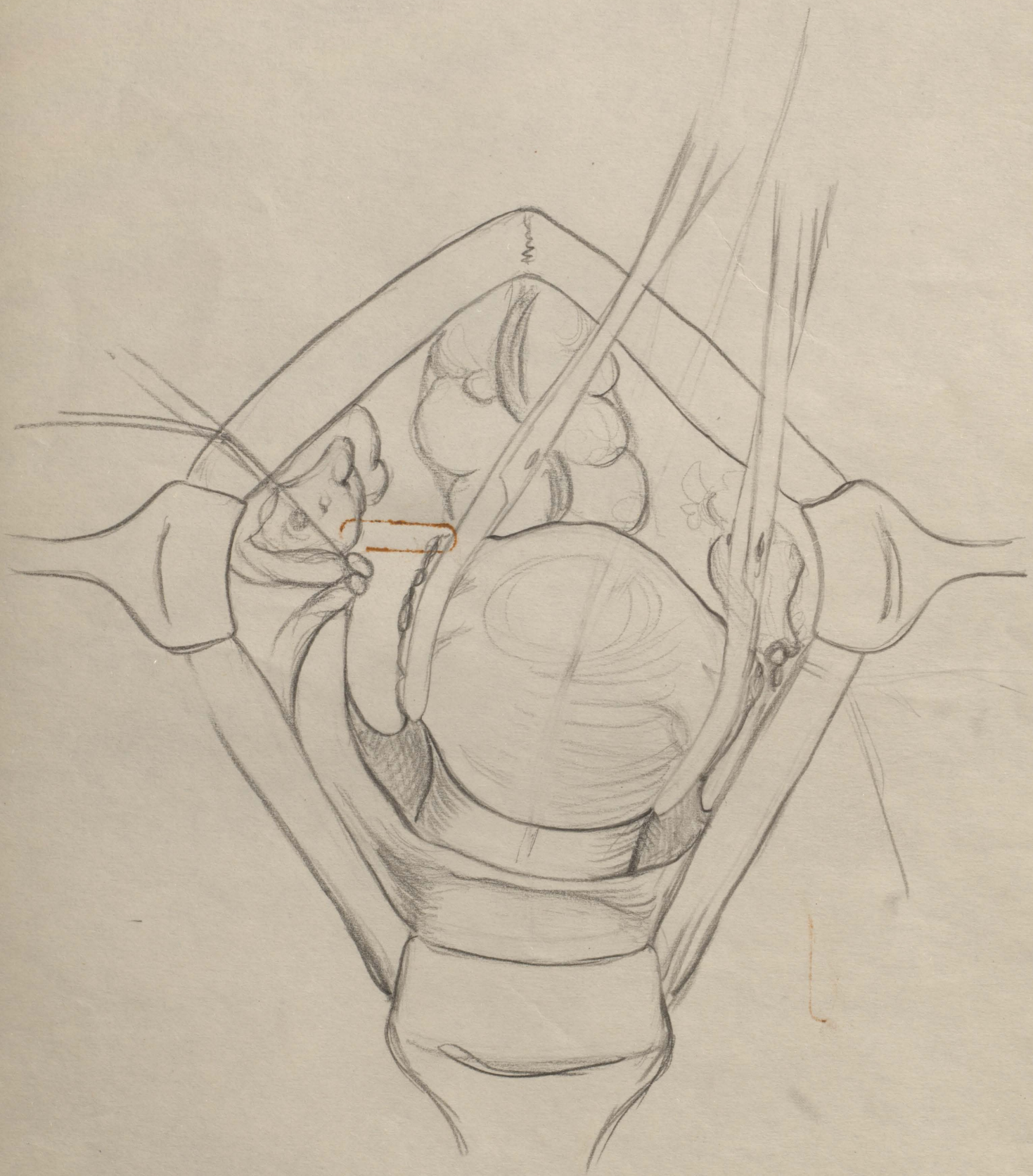


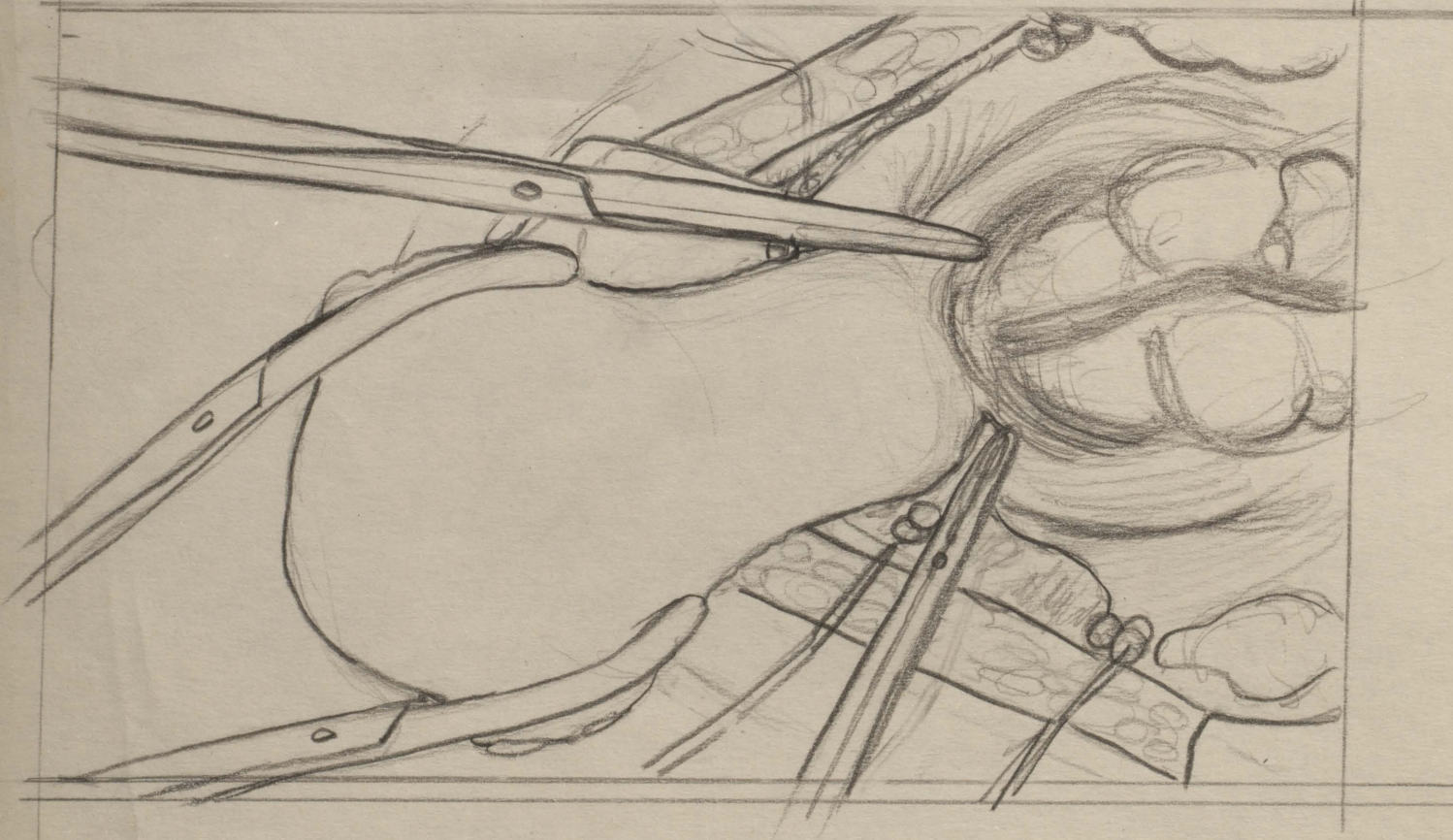
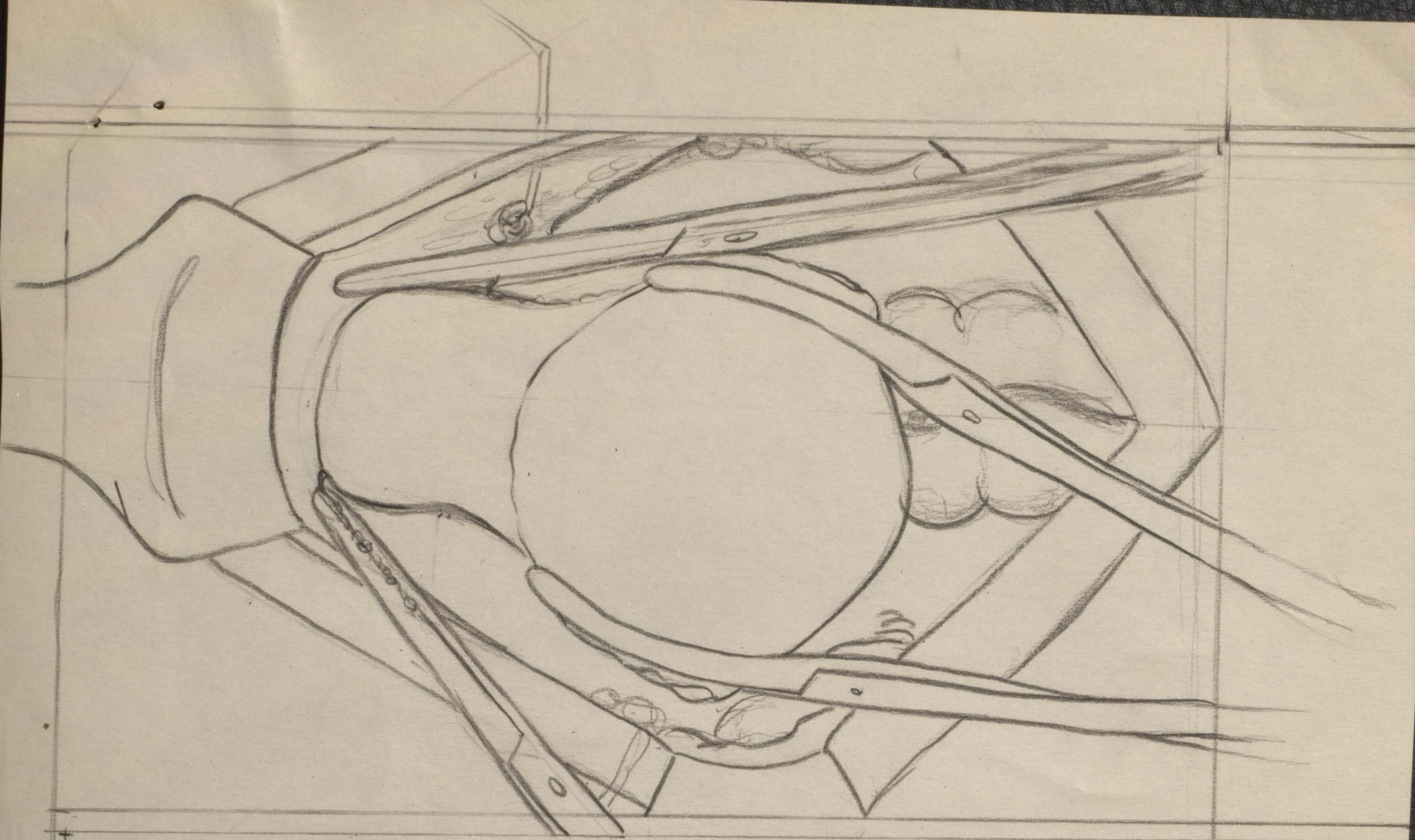


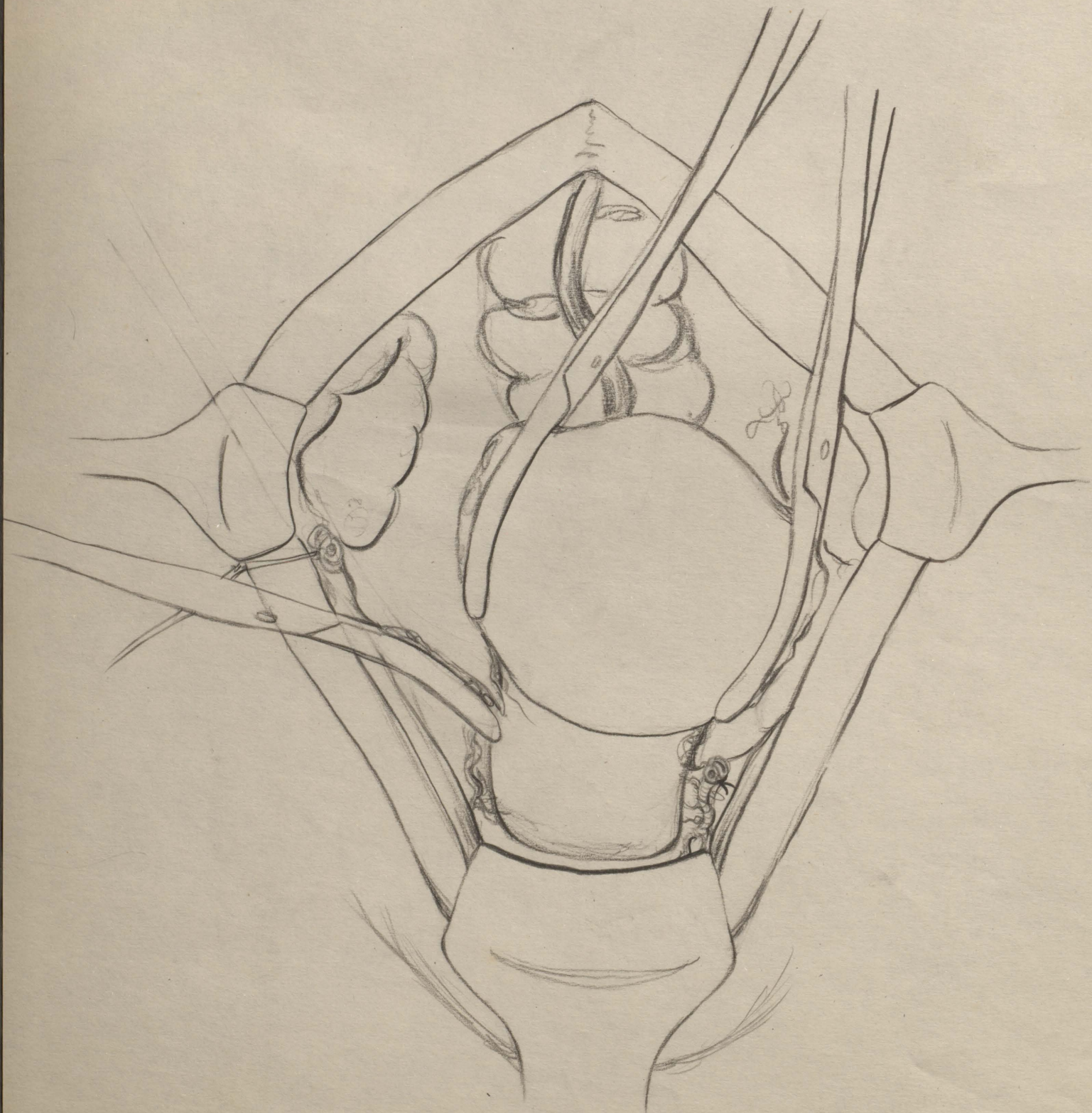
d. sp.

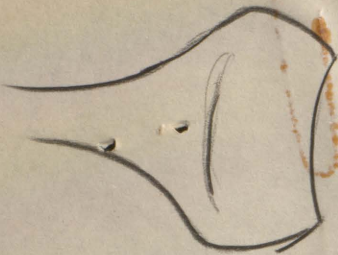
K

u.v.





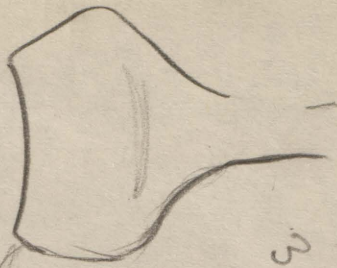



20
1.40

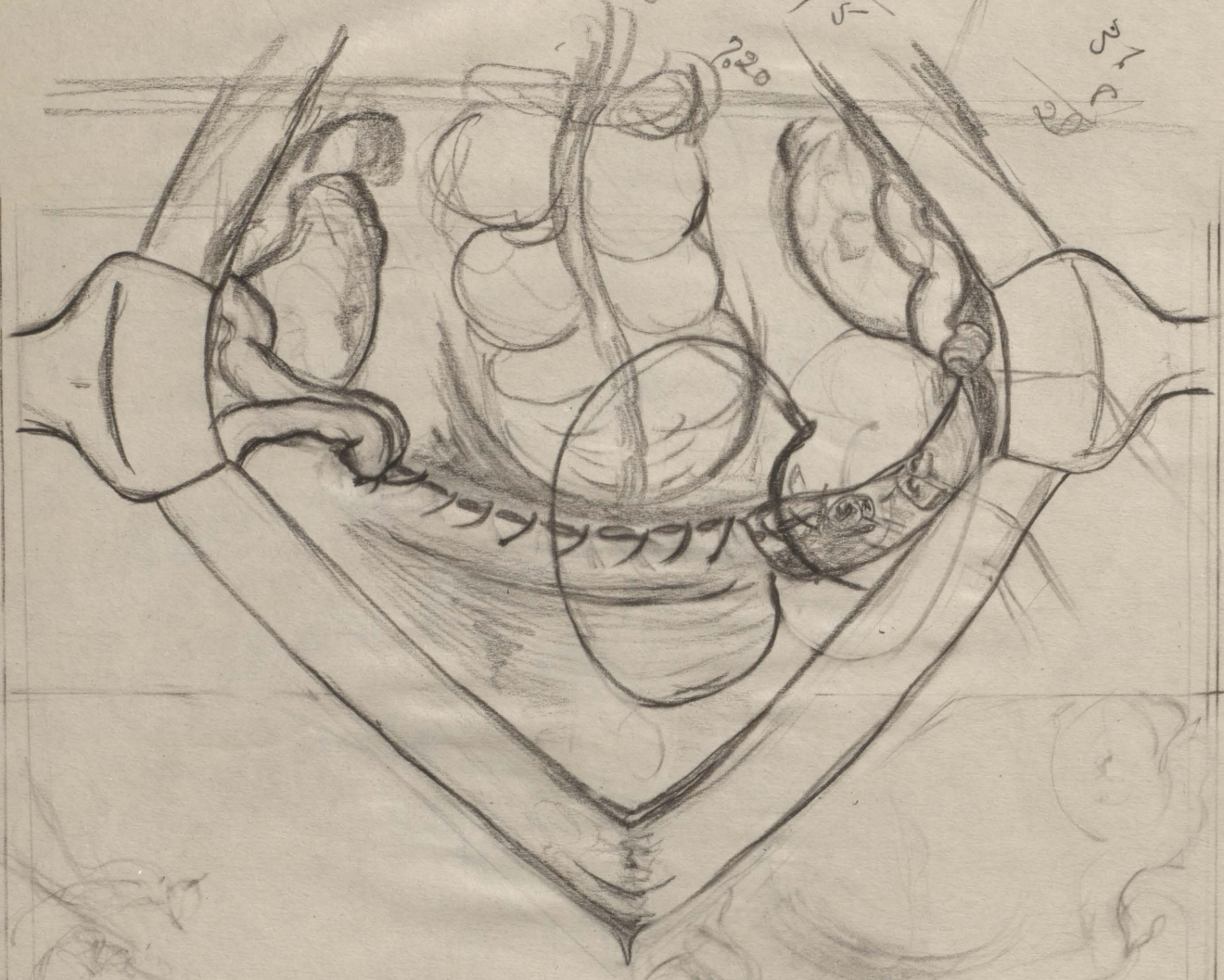
20
1.00

5 17.20
155
6.75



12
3720
48

20
1.00



20