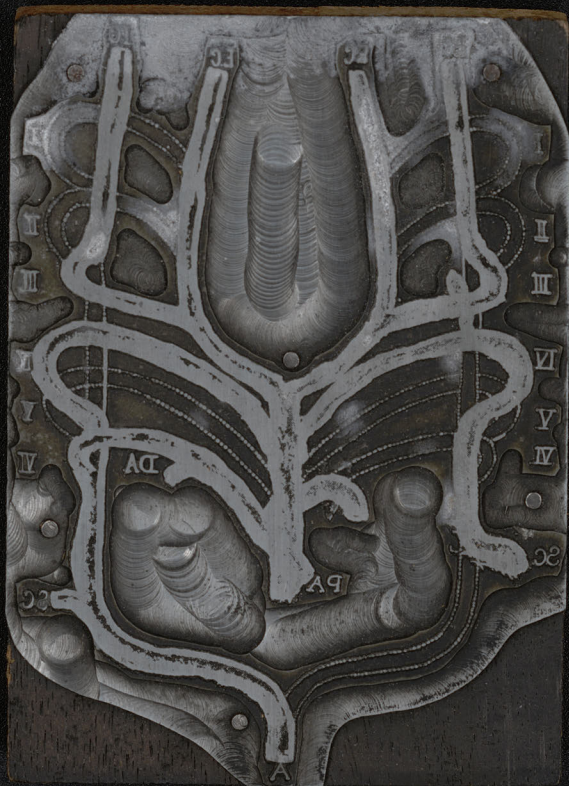

An anatomical engraving of a human torso, showing the ribcage, spine, and internal organs. The image is heavily redacted with a dark, semi-transparent overlay. The redaction covers most of the central and lower portions of the torso, leaving only the upper ribcage and some anatomical details visible. The engraving includes various anatomical labels such as 'A', 'B', 'C', 'D', 'E', 'F', 'G', 'H', 'I', 'K', 'L', 'M', 'N', 'O', 'P', 'Q', 'R', 'S', 'T', 'U', 'V', 'W', 'X', 'Y', 'Z', 'AA', 'BB', 'CC', 'DD', 'EE', 'FF', 'GG', 'HH', 'II', 'JJ', 'KK', 'LL', 'MM', 'NN', 'OO', 'PP', 'QQ', 'RR', 'SS', 'TT', 'UU', 'VV', 'WW', 'XX', 'YY', 'ZZ', 'AAA', 'BBB', 'CCC', 'DDD', 'EEE', 'FFF', 'GGG', 'HHH', 'III', 'JJJ', 'KKK', 'LLL', 'MMM', 'NNN', 'OOO', 'PPP', 'QQQ', 'RRR', 'SSS', 'TTT', 'UUU', 'VVV', 'WWW', 'XXX', 'YYY', 'ZZZ', 'AAA', 'BBB', 'CCC', 'DDD', 'EEE', 'FFF', 'GGG', 'HHH', 'III', 'JJJ', 'KKK', 'LLL', 'MMM', 'NNN', 'OOO', 'PPP', 'QQQ', 'RRR', 'SSS', 'TTT', 'UUU', 'VVV', 'WWW', 'XXX', 'YYY', 'ZZZ'.

Warning:

Some images may be
disturbing to some viewers.

Graphic content has been redacted.
Unredacted copies at the end.







Волосъ
Дугообразная железа

Волосъ

Железа
Дугообразная


Ложка слезная
Дугообразная

Дугообразная железа

Волосная железа
Дугообразная

Волосная железа
Ложка слезная

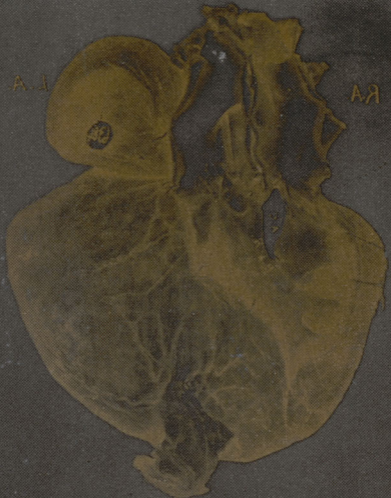Ложка слезная





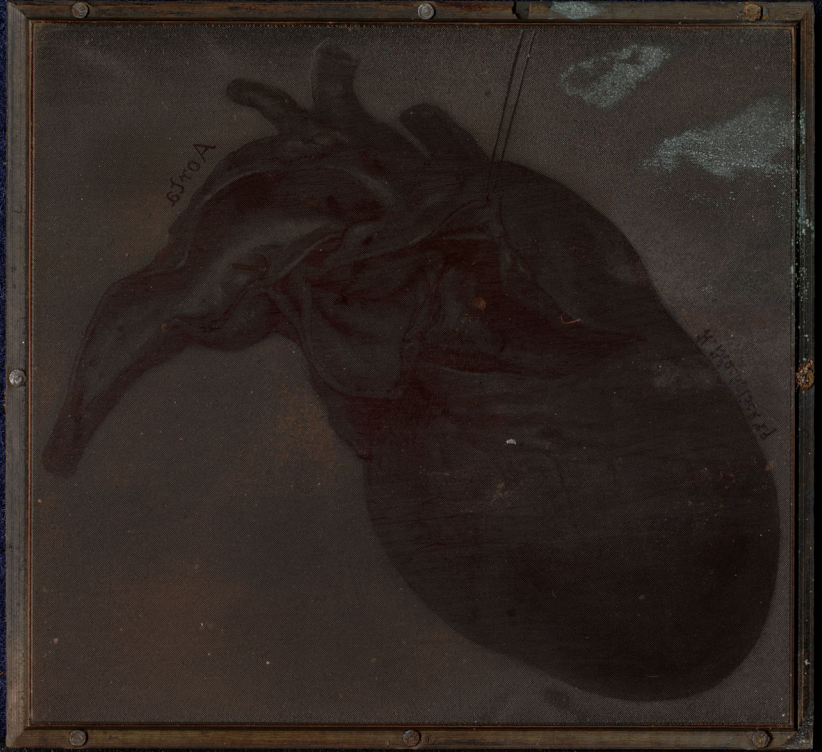A.I.

RA



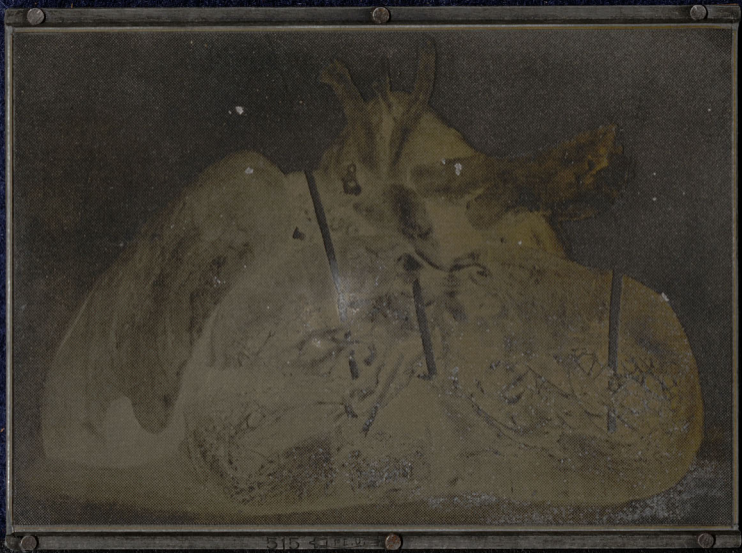CC



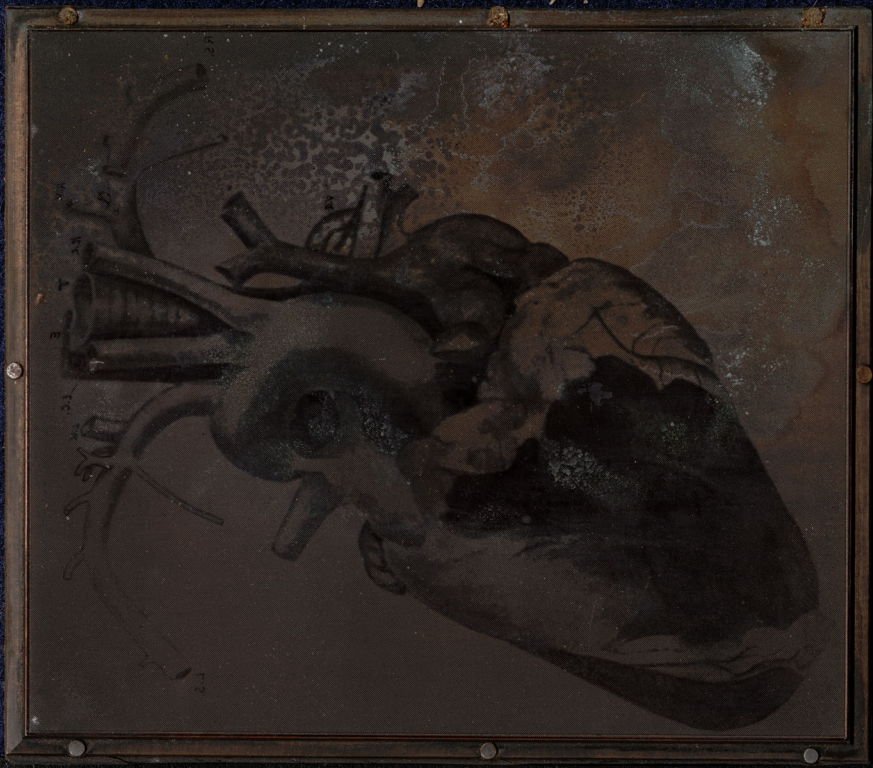

A. 100

F. 100



515 4115



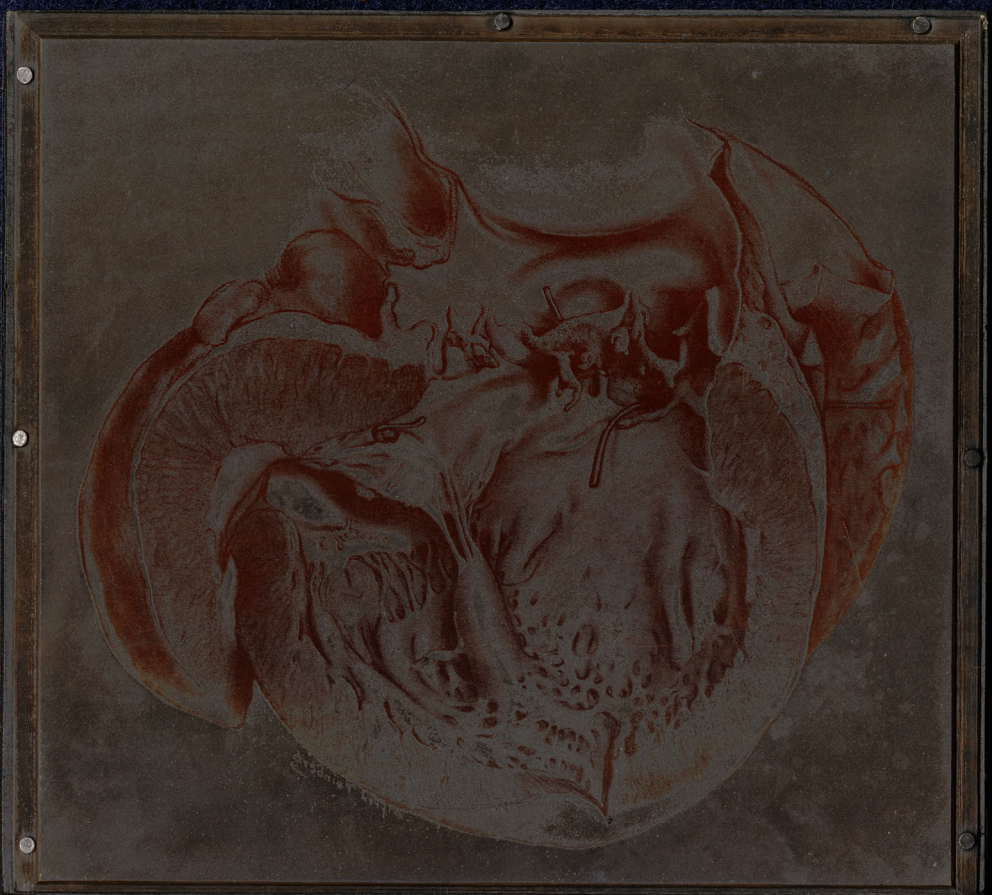RA

LA



RIB 21 P. 10






**Warning:
Graphic Content**

unredacted copy at the end









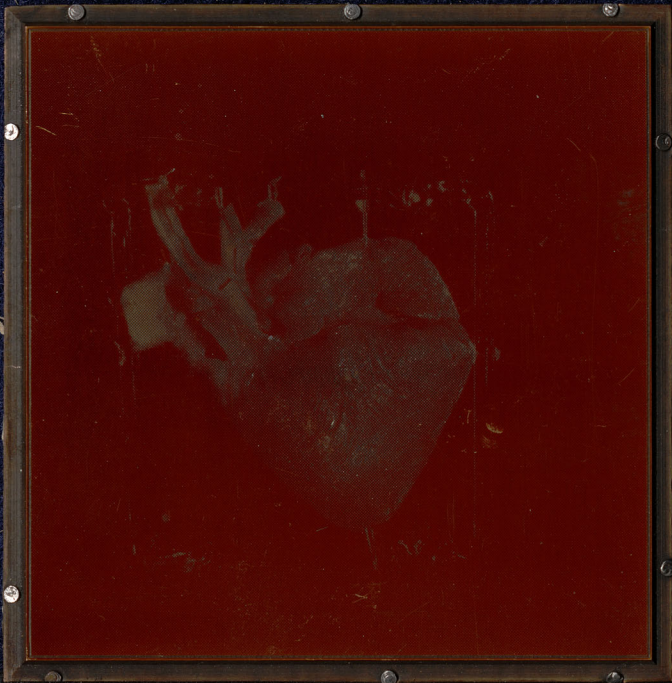

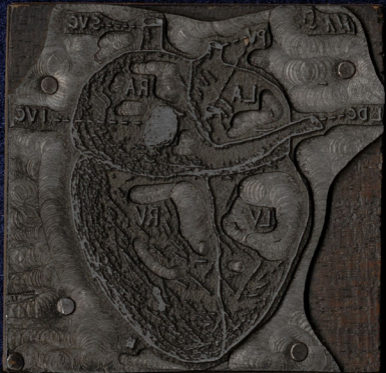




PLATE 100

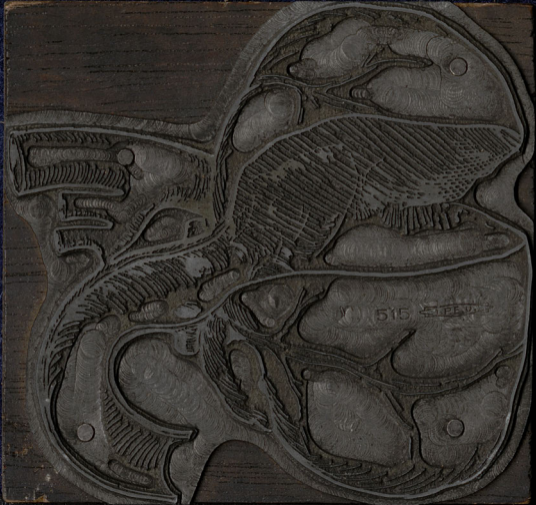












515 SPEYER



**Warning:
Graphic Content**

unredacted copy at the end

NOV 18 1885



**Warning:
Graphic Content**


unredacted copy at the end

**Warning:
Graphic Content**

unredacted copy at the end





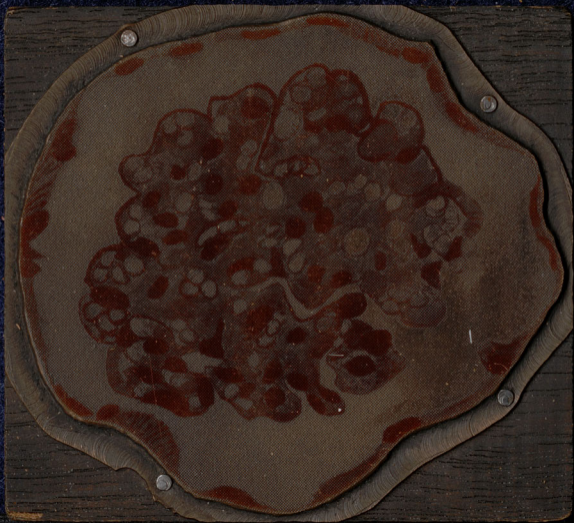

1894 C. S. V.



**Warning:
Graphic Content**

unredacted copy at the end





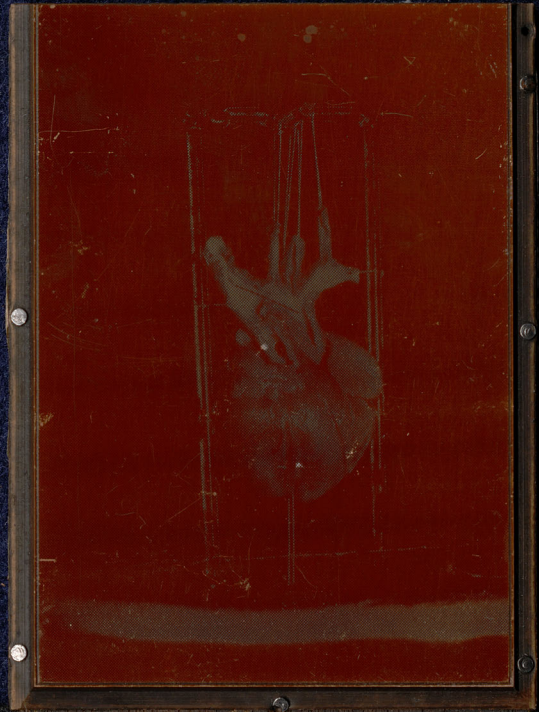513

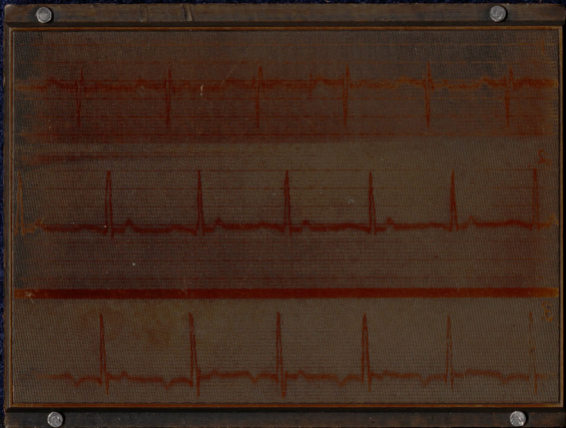
Warning:
Graphic Content

unredacted copy at the end










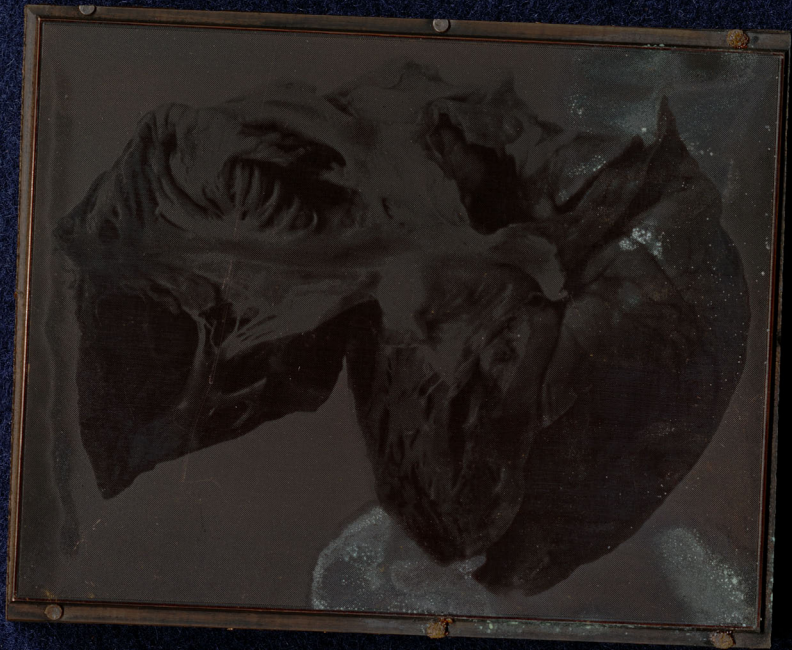


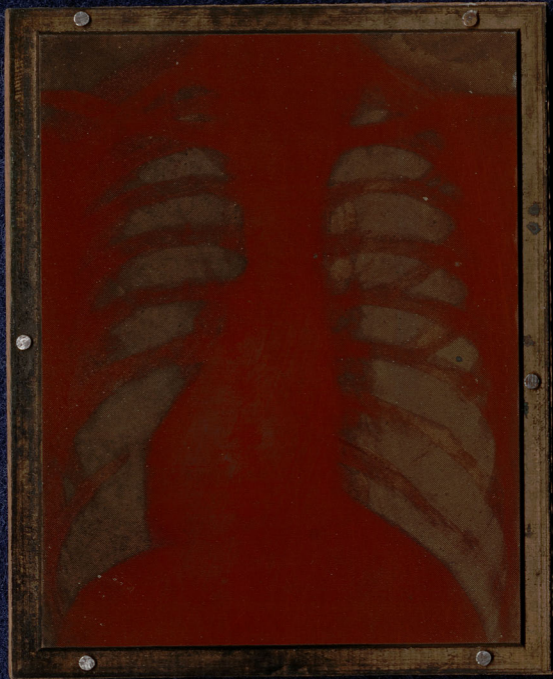
R

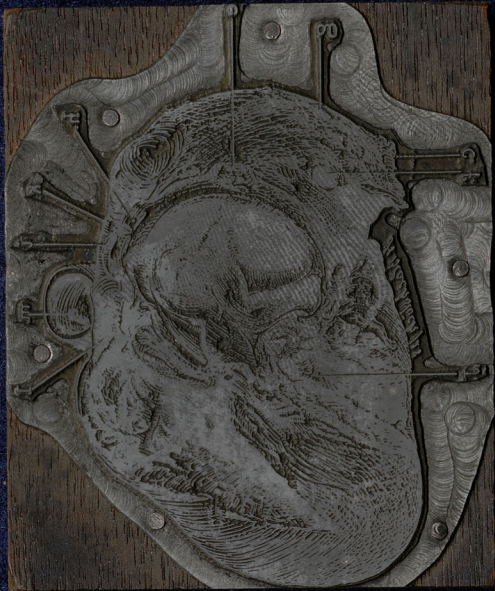






























**Warning:
Graphic Content**

unredacted copy at the end

Sections from A 194/36
Hamilton Medical

muscular
Haemangioma of mitral valve.

MCCUTCHEON, M.D.
490 York Street
MILTON - ONTARIO



OFFSETS.

Conspicuous Heart
disease -

Dr. M. Abbott

PLATES FOR MAUDE ABBOTT'S
ATLAS.

SLIDES showing information about content. Not listed in M. Abbott. Atlas of congenital heart disease.

Plate 24.

Fig. 1
Fig. 2 a + b
Fig. 3b.
Fig. 4 + b
Fig. 5.

Plate 6.

Fig. 1, 2, 5 on slide
Fig. 6
Fig. 7.

Slide Hand

fusion, adversely upon one
tion has become depressed
rasitic individual has re-
in the body of the larger
certain members or parts
reformed, and with heart
in the variety known as
at homologous twins are
iduals (Stockard'), and so
metrical double monsters
that in the asymmetrical
larger member of the pair,
as not been interfered with,
maturity as an individual
nal in all respects, except
and members or parts of
present case, however, we
most forms of congenital

GERMAN DIAGRAMS OF HEA

Congenital heart
under
na

Collection. Loc. Plate 16. Fig. 9

McGill University Clinical Collection
Cat. No. 14.1318
Defect of circulation in P

MISCELLANEOUS SLIDED SHOWING
NO INFORMATION, and not listed in
Abbott. Atlas of Congenital Heart
Disease.

DR. ABBOTT'S HEART SLIDES

Slides of x-ray and electrocardiograph
pictures of heart.

Plate V

Fig. 2 a + c
Fig. 2 b.
Fig. 3

Warning:

Some images may be
disturbing to some viewers.
Graphic content ahead.







