(15)

~~Osler 16~~
WG. 7.

7657. 'Acute Pneumonic Tuberculosis.'
MS. read before the Tuberculosis Society, London, 24 Mar., 1919, with 14 photographs. Unpublished, except in abstract, Lancet, 1919, i, pp. 615–16 (cutting in no. 3577).

7657

OSLER, sir William 1849-1919.

MS. of An account of certain organisms occuring in the liquor sanguinis. 1873.

One of the earliest and best descriptions of the blood platelets. He noticed that white thrombi were almost entirely composed of them.

(15)

7657. 'Acute Pneumonic Tuberculosis.' MS. read before the Tuberculosis Society, London, 24 Mar., 1919, with 14 photographs. Unpublished, except in abstract, Lancet, 1919, i, pp. 615–16 (cutting in no. 3577).

Delivered but not published in full

"Acute Pneumonic Tuberculosis"

[An Address at the Tuberculosis Society March 24th 1919]

abstract published in The Lancet, Lond. 1919. i. pp 615-16.

ACUTE PNEUMONIC TUBERCULOSIS(1).

by

Sir William Osler, Bt., M.D., F.R.S.. Regius Professor of Medicine at Oxford University.

- - - - - - - - : : : : - - - - - - - -

That we must distinguish between an infection and a disease is ~~one of the~~ a lesson taught by tuberculosis. Most of us in this room - probably all of us - have been, and are, infected by Koch's bacillus, we are tubercular but few (none of us I hope) are tuberculous in the sense of being actually diseased.

Granted that infection takes place, as a rule, in childhood , the two important problems are:-

1. ~~The favouring of conditions that may~~ How to render this infection less widespread, and
2. A knowledge that will ~~enable us to~~ prevent the ~~potential~~ actual infection (harboured by all) from becoming the ~~clinical~~ potential disease fatal to so many.

This conversion of the an infection into a disease is so slow that it is impossible as a rule to fix a day, a week or even a month for the onset of clinical symptoms. On the other hand Tuberculosis ~~as~~ an infection may cause a disease the symptoms of which ~~may~~ begin with great abruptness.

I have tabulated here the acute forms; ~~many of which begin with great abruptness:~~ slide

~~(see next page)~~

- -

x Tuberculosis Society, March 24th, 1919.

ACUT

Serous Membranes { d. Acute Lymphadenitis. e. Acute Synovitis.

fect- cide nditions,

knew

ACUTE TUBERCULOSIS.

- A. GENERAL
  - 1. Acute Toxemia
  - 2. Miliary tuberculosis.
- B. LOCAL.
  - 1. Pulmonary
    - a. Miliary
    - b. Broncho-pneumonic
    - c. Pneumonic.
  - 2. Cerebro-spinal
    - Meningitis.
  - 3. Lymphatic and Serous Membranes.
    - a. Pleurisy
      - Acute suppurative
      - Sero-fibronous
      - " "
    - b. Pericarditis
    - c. Peritonitis.
    - d. Acute lymphadenitis.
    - e. Acute Synovitis.

1a 2

ACUTE TUBERCULOSIS.

- A. GENERAL
  - 1. Acute Toxemia
  - 2. Miliary tuberculosis
- B. LOCAL.
  - 1. Pulmonary
    - a. Miliary
    - b. Broncho-pneumonic
    - c. Pneumonic.
  - 2. Cerebro-spinal.
    - Meningitis.
  - 3. Lymphatic and Serous Membranes.
    - a. Pleurisy
      - Acute suppurative
      - Sero-fibronous
      - " "
    - b. Pericarditis.
    - c. Peritonitis.
    - d. Acute Lymphadenitis.
    - e. Acute Synovitis.

r exam-
are
e
vely
-
e of
requently
hospitals
fatal
s of the
fect-
cide
nditions,
knew

ACUTE TUBERCULOSIS.

- A. GENERAL
  - 1. Acute Toxemia
  - 2. Miliary tuberculosis.
- B. LOCAL.
  - 1. Pulmonary
    - a. Miliary
    - b. Broncho-pneumonic
    - c. Pneumonic.
  - 2. Cerebro-spinal
    - Meningitis.
  - 3. Lymphatic and Serous Membranes.
    - a. Pleurisy
      - Acute suppurative
      - Sero-fibronous
      - " "
    - b. Pericarditis
    - c. Peritonitis.
    - d. Acute lymphadenitis.
    - e. Acute Synovitis.

The mode of origin of some of these we know well, as for example, the generalised miliary tuberculosis; but of others we are very doubtful. e.g. the tuberculous meningitis, and the acute tuberculous pleurisy, the acute toxemia, too, with comparatively slight lesions, the febris tuberculosa peracuta, ~~or~~ the typho-bacillose of the French.

Of all types on the schedule, the acute penumonic is one of the least common and illustrates a variety seen much more frequently in general hospitals than by specialists on the diseases in hospitals for consumption or in sanatoria. One of the most rapidly fatal of all forms, it presents pathological and clinical problems of the greatest interest.

have led me to the conclusion that the changes in organs affected by tuberculosis are not essentially different, but co-incide completely with the inflammations arising under abnormal conditions, and more particularly the chronic forms of infection."

It must not be forgotten, however, that even to the men who knew

Laennec, it was not easy to accept the specificity of all tuberculous

The history of this form is well given in Lepine's thesis*, (Paris 1872 3.4 in the monographs of Tendeloo, and of the Fraenkel and Troje, and the more recent papers in . I would like to mention just three points:-

In the first place, the name 'Caseous' or 'Cheesey' , the specific feature of tuberculous lesions, was first applied by Mangetus, the well-known Geneva physician in his edition of the Sepulchretum of Bonetus, 1700. An interesting point is that in the 48th observation of the Additamenta he not only mentions the word but he describes apparently for the first time miliary tuberculosis - scattered granules throughout all the organs which he compares to grains of millet.

The second fundamental point was the recognition by Laennec of the identity and specific character of all tuberculous lesions, whether ~~as~~ small tubercles, yellow tubercles, caseation, or gelatinous infiltration. How little he regarded ordinary pheumonia as related to tuberculosis is witnessed by the separate treatment of the two diseases in vols. i and ii of his original edition.

And the third point is of special interest to us this evening. Until the middle of the last century Laennec's views prevailed, and all were, as we are now, unicists. Then came the great heresy in which, as younger men, we were all involved, ~~and it~~ which started with a remarkable paper by Prosektor Reinhardt at the Charité Hospital, Berlin, whose name appears as co-editor with Virchow on the title page of the early volumes of the famous Archives of pathological anatomy. Reinhardt's paper in vol. i of the old series of the Charité Annalen opens with the statement

> "A series of observations on the development of the tubercle have led me to the conclusion that the changes in organs affected by tuberculosis are not essentially different, but co-incide completely with the inflammations arising under abnormal conditions, and more particularly the chronic forms of infection."

It must not be forgotten, however, that even to the men who knew

Laennec, it was not easy to accept the specificity of all tuberculous lesions. So keen an observer as Andral, the editor of the third edition of Laennec's great work, thought that tubercles could be a consequence of inflammation (Clin. Méd. 1834, T. IV, pp. 1-4), and Rayer believed in thetransformation of hepatisated lung into tubercle. 6

Cruveilhier (Traité d'Anatomie Pathologique T. IV) regarded tubercles not as the chief danger in pulmonary phthisis, but remarks that if we could only guard the tuberculous lungs from the consecutive pneumonia, many patients recover.

It may be said that in the seventies, with the exception of certain of the leading clinicians in France, and here and there one in England and the United States, the Virchow School was dominant. It is interesting to look back at the discussions which took place at that period. ~~When a student in London in 1872-3, I often had the pleasure of hearing Wilson-Fox discuss the question with my old teacher Burdon Sanderson.~~

Now I mention these points because it was the ~~group~~ (the) of cases we are to consider this evening that forced the conviction on many minds that an ordinary pneumonia might terminate in caseation.

cles in the bronchial glands and scattered groups in the lower left lobe. He was admitted cyanosed and delirious.

V. No. 1690 f. (London Hosp. Mus. - Dr. Turnbull) man aged 29, who died in the eighth week of the illness in the Bethnal Green Infirmary (Dr. Potts). Typhoid fever was suspected. With the exception of a small patch at the right lung, the left lung only was involved. The specimen shows well the bronchial origin, the peripheral caseation , and the gradual fusing of the masses. Histologically extensive caseous bronchitis.

SO FAR THESE SPECIMENS SHOW THE EARLIER STAGES.

VI. No. 3378 (R.C.S.) presented to the Museum by Sir James Paget who has written an admirable description:-

"The lung was enlarged, solid and heavy, by a diffuse infiltration

The lesions – Caseous Pneumonia

Nodular – above in a lung

~~PHOTOGRAPHS.~~

I. 3374 (R.C.S.). one lung uniformly involved. solid and airless, but on closer inspection:- – Enlarged

No 2. II. It is seen that the lung is everywhere stuffed with small tubercles, many of which have coalesced to form diffuse caseous areas. As is seen, they are chiefly about the small bronchi.

III. No. 1718 a. (St. Bart's Hosp.) from a man aged 40 who died about the 4th week of an acute illness - consolidation of the left lung, pleurisy, and pneumothorax. Here, too, the earlier stages of the process are seen in the upper part of the lung, where the tubercles are discrete, but below there is uniform caseous infiltration.

IV. Specimen no. 0045 (Guy's Hosp. Mus.) from a male, aged 19, with practically complete caseation of the right lung, without cavity ~~formation~~, but with an old scar in the apex. There were a few tubercles in the bronchial glands and scattered groups in the lower left lobe. He was admitted cyanosed and delirious. – Left heart & dilat. ankle alved. ed

V. No. 1690 f. (London Hosp. Mus. - Dr. Turnbull) man aged 29, who died in the eighth week of the illness in the Bethnal Green Infirmary (Dr. Potts). Typhoid fever was suspected. With the exception of a small patch at the right lung, the left lung only was involved. The specimen shows well the bronchial origin, the peripheral caseation, and the gradual fusing of the masses. Histologically extensive caseous bronchitis.

SO FAR THESE SPECIMENS SHOW THE EARLIER STAGES.

VI. No. 3378 (R.C.S.) presented to the Museum by Sir James Paget who has written an admirable description:-

"The lung was enlarged, solid and heavy, by a diffuse infiltration

"of dull, yellowish-white tuberculous matter through its whole texture. None of the original texture of the lung can be discerned, scarcely even does a blood-vessel of air-tube appear pervious in it, but it is uniformly solid, and its colour would be uniform were it not for the black matter which was deposited in it before the tuberculous disease. In a few places small, broken-walled cavities have been formed after the softening of the tuberculous matter."

Here, too, on close inspection one may see in places the bronchial origin.

VII. This is a specimen of much the same type, practically the whole lung infiltrated, also described by Sir James Paget in the following terms:- " The lung is compact and heavy but brittle, the surface is smooth and firm, of a pale yellowish-white colour, marbled and mottled with various shades of grey, with black matter deposited in spots and lines." Two beginning ares of softening are seen. ~~The final stage~~

VIII. No. 1718c.1. From a woman, aged 26, under the care of Dr. G. who died at the end of 4 or 5 weeks' illness. The three interesting points are:-

First, the upper lobe still shows lung texture with bronchi and blood vessels. 2. The lower lobe has reached the final stage of caseous transformation in which the texture is uniform, yellowish white in colour, no longer recognisable as lung tissue, and the bronchi and blood vessels involved in the caseation. And 3, the cavity which had ruptured, causing pneumothorax.

VIII a another specimen uniformly solid a

IX. No. 1718c.2. (St. Bart's Hosp.) Necrotic softening with the

and which extended along the main bronchus into the lung

with the entire lower lobe, dry, caseous and uniform. In the upper lobe are seen some of the coarse tubercles; the abdominal lymph glands were involved and the specimen looked as Dr Freund remarked like the pericardit of cable

1 The caseation we have considered
2. The cavities we have spoken of (1) old. (2) recent. (3) old partly healed scars Fig 9. Guys Hosp
3. Tubercles
specimen
see p. 10. above

8

Caseous Pneumonia.

rapid formation of large irregular cavities is well illustrated in this specimen. The entire lung is involved, the caseation advanced, the necrosis widespread, and in one of the cavities in the lower lobe is a large aneurysm from which the fatal haemorrhage occurred.

NOW IN ALL OF THESE CASES, SO FAR, THE INVOLVEMENT HAS BEEN OF THE ENTIRE LUNG, BUT THE DISEASE MAY BE MONOLOBULAR AS IN THE FOLLOWING SPECIMEN:-

X. No. 267 (Guy's Hosp. Mus.) From a case of extraordinary interest, a man aged 24, admitted under Dr. Washburn, with pain in the side, rusty sputum, and the general features of acute pneumonia. He died on the 8th day in hospital from pulmonary embolism. There was a small cavity in the apex of the left lung. The whole of the upper lobe was caseous. It was thought at first to be possibly grey hepatization, but microscopic examination showed it to be tuberculous. The specimen is of ~~special~~ exceptional interest in showing the rapidity with which advanced caseation may occur. Note particularly in the upper portion the granular character of the surface in contrast to the smooth uniform texture below.

XI. Specimen no. 09[73] (Guy's Hosp.) shows the not uncommon invasion of the lung from the enlarged and caseous bronchial glands, but I have not seen anything so extensive as this specimen. The child is aged 6 months, admitted Nov. 20th ,1909, and died on the 29th. Had been ill for some months with fever. ~~From~~ The fused group of right bronchial glands which were caseous, softened and purulent, and which extended along the main bronchus into the lung, and fused with the entire lower lobe, dry, caseous and uniform. In the upper lobe are seen some of the coarse tubercles; the abdominal lymph glands were involved and the specimen looked as Dr Freund remarked like the perlsucht of cattle

1 The caseation we have considered
2. The cavities we have spoken of (1) Old. (2) recent. (3) Old fibrotic scars Fig 9. Guy's Hosp Specimen
3. Tubercles

see p. 10. above

Caseous Pneumonia.

1 Mixed lung
2 Pneumonic nodules
3 Diffuse caseous

XII

~~Fourthly~~, ~~one sees~~ in these lungs, ~~in a typical form~~, the gelatinous infiltration of Laennec is seen in typical form. Let me give you the ~~great~~ master's statement of this remarkable condition, which he speaks of as 'jelly-like tuberculous infiltration':-

> " It is formed by a humid, rather than liquid matter, colourless or slightly sanguinolent, and more like a fine jelly, than serosity. At times one would be tempted to believe that this is only an oedema caused by a very viscous lymph, but this infiltration differs from pulmonary oedema by its scarcely, if at all, preserving a trace of the air-cells, which seem melted into jelly".

One sees this occasionally about the small tuberculous cavities in ~~the~~ a lung, about limited caseous areas, or about the grape-like groups of tubercles, but under no circumstances do we see it so widely extended, and in such typical form, as in the~~se cases of~~ acute pneumonic phthisis I have seen the anterior third of the upper lobe translucent, homogenious, and looking from the outside as if oedematous, but, as Laennec remarks, the condition differs clearly from ordinary pulmonary oedema. In the broncho-pneumonic type of acute pulmonary tuberculosis, portions of lung intervening between the caseous tubercles may present this gelatinous infiltration. It is curious how little attention has been paid to this by recent writers - indeed there are works on pathological anatomy, in which it is overlooked altogether. One may see in it small grey areas standing out strongly against the reddish infiltration, and it was an exceedingly acute observation of Laennec, that this more solid grey infiltration and the crude, yellow, cheesy material arise directly in this gelatinous tissue. I would ask you to note particularly that he speaks of it as 'jelly-like tuberculous infiltration' inwh ch he was unquestionably correct, as I believe this is a

here

Could be differentiated
~~differs~~ from those of bronchial origin.

9

There ~~appear to~~ are be three modes of origin ~~in~~ of this ~~remarkable~~ type of ~~disease:-~~ tuberculous pneumonia

I. Haematogenous. This is only possible with ~~the~~ a local infection of the pulmonary artery or one of its branches, and a case in point is reported by Tendeloo which has the additional interest of being one of the earliest ~~post mortems~~ autopsies on record, death having occurred on the 8th day ~~of which I know, is A case reported by Tendeloo (~~Studien über die Ursachen der Lungenkrankheiten, 1902, Pg.391) ~~in which~~ death occurred in about the 8th day of an acute illness. The patient was a dissipated woman, aged 40, who was admitted delirious, dyspnoeic and cyanotic on the sixth day of the illness and died two days later. The upper part of both lungs was airless, reddish-grey in colour, smooth on section, contained everywhere small greyish-yellow masses, most abundant in the upper, more solid portions of the lung. The smaller areas were rounded, the larger more irregular and less clearly defined. The crepitant portions of the lung were oedematous and congested. A point of special interest is the fact that at the apex of the left lung there was an old caseous, tuberculous focus, the size of a walnut. In the middle of this was a vein almost completely filled with a fresh clot, where an erosion had taken place through the wall. Bacilli were found in the adherent clot. In the neighbourhood of the vein was a contracted, caseous branch of the pulmonary artery.

You remember that in Figs i and ii the condition looked very like a very intense miliary tuberculosis of the lung, and it is quite possible that the early lesions in the haematogenous cases

lymph glands were involved, and as Dr. French remarked, the specimen somewhat resembled a perlsucht of cattle.

Could be differentiated
d~~iffers~~ from those of bronchial origin.

II. Bronchogenous. Obviously in a majority of the cases the infection is bronchogenous, an aspiration process, ~~what~~ and it has been very well called by Heller and Hedinger primary alveolar tuberculosis. The infection arises from a small focus usually at the apex, or there is an erosion of a bronchous ~~from~~ by a tuberculous gland. The earliest specimen in my series was on the 13th day. The lower lobe was uniformly solid, with innumerable small grey bodies, a little larger than miliary tubercles, many fusing and becoming caseous, the intervening tissue deeply congested and in places gelatinous.

(2) Fraenkel & Troje's 5th case (Uber die pneumonische Form der acuten Tuberculosis, Berlin, 1893. Sonder-Abdruck aus der Zeitschrift für klinische Medicin. Band XXIV. Heft 1 u.2, 3 u.4.) died on the 13th day of the disease with a diagnosis doubtful between an acute caseous pneumonia, and a fibrinous pneumonia in a previously tuberculous individual. The patient was aged 28, had pleurisy two years previously, sickened on November 19th with a severe chill

2.

followed by pain in the side, cough and dyspnoea. Admission - Nov. 26th; signs of involvement of both lungs, tubercle bacilli in the grass-green sputum; death on December 1st - on the 13th day from the chill. P.M. Left lung heavy, and part of the upper lobe airless, consistence everywhere increased; on section, numerous small greyish-red areas surrounded by dark, congested, infiltrated tissue. Those masses were scattered throughout the right lung as well, in the upper lobe of which in many places they had fused into larged areas froming greyish-red masses. In the intervals between these, there was much gelatinous infiltration. At the apex of the right lung there was a small cavity, the size of a nut, with caseous walls and indurated tissue about it.

There is a remarkable specimen at Brompton showing uniform

Modes of origin (1). Haematogenous diffe Nubary. Tuberdoo.. my case (17) 12
milli

11

One of the most careful studies of a bronchogenous case was made by Dr. Turnbull in specimen , of the London Hospital (No. V on the screen again)

care. The section shows the left lung solid from apex to base with the lobes adherent. The cut surface presents many irregular caseous areas, with infiltrated tissue between. The smaller areas, seen best at the base, are trefoil shaped, and may be seen grouped around the finest terminations of the bronchioles, which can be recognised clearly by the peribronchial anthrocosis. In many of the smaller caseous foci a black dot is seen in the centre. Here and there, intervening between the solid areas are strands of infiltrated tissue. Certainly the general appearance of the specimen suggests a bronchogenous infection. Dr. Turnbull tells me that the microscopic appearance bears this out in a striking manner There is a cheesy bronchitis of the smaller tubes, peribronchitis and caseous pneumonia of the surrounding alveoli; the pulmonary arteries corresponding to the bronchioles are thrombosed; even in the larger areas, it is easily recognised that the disease has started in and around the bronchioles, and has spread into the neighbouring alveoli. Tubercle bacilli in large numbers are present There was a small patch of the tuberculosis at the apex of the right lung - no other tubercles in the body.

The patient, aged 29, was admitted to the Bethnal Green Infirmary with an illness suspected to be enteric. He was in the hospital with high fever and signs of consolidation of the left lung. A fistula in ano developed.

There is a remarkable specimen at Brompton showing uniform caseation of a lung which followed erosion of the main bronchus by a tuberculous lymph gland.

Clinical features

15 7

ACUTE PNEUMONIC TUBERCULOSIS.

13 c

14

13

Caseous Pneumonia.

III LYMPHATIC. Colonisation through the lymph channels is a common mode of diffusion of tuberculosis, but it is rarely diffuse, and still more rarely associated with a wide-spread exudative process. Extensive caseation is met with in one mode of lymphatic invasion of the lung, ~~particularly~~ in children. ~~It not infrequently happens that~~ The bronchial lymph nodes enlarge and pass deep into the hilus of the lung, the tissue of which may be invaded directly. It is by no means uncommon, in a section of a lung of this sort, to find the chief involvement at the root, and it may be difficult to differentiate between the involved parenchyma and the enlarged caseous lymph-glands. Occasionally it happens that invasion from this source leads to uniform caseation of an entire lobe. Specimen 09[73] in Guy's Hospital Museum illustrates this. A child aged 6 months was admitted on November 26th, 1909 under Dr. Hale White and dies on the 29th. The illness had been of some weeks' duration, with wasting and fever and, towards the end, signs of meningitis. The bronchial glands were greatly enlarged and caseous. At the hilus of the lung these large masses had extended along the outside of the lower, main bronchus into the lung tissue, converting nearly the whole of the lower lobe into a caseous mass. There were tubercles in the upper lobe, and small tuberculous masses in the left lung. The mediastinal glands were enlarged, the abdominal glands cibro-caseous - as Dr. French, who made the Post-mortem, remarks, like Perlsucht in cattle.

This is the brain here - Ah

1 Ro
2 de

Clinical features

13c

ACUTE PNEUMONIC TUBERCULOSIS.

	Name		Age	Onset	Duration	Tub. Bac.	Result.
1.	G.R. (col.)	m.	20	Chill	10 wks	15th day	Death
2.	H.W.	m.	29	Chill	29 dys	21st "	"
3.	E.H.	m.	23	"	18 dys	15th "	"
4.	R.H.	m.	35	Acute	4 wks	21st "	"
5.	J.A.	f.	42	Acute	8 wks	Never found	"
6.	A.J.	f.	15	Chill	?	19th day	Improve.
7.	R.H.	m.	43	"	8 wks	40th day	Death
8.	A.H.	m.	52	Gradual	7 wks	14th day	"
9.	F.S.	m.	20	Chill	?	21st day	Improve.
10.	E.H.	f.	38	Gradual	6 wks	28th day	Death
11.	J.M.C.	m.	58	Haemop.	3 mos	Not fd	"
12.	M.G.	f.	25	Acute	?	15th day	Improve.
13.	E.L.	m.	45	Acute	13 dys	9th day	Death
14.	E.W.	f.	68	Chill	?	47th day	Improve.
15.	J.R.	m.	17	Haem. & chill	?	41st day	Improve.
16.	J.R.	m.	48	Chill	?	16th day	Improve.
17.	C.O.	m.	41	Chill	?	4th day	Improve.
18.	E.J.S	f.	21	Grad.	?	8th day	Improve.
19.	J.C.	m.	48	Grad.	8 weeks	?	Death
20.	F.H.	m.	19	Grad	?	21st day	Improve
21.	J.M. (Col.)	m.	22	Grad.	?	Not fd.	Terminal & Unsuspected.
22.	A.H. (Col.)	f.	26	Haemop.	5 wks	22nd day	Death
23.	C.T.	m.	21	Haemop.	?	3rd wk	Improve.

M. 16

F. 7

not fatal

frequency proportionate to the care with which it is looked for. There is no other condition - except perhaps gangrene - in which we see such

DIAGNOSIS.

It is unusual to recognise the true nature of the disease at first. There are four types of cases:-

1. The pneumonic. in which the disease sets in abruptly with a chill, pain in the sides, and all the features of an ordinary pneumonia.

2. I have frequently referred in my writings to the case of a cab-driver on whom I lectured for several weeks as a case of ordinary pneumonia. 10 cases in my series began with a chill, and cases were admitted to hospital with the diagnosis of pneumonia. The physical condition of the lung and the general features may be identical with the ordinary croupous form. There may be rusty sputum ~~in which are apparently~~ with pneumococci, ~~and~~ & streptococci the temperature may ~~be very much the same~~ high & uniform, and perhaps it is the second or third week before suspicions begin to be aroused, owing to the sweats and the changed character of the sputum, and suggestive physical signs. The leukocytes, as a rule, are not so much increased. In one case (No.) there was marked leukopenia, in another, (No.) there was an enormous increase, 92,000 per c.m., in another 32,000 p.c.m.

The condition of delayed resolution may be puzzling, particularly when the consolidation of the greater part of the lung persists for many weeks, but in these rare cases the fever is not high and the general symptoms are not severe, and the sputum is negative.

Careful and persistent examination of the sputum is the most important help in diagnosis. ~~Microscopically there is no feature of importance.~~ Probably no form of diffuse consolidation of the lung, ~~with which~~ do we so frequently ~~see~~ find a grass-green sputum. It was present in fully half of the cases, and its presence has been noted by Traube and many other writers. Tubercle bacilli are found in a large proportion of the cases. As these specimens show, ~~some~~ cavities are almost ~~in-~~ always ~~evitably~~ present, and the bacilli were found as early as the fourth, eighth, and ninth days in my series. In one case they were not discovered until the 32nd examination. Elastic tissue is found in a frequency proportionate to the care with which it is looked for. There is no other condition - except perhaps gangrene - in which we see such

large fragments of lung tissue. One difficulty is there may be neither cough nor sputum. even as late as the eighth week: these are generally cases with marked toxemia. When one is on the look-out for the disease, and with somewhat bitter memories of mistakes in diagnosis, one may be led astray by the previous history or by the presence of tubercle bacilli in the sputum, and diagnose as caseous pneumonia for the ordinary croupous form. This happened in the following cases. the first of which is interesting as showing the small focus from which many tubercle bacilli would come.

Over 15a & 15b

II Seven patients of the series were admitted with the diagnosis of typhoid fever, based on the general appearance, the early delirium, and the high fever. When, as was the case in Baltimore, typhoid fever is very prevalent and many cases admitted with pulmonary complications, the mistake is a very natural one, but very soon the pulmonary features dominate the scene, and in all of our cases the condition was recognised, which was not always the case with general miliary tuberculosis.

III In a third group the tuberculous character of the disease is at once suggested either by the pronounced family history, the onset with haemoptosis, which occurred in four cases of the series, the presence of tuberculous glands, or of thickened pleura, ~~and~~ Lastly, the caseous pneumonia may be a terminal infection unsuspected and recognised only post mortem. This was the case with a coloured man, aged 22, who had been under observation for more than two years with bilateral spastic rigidity. At the Pm there was internal hydrocephalus with hydromyelia and extensive caseation of one lung and part of the other.

From the standpoint of physical signs there are no cases so instructive. All the features of ordinary pneumonia may be present. Pseudo-cavernous signs are common. The process of cavitation may be followed

mass. On section the centre of this was softened, forming a small cavity, which communicated directly with ~~the~~ a bronchus.

(1) Peracute . death in 1-2 weeks
(2) acute death — 10 days & 12 weeks
(3) chronic
(3) Types of Pneumonia

DIAGNOSIS.

19

15.b

18

15.a

DIAGNOSIS.

A man aged 45, was admitted to the Johns Hopkins Hospital with ~~an~~ acute left sided pleurisy on June 18th, between which ~~time~~ date and the 26th August he was tapped six times. ~~In four,~~ On four occasions the fluid was slightly blood-tinged. He lost 20 lbs. in weight. He then improved rapidly, and by the time he was discharged, on August 28th, with the exception of the usual flatness, and a slight shrinkage of the left side he was in first rate condition.

He was re-admitted on May 30th, having been acutely ill for three days, with shortness of breath, cough and fever. The sputum was muco-purulent, blood-tinged and contained tubercle bacilli. There were the old signs of thickened pleura on the left side, consolidation of the right lower lobe, which rapidly extended, and by the morning of the 5th June, the day of his death, had involved the greater part of the lung. Naturally with such a history, and with tubercle bacilli in the sputum we thought of the possibility of an acute tuberculous pneumonia, but the Post-Mortem showed:-

? I). ~~A~~ Old tuberculosis of the left pleura, with great thickening ~~of the membrane,~~ but without any involvement of the lung tissue.

2). ~~Ordinary~~ Croupous pneumonia involving the whole of the right lung except the extreme apex and a small antero-lateral margin. There was no question as to the nature of it. At the apex of this lung in the only air-containing portion was an area of caseation about 3 centimetres in diameter forming a nodular mass. On section the centre of this was softened, forming a small cavity, which communicated directly with ~~the~~ a bronchus.

(1) Peracute . death in 1-2 weeks
(2) acute death — 10 days & 12 weeks
(3) chronic

(3) Type of Pneumonia
(1) Typhoid
2 Pul.-Tub.

DIAGNOSIS.

One is sometimes led astray by the known presence of tuberculosis elsewhere. I have reported a remarkable case ("Tuberculous Peritonitis". Johns Hop. Hosp. Rep. Vol.II.) of a woman who was admitted on August 28th with tuberculous peritonitis, who was operated upon successfully. She was discharged well on December 12th. On January 8th she was re-admitted with fever, urgent dyspnoea, and signs of consolidation of the right lower lobe. We were suspicious that this might be tuberculous. On the 6th day she had a profuse fatal haemorrhage from the bowels.

The P.M. showed tuberculosis in process of healing, confined to the peritoneum only, lobar pneumonia of the right lung, syphilis of the rectum , from an ulcer of which the haemorrhage had come.

London Hospital

Museum specimen No. 1690.F.

as in no other cases; as the consolidation advances, tymparitic resonance may be extraordinarily marked, and lastly, there may be no breath sounds over large areas, a condition readily explained by some of these specimens, in which even the bronchial tubes are filled with caseous plugs.

Prognosis

PROGNOSIS. There are three groups of cases:-1.The acute, causing death within the ten days or two weeks. There are on record deaths on the 6th, 8th and 10th days. My earliest case was on the 13th day.

2. A sub-acute group in which death occurs within the three months, and 3 in a few instances recovery takes place even after the condition appears to have been most desperate. In about half my series the patients were well enough to ~~take note of~~ leave the hospital. When one looks at these specimens, it is quite evident that recovery is not possible when a lung reaches the Rochfort-cheese stage, and the ~~extraordinary instances~~ cases in which a lung clears, the fever subsides, and the patient progressively improves, are instances in which the physical signs have been produced by conditions other than diffuse caseation. A most interesting report was that given by Dr. R. Manders Smyth in the Practitioner for 1901, of personal experience of recovery from galloping consumption.

London Hospital

Museum specimen No. 1690.F.

Acute caseous pneumonia. (Acute pneumonic phthisis).

Specimen presented by Dr. Potts, Medical Superintendent of the Bethnal Green Infirmary.

Case of Alfred Franklin, aged 29, a barman, died Jan.9th.,1907.

Total duration of illness about 8 weeks.

The illness began with rigors, malaise, dyspneoa and cough: three weeks later he was admitted to the Infirmary with pyrexia (100 - 104 deg.), but beyond a few crepitations at the bases of the lungs there were no physical signs of disease. Enteric was suspected but the spleen was not enlarged and there were no confirmatory signs. Later a fistula in ano developed. Towards the end signs of consolidation of the left lung were found.

P.M. There was found a small patch of tuberculosis at the apex of the right lung: there was no evidence of tuberculosis elsewhere in the body save in the lungs.

The specimen shows the left lung in a condition of caseous broncho-pneumonia from apex to base. The pleura is thickened the lymph membrane being most marked at the apex: the two lobes are adherent. At the hilum were swollen anthracotic lymph glands with caseation. On the cut surface of the lung are seen large and small irregular areasnof caseous consolidation. The small areas are best seen at the base and are trefoil shaped, and in some cases can be seen grouped round the finest terminations of the bronchioles which

stained appropriately.

Described by Dr. Turnbull in 1907.

Museum specimen No. 1020.B.

Acute caseous pneumonia. (Acute Pneumonic Phthisis).

Specimen Presented by Dr. Poffa, Medical Superintendent of the Bethnal Green Infirmary.

Case of Alfred Franklin, age 25, a painter, died Jan.28th.,1907.

Total duration of illness about 8 weeks.

The illness began with rigors, malaise, dyspnoea and cough: there were slight pleuritic pains at the inflammatory apex (lobe - lobe) but beyond a few crepitations at the base of the lower lobe the chest was not affected. Sputum was admitted to the infirmary with Pneumonia (lobe - lobe) but beyond a few crepitations at the base of the lower lobe the chest was not affected. Sputum was examined and was found a small fleck of tuberculosis bacilli. Towards the end of the first week the patient was delirious and died on the 8th day of the illness.

can be recognised by the peribronchial anthracosis. In many of the small caseous areas a black dot may be seen near the centre. The larger areas are due to coalescence of smaller polygonal areas and show lines of black pigment lying in the interlobular septa. The larger bronchi have thickened walls: between the pneumonic areas aerated lung substance is visible.

Micro. Areas of caseation show caseous bronchitis of the smaller tubes, peribronchitis and caseous pneumonia of the surrounding alveoli.

The pulmonary arteries corresponding to the bronchioles are thrombosed. Even in the larger areas it is easy to recognise that the process has started in and around the bronchioles and has spread into the neighbouring alveoli. The tissue still partly aerated shows interstitial pneumonia and an exudate of swollen mononuclear cells of epithelial type in the alveoli. In the alveoli at the periphery of a caseous area are seen masses of a substance staining with eosin and having spindle shaped nuclei which is probably fibrin beginning to organise.

Tubercle bacilli in large numbers were found in the sections stained appropriately.

Described by Dr. Turnbull in 1907.

Museum specimen No. 1230.B.

Acute caseous pneumonia. (Acute Pneumonic Phthisis).

Specimen presented by Dr. Potts, Medical Superintendent

can be recognised by the peripheral infarcts. In many of the small caseous areas a black dot can be seen near the centre. The larger areas are due to coalescence of smaller peripheral areas and were first noticed by Laennec in the interlobular septa.

Histologically the peripheral zone is composed of polymorphonuclear cells to which fibrin and red blood corpuscles are added. In the latter stages it is seen to be surrounded by a zone of fibroblasts.

The pulmonary infarcts corresponding to the pneumonic are formed by the process that starts in the pneumonic area but ends in a peripheral fibrinous exudate. Even in the larger areas it is seen to recognise that the process is a specific one.

Imported specimen in large numbers were found in the sections examined appropriately.

Described by Dr. Lundell in 1904.


23


24

1718 A Barts Hospital

267 Eng. Hatchite

37

25v

X

267 Gnp. Hospital



26v

0973 (gnp) Hosp

XI

1

27

1V

28

29

37

Fr. Tantalite
Stuttu Island

V

No 1650

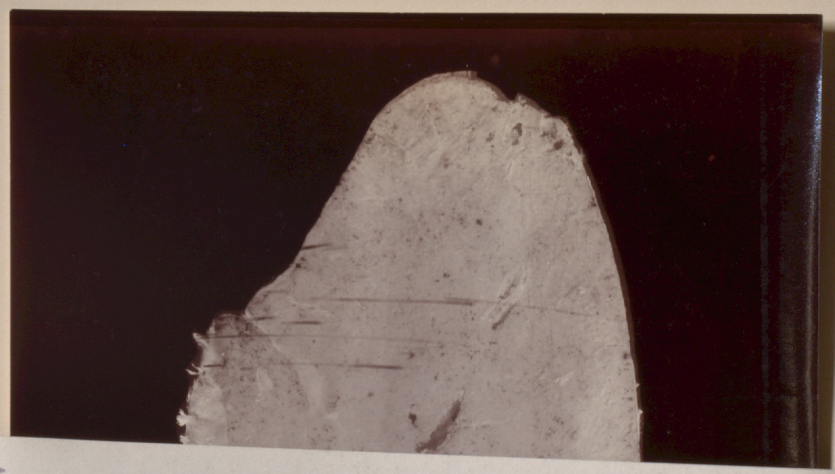

30 V

3378 R.C.S

VI

vii

31 v

29

1718 c. 1. Barts Hospital

~~26~~

viii

32 v

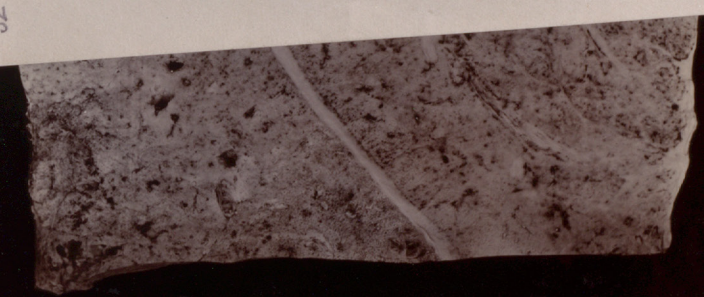

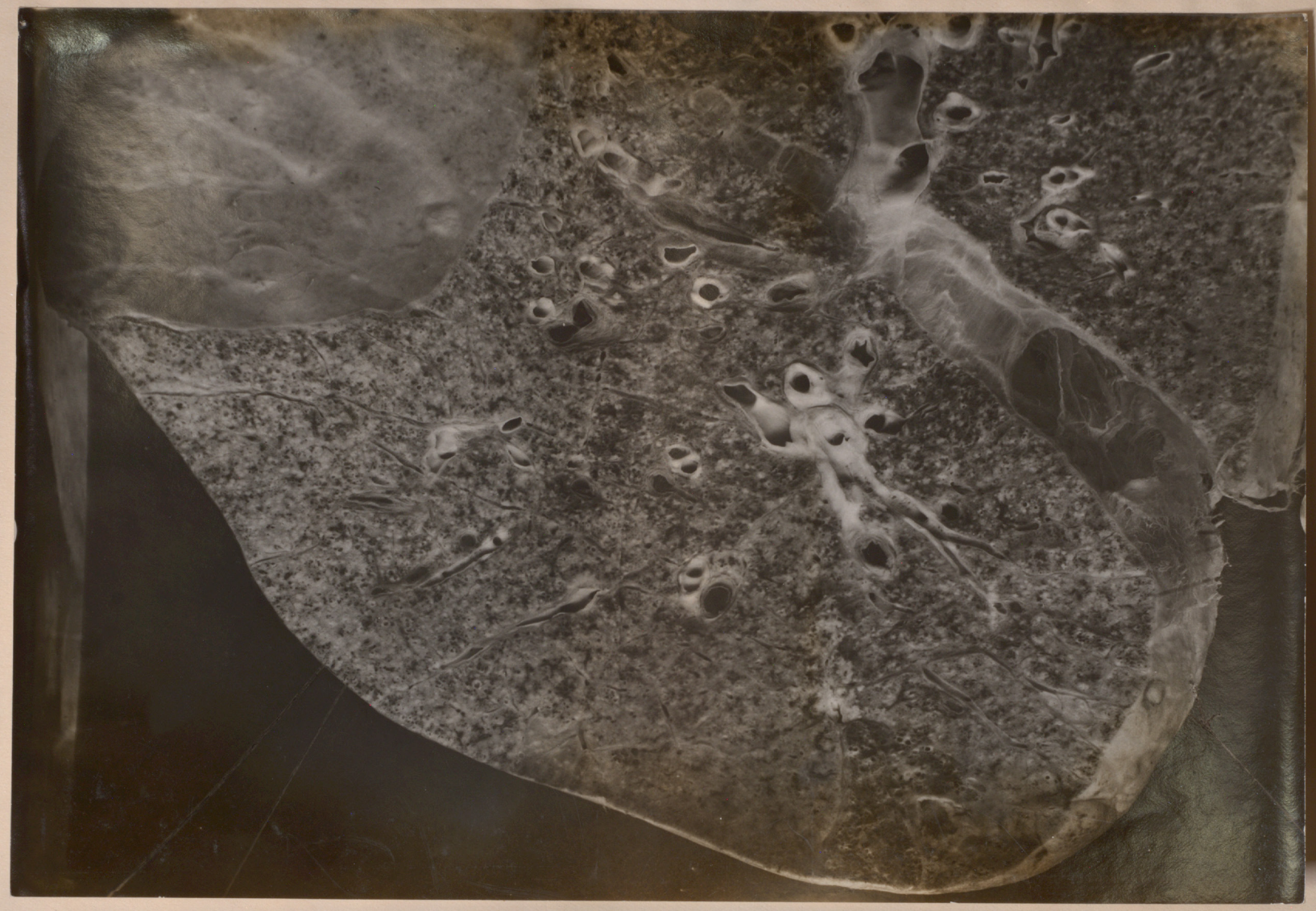


34


35



3374. R.C.S Mus

Enlarged Portion




36

[One other illustration was found with this paper, namely, Fig. 322 on p. 611 of W. G. MacCallum's Textbook of Pathology, Phila & Lond. 1914 W. B. Saunders Company. The page had been neatly cut out of the book. It was sent to Dr. S. Graham Ross to be reinserted as Lady Osler had given Dr. Ross the book after Sir William Osler's death — one of the books not catalogued for the Bibliotheca Osleriana.]

[One other illustration was found with this paper, namely, Fig. 322 on p. 611 of W. G. MacCallum's Textbook of Pathology, Phila & Lond. 1916 W. B. Saunders Company. The page had been neatly cut out of the book. It was sent to Dr. S. Graham Ross to be reinserted as Lady Osler had given Dr. Ross the book after Sir William Osler's death — one of [illegible] Osleriana.]

38 (ult.)