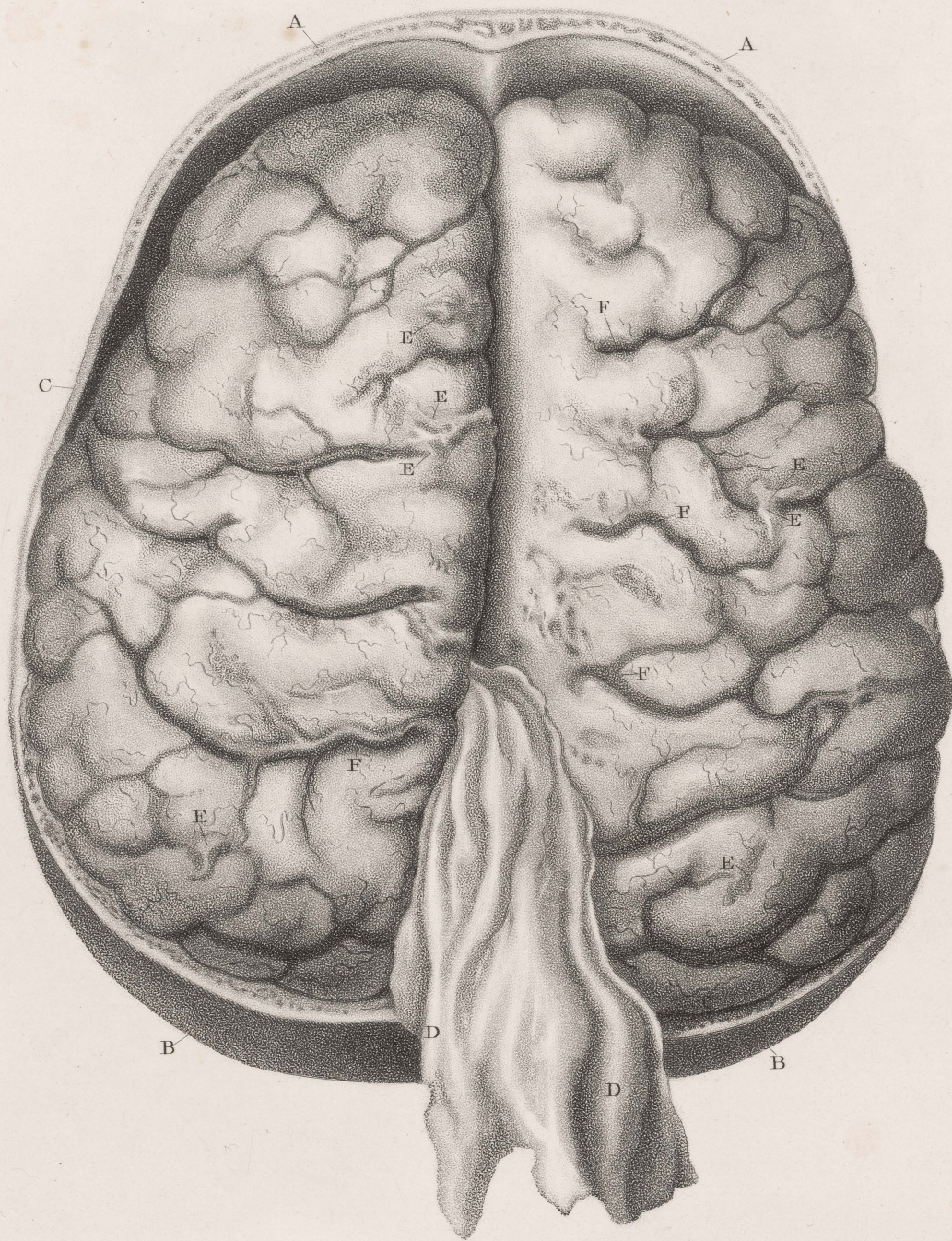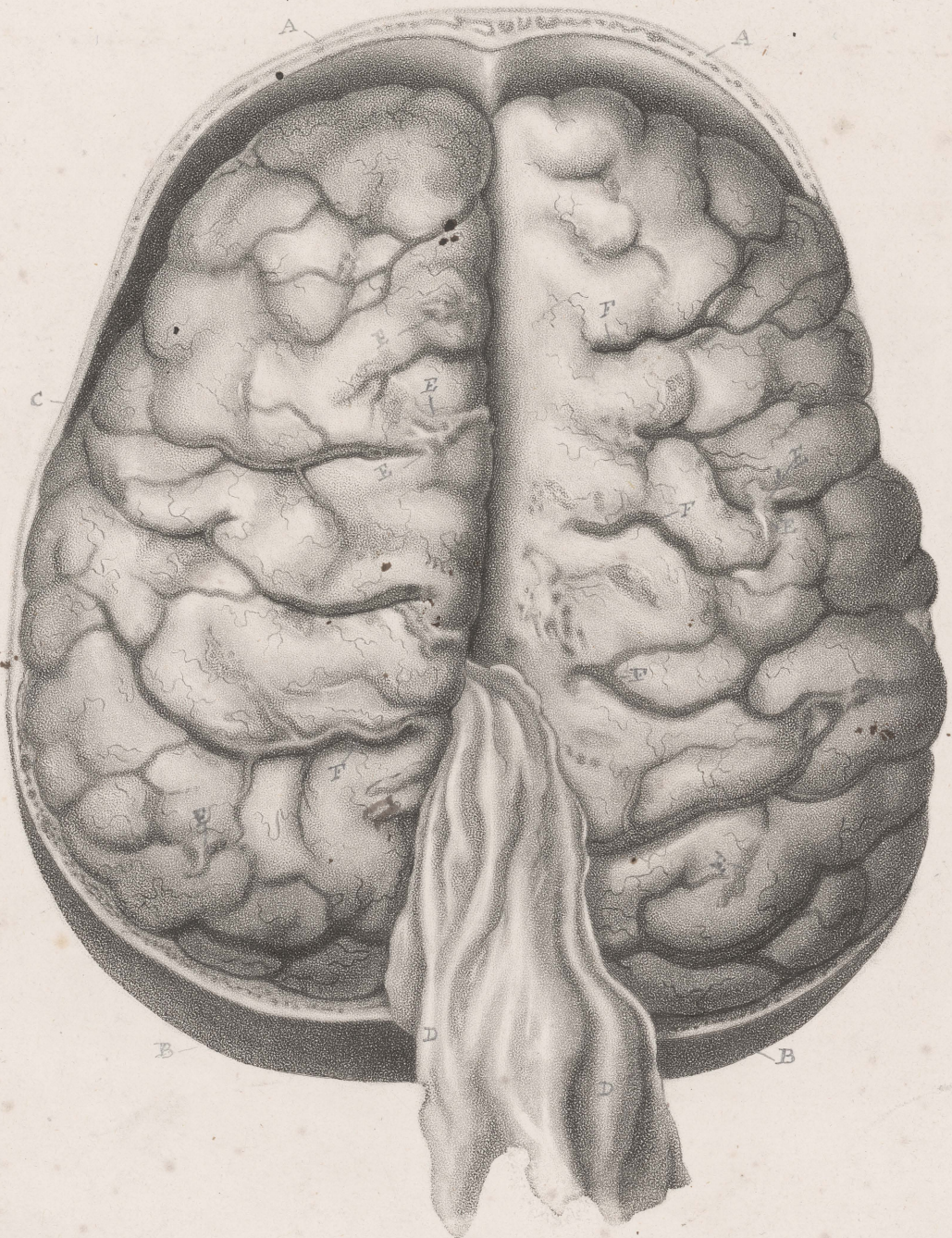


J. Howship, del.

J. Wedgewood, sculp.

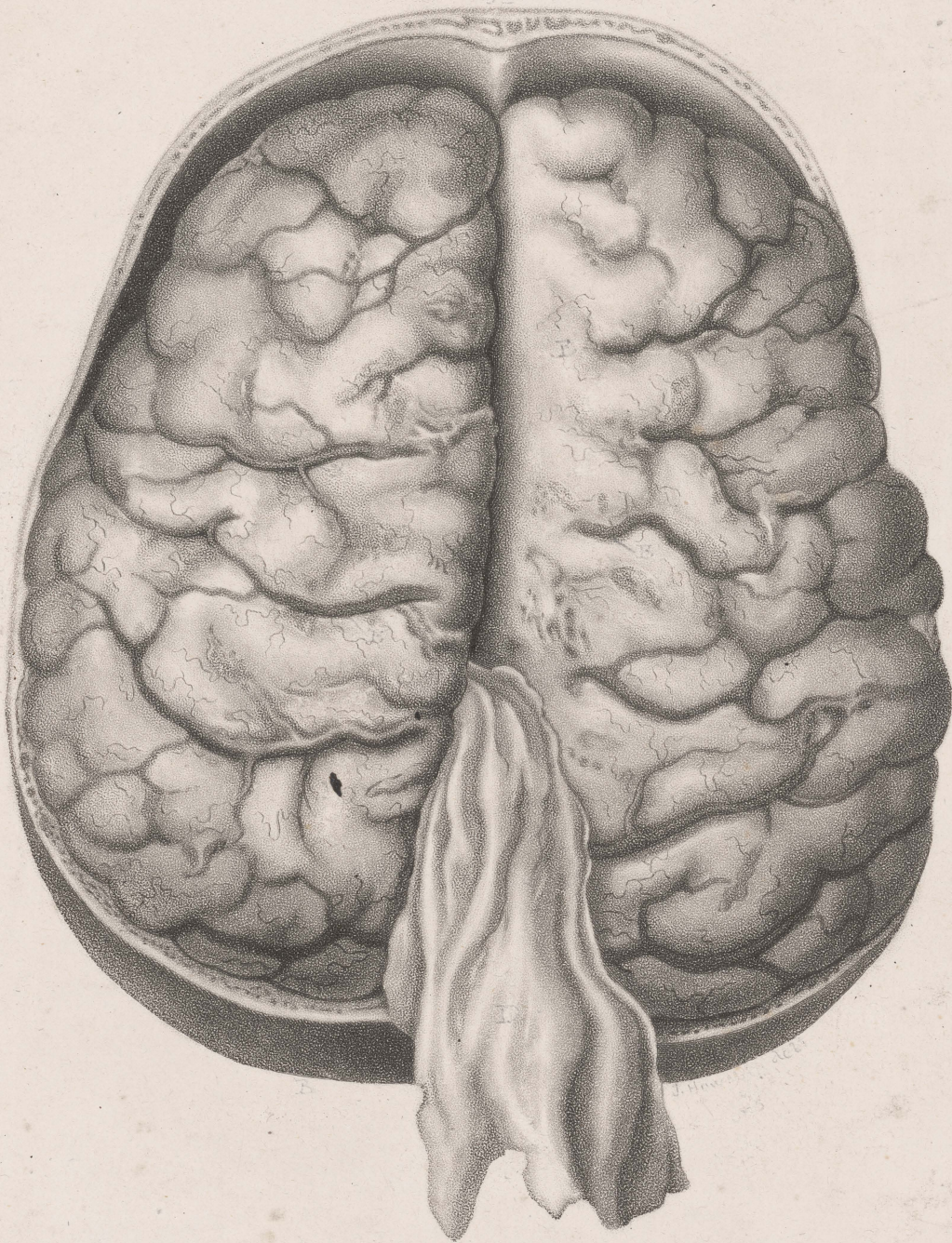
INFLAMMATION OF THE PIA MATER
and
TUNICA ARACHNOIDES.



J. Howship del^t

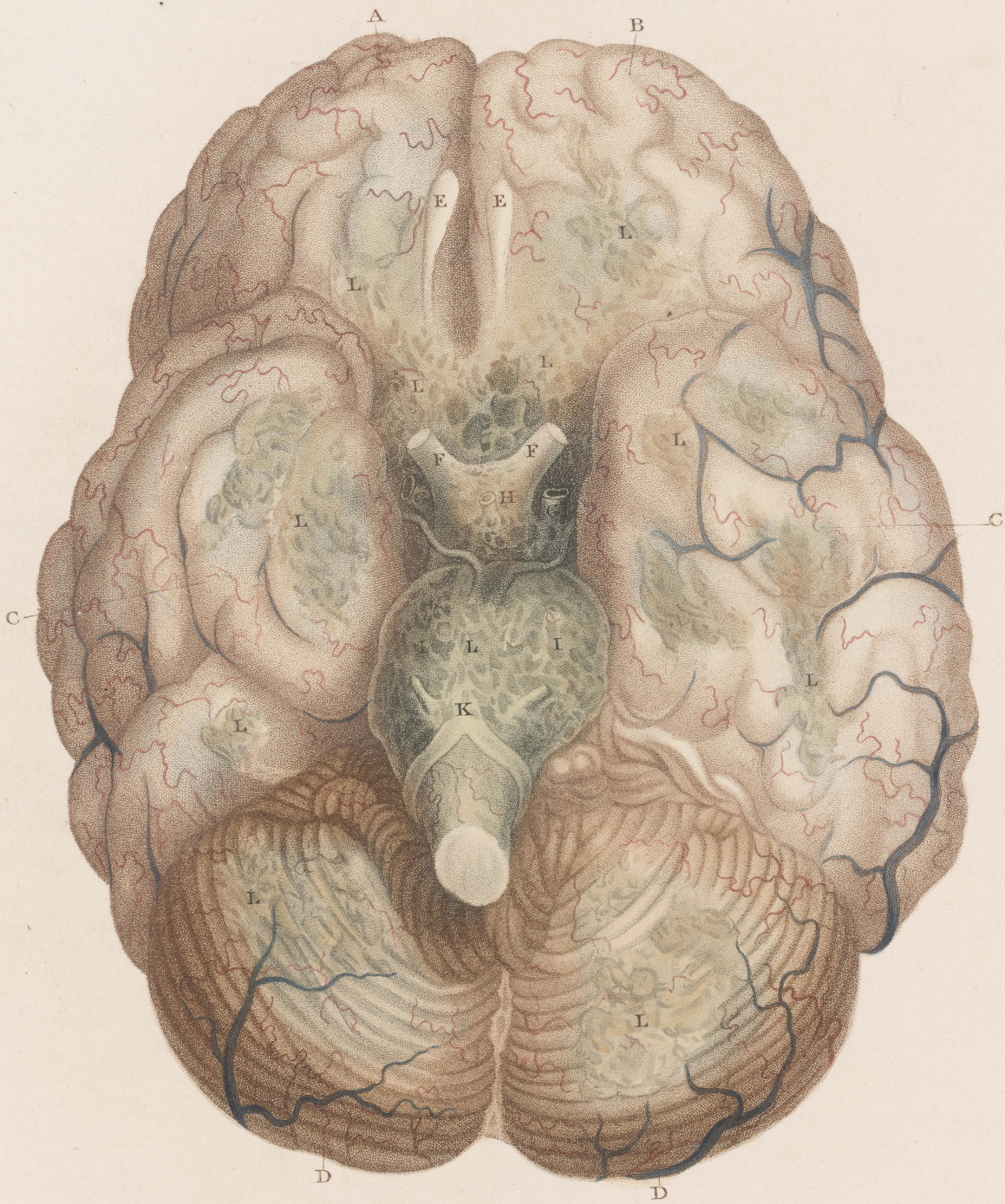J. Wedgewood sculp^t

INFLAMMATION OF THE PIA MATER
and
TUNICA ARACHNOIDES.



INFLAMMATION OF THE BRAIN
SECTION OF THE BRAIN
TUNICA DURA MATER.

PLATE IV.



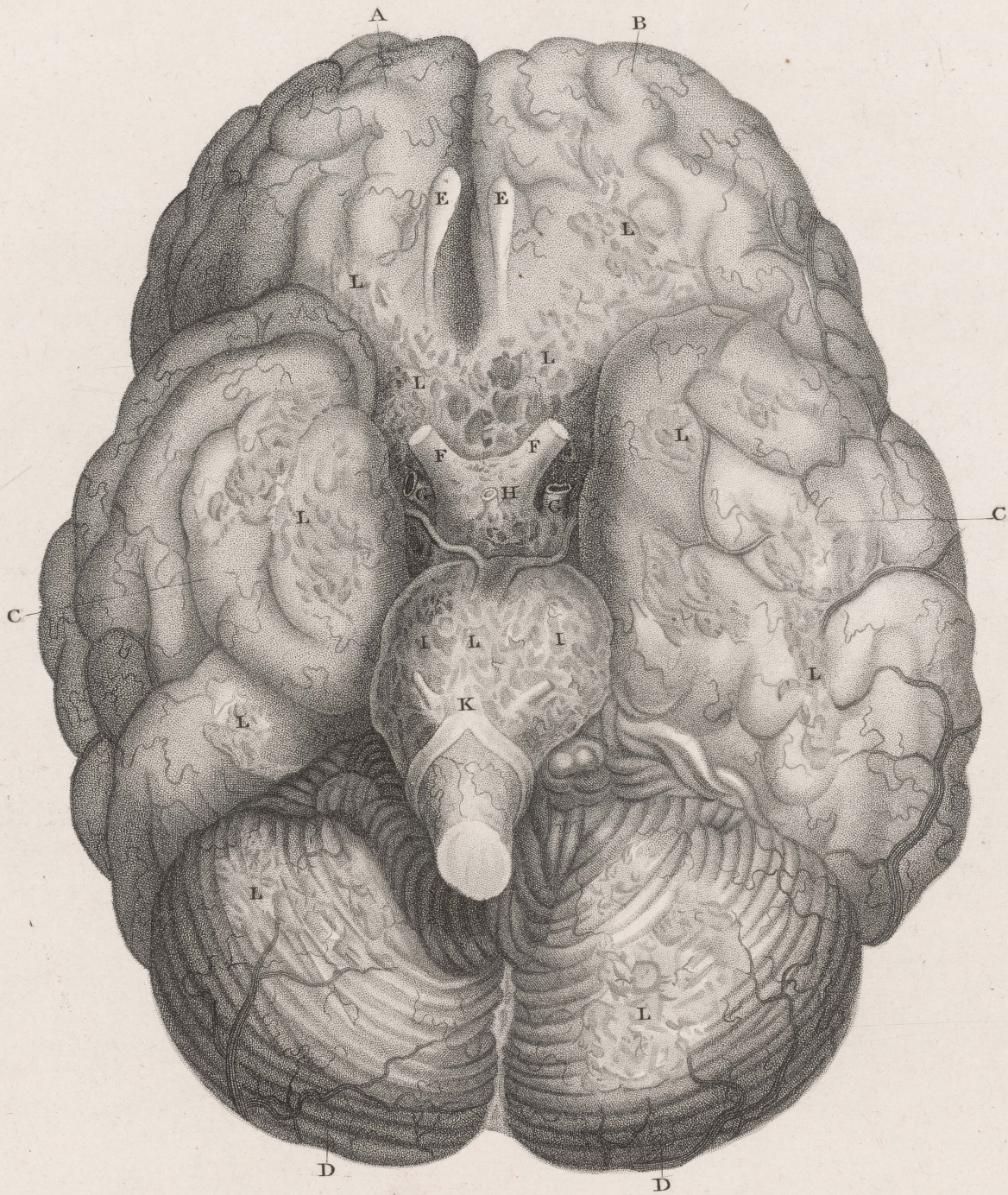
J. Howship del^t

J. Wedgwood sculp^t

INFLAMMATION OF THE PIA MATER
and
TUNICA ARACHNOIDES.

Published by D^r. Hooper, Jan^r. 1826.

PLATE IV.

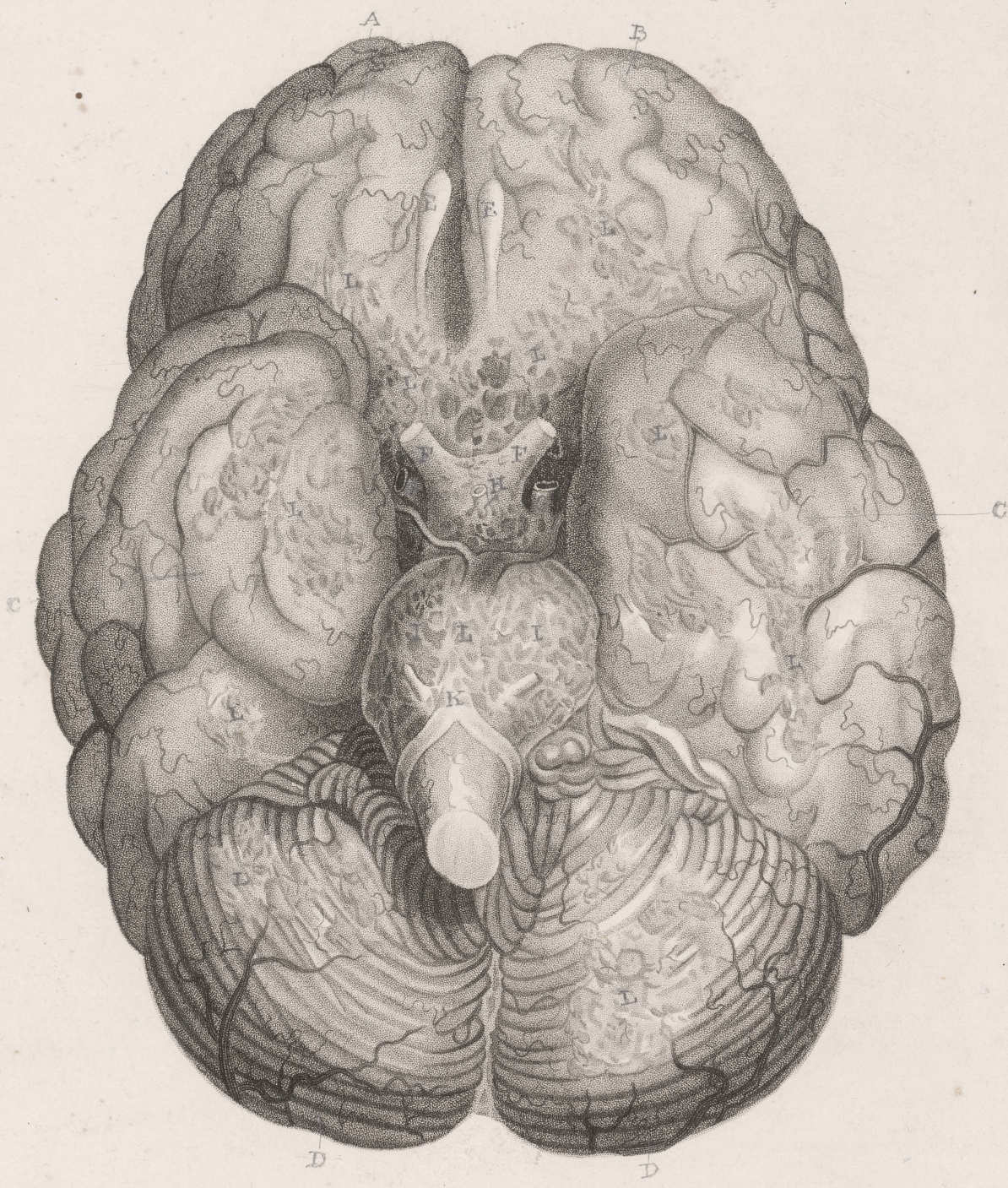

J. Howship del^s

J. Wedgwood sculp^s

INFLAMMATION OF THE PIA MATER
and
TUNICA ARACHNOIDES.

PLATE IV.

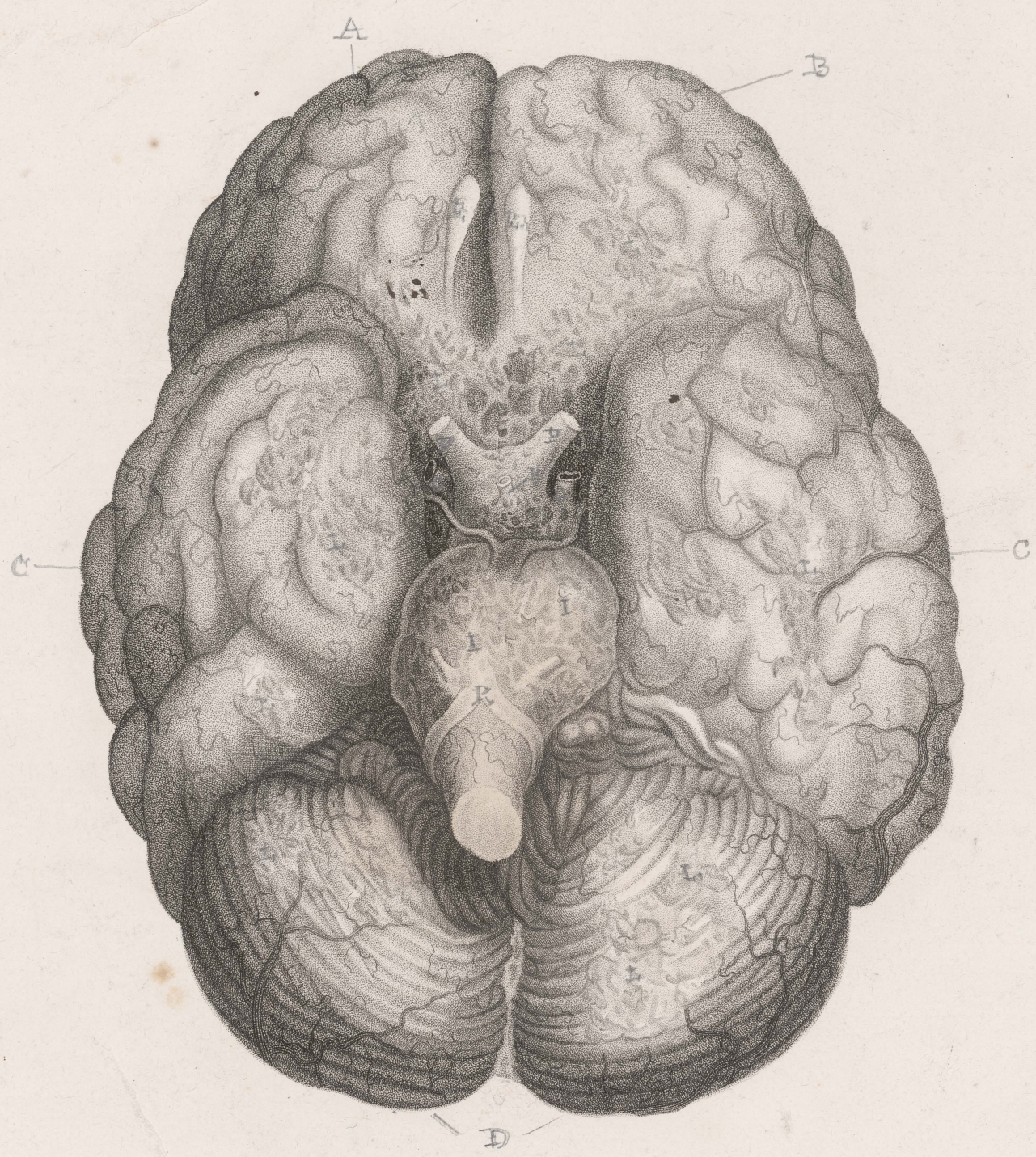

J. Horskup delt

J. Wedgwood sculp

Inflammation of the Pia mater
and
Tunica Arachnoidea.

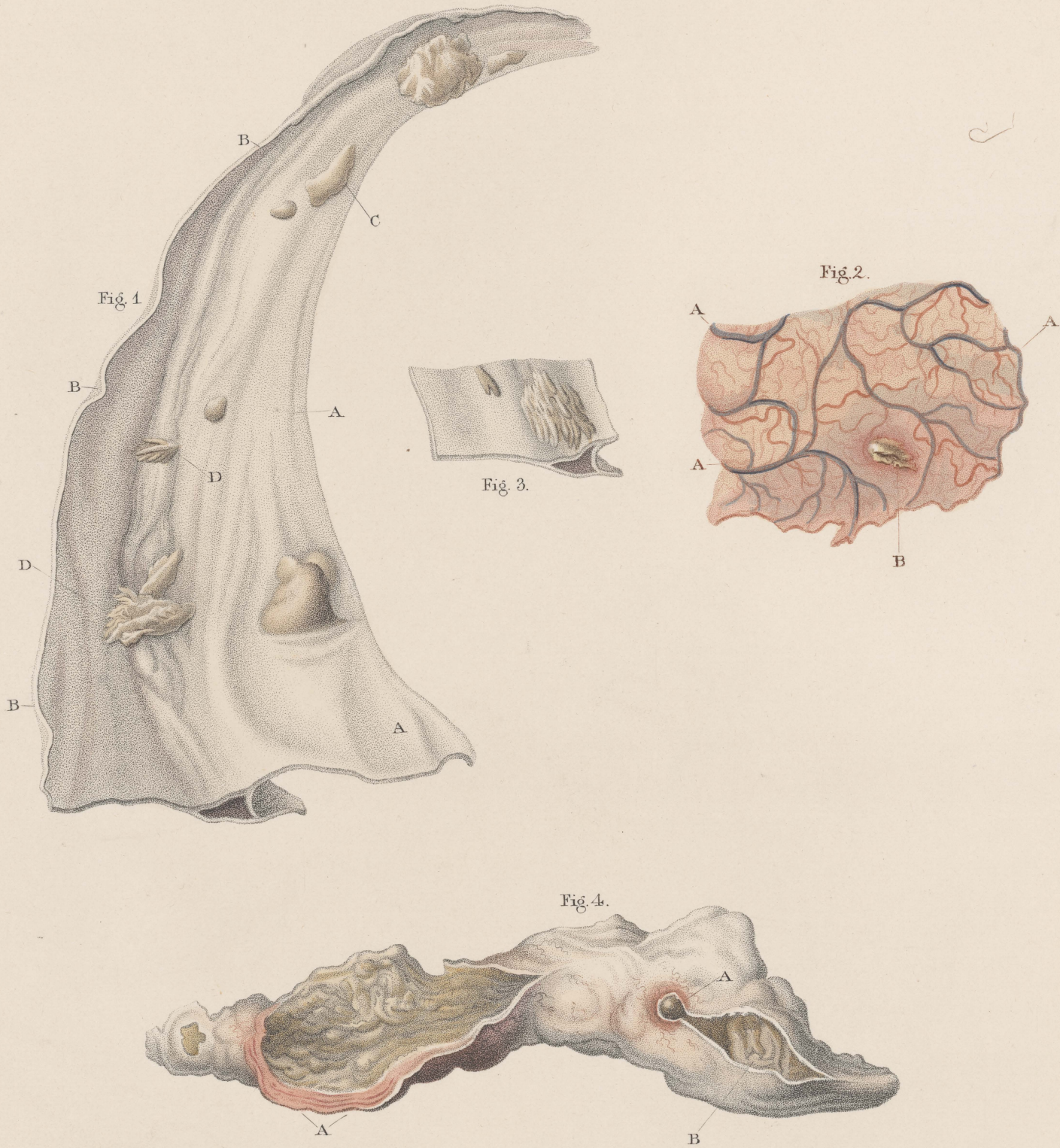
TV



Inflammation of the Pia mater
and
Tunica arachnoides

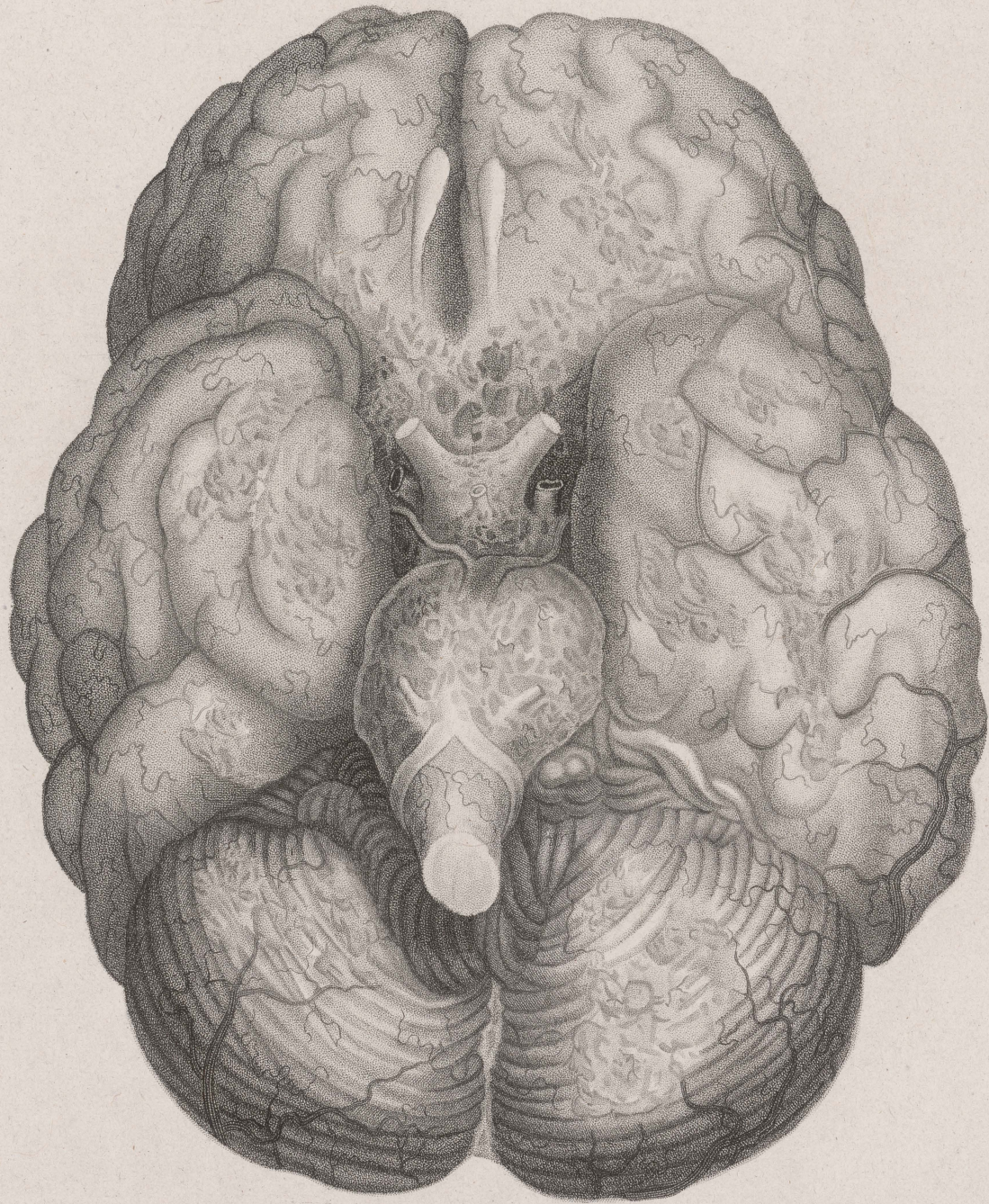

PLATE V.

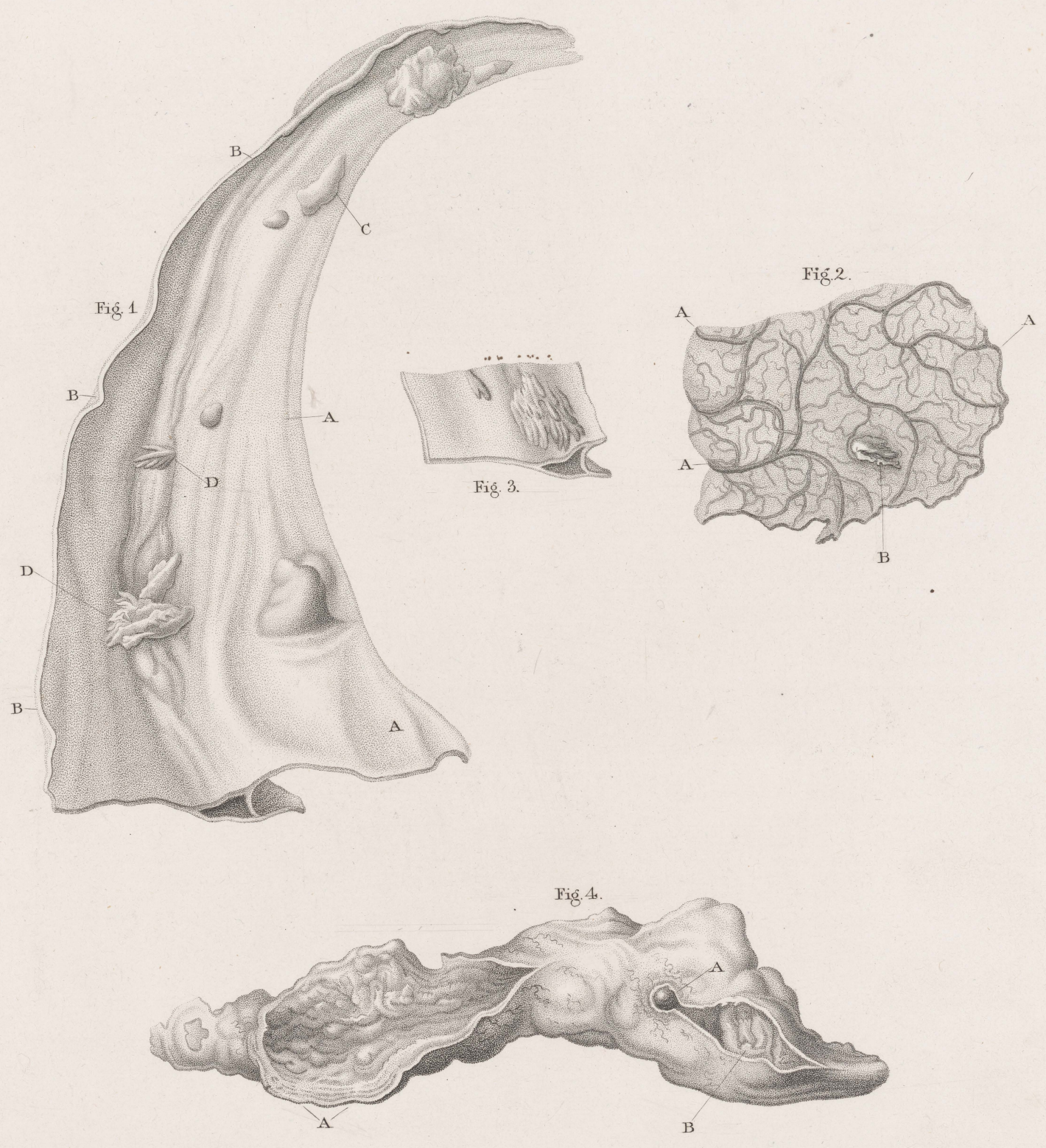


J. Howship del.

J. Wedgwood sculp.

OSSIFICATION OF THE DURA AND PIA MATER
and
ABSCESS OF THE LATERAL SINUSES.

PLATE V.

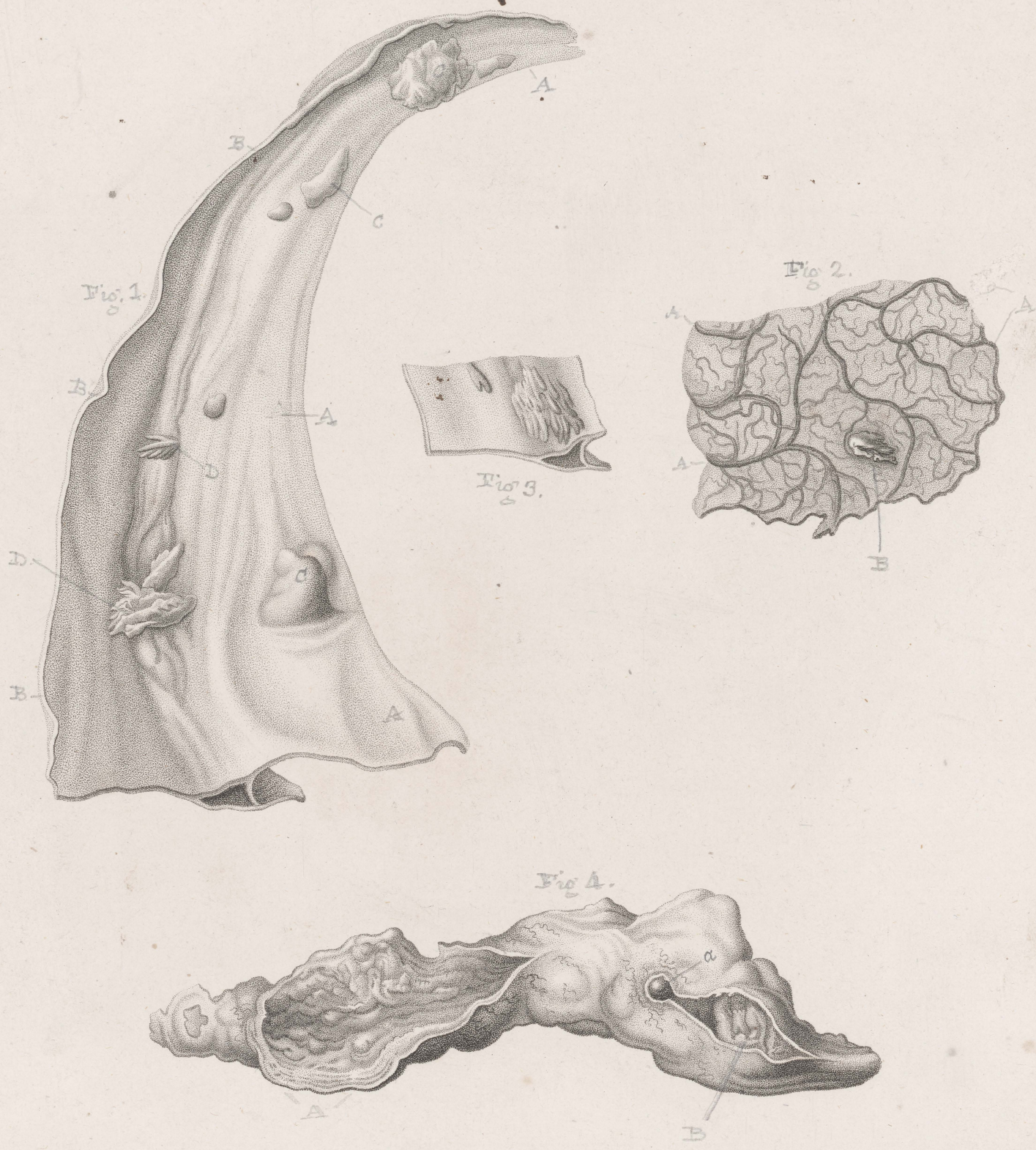

J. Howship del.

J. Wedgwood sculpt.

OSSIFICATION OF THE DURA AND PIA MATER
 and
ABSCESS OF THE LATERAL SINUSES.

PLATE V.

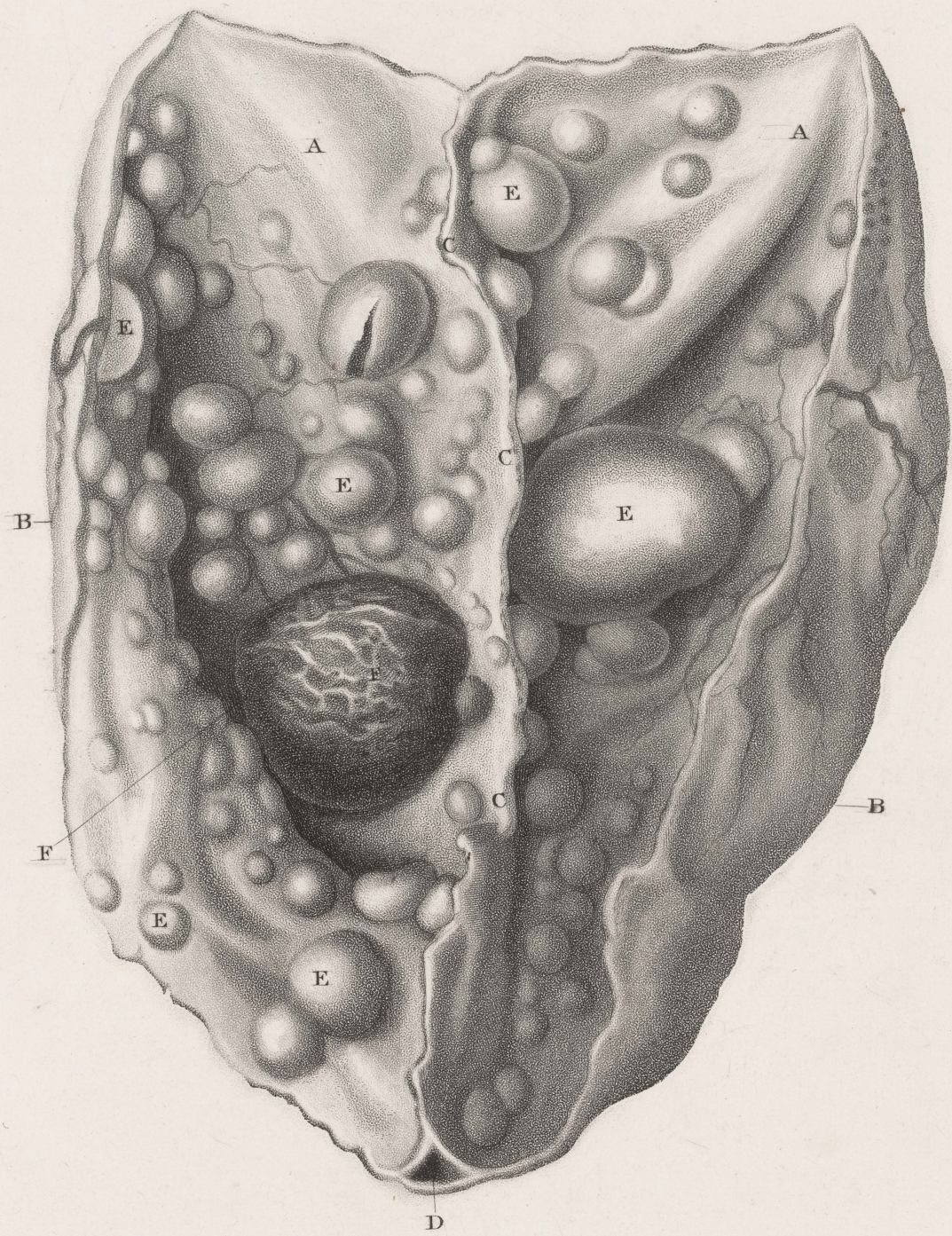

J. Hawship del^t

J. Wedgewood sculp^t

OSSIFICATION OF THE DURA AND PIA MATER.
and
ABSCESS OF THE LATERAL SINUSES.

PLATE VI.



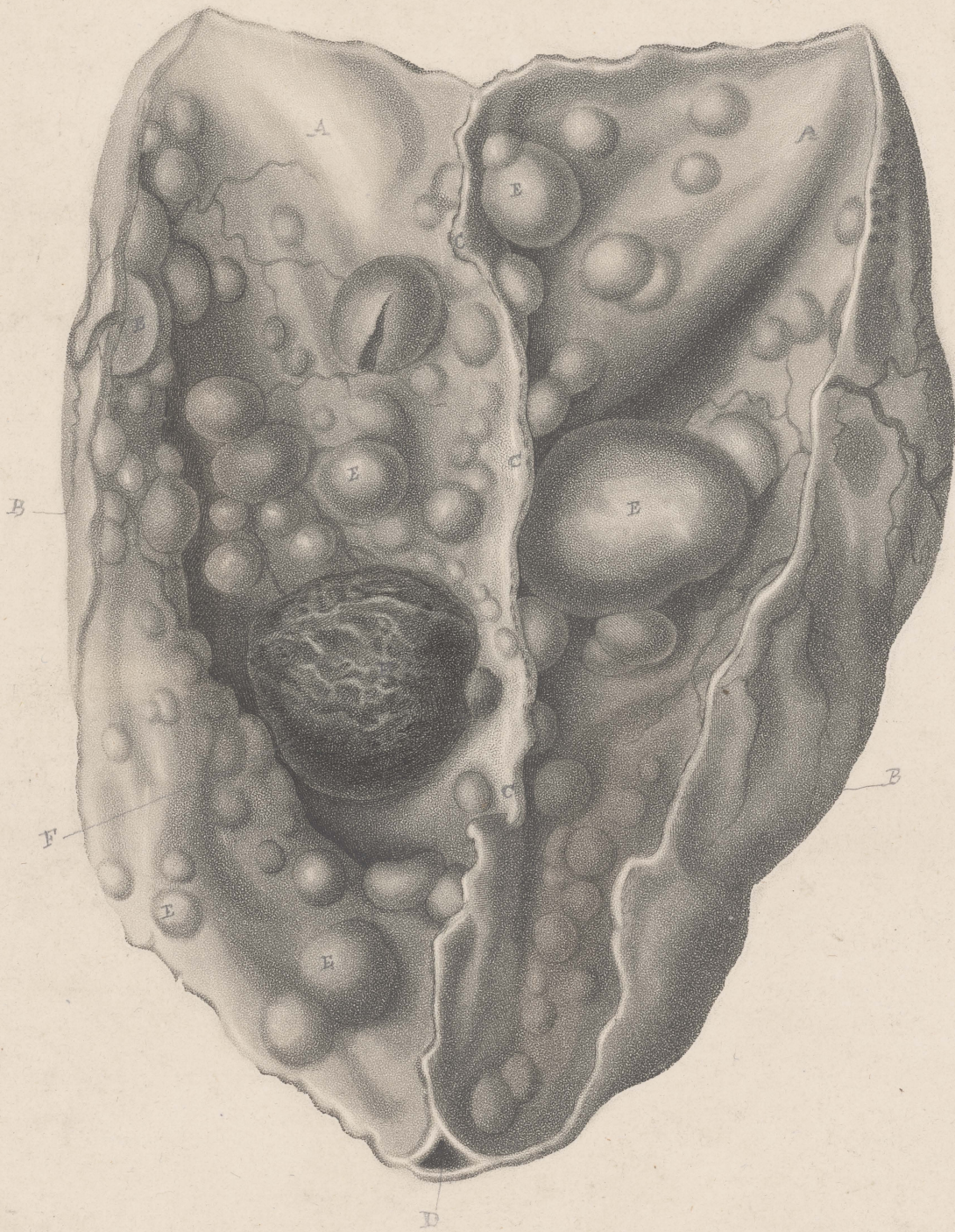G. Kirdland del^t

J. Wedgwood sculp^t

TUBERCLES OF THE DURA MATER.

PLATE VI.

PLATE VI.



G. Kirilana del.

J. Medjewood sculp^t

TUBERCLES OF THE DURA MATER.

△

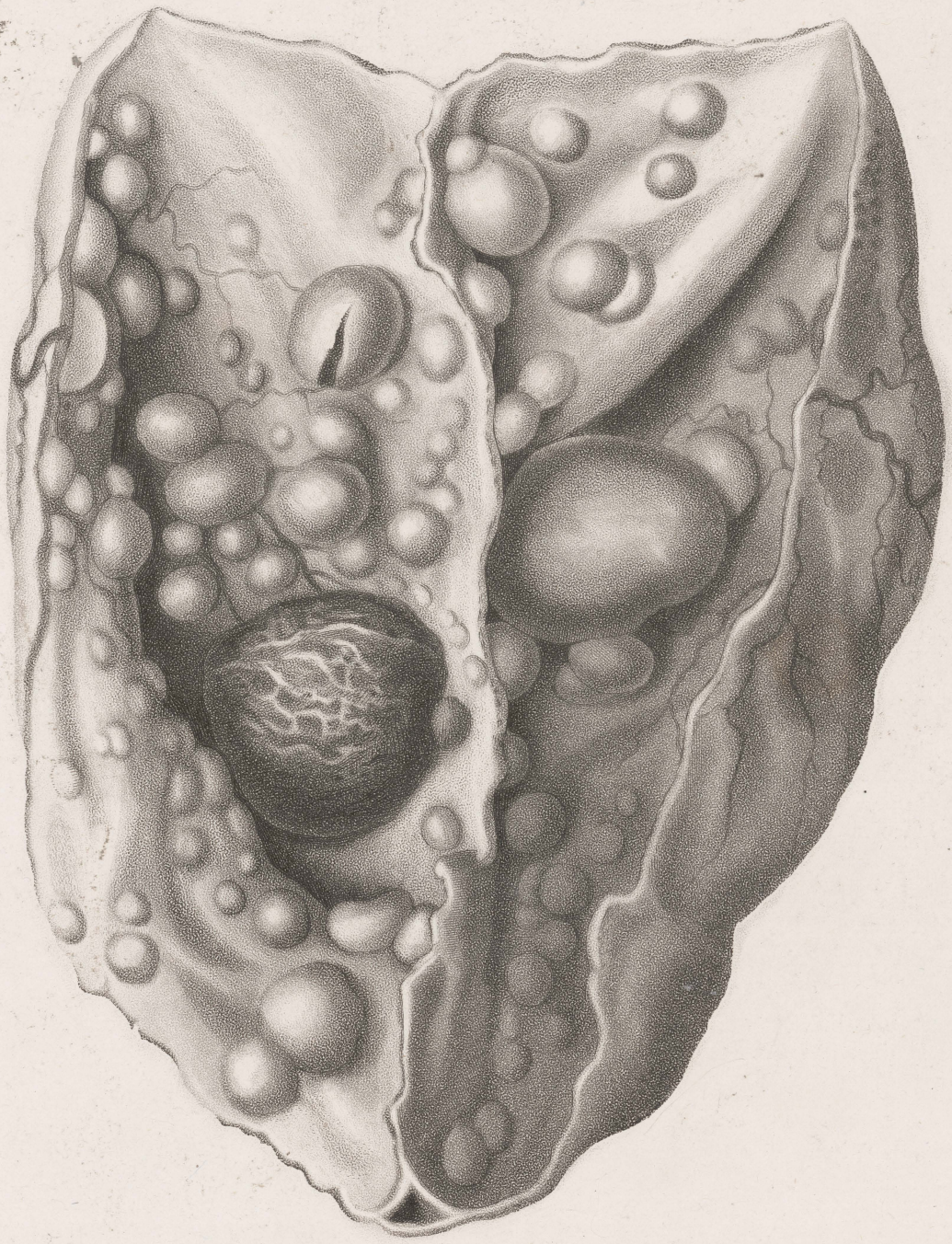
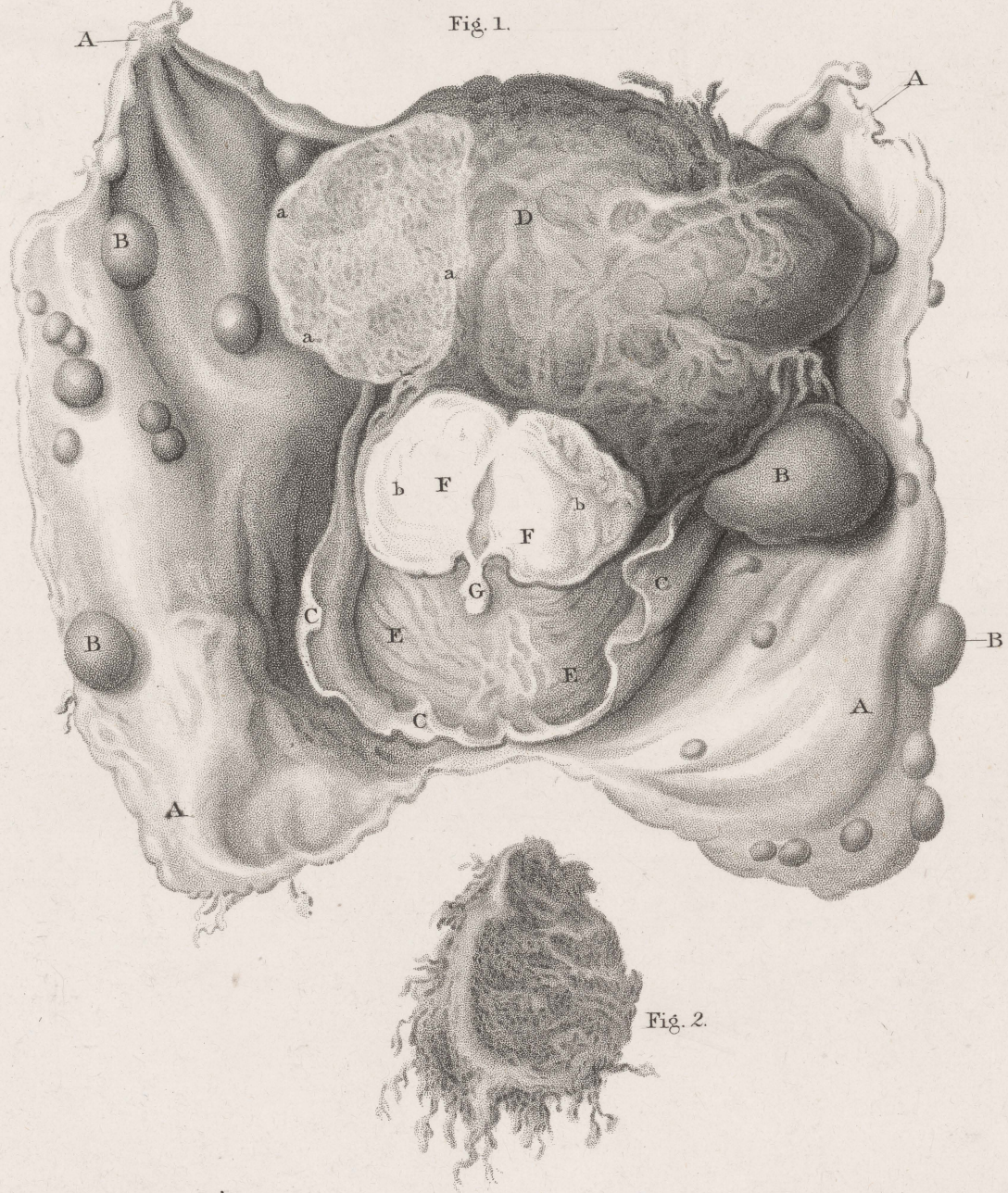

PLATE VII.

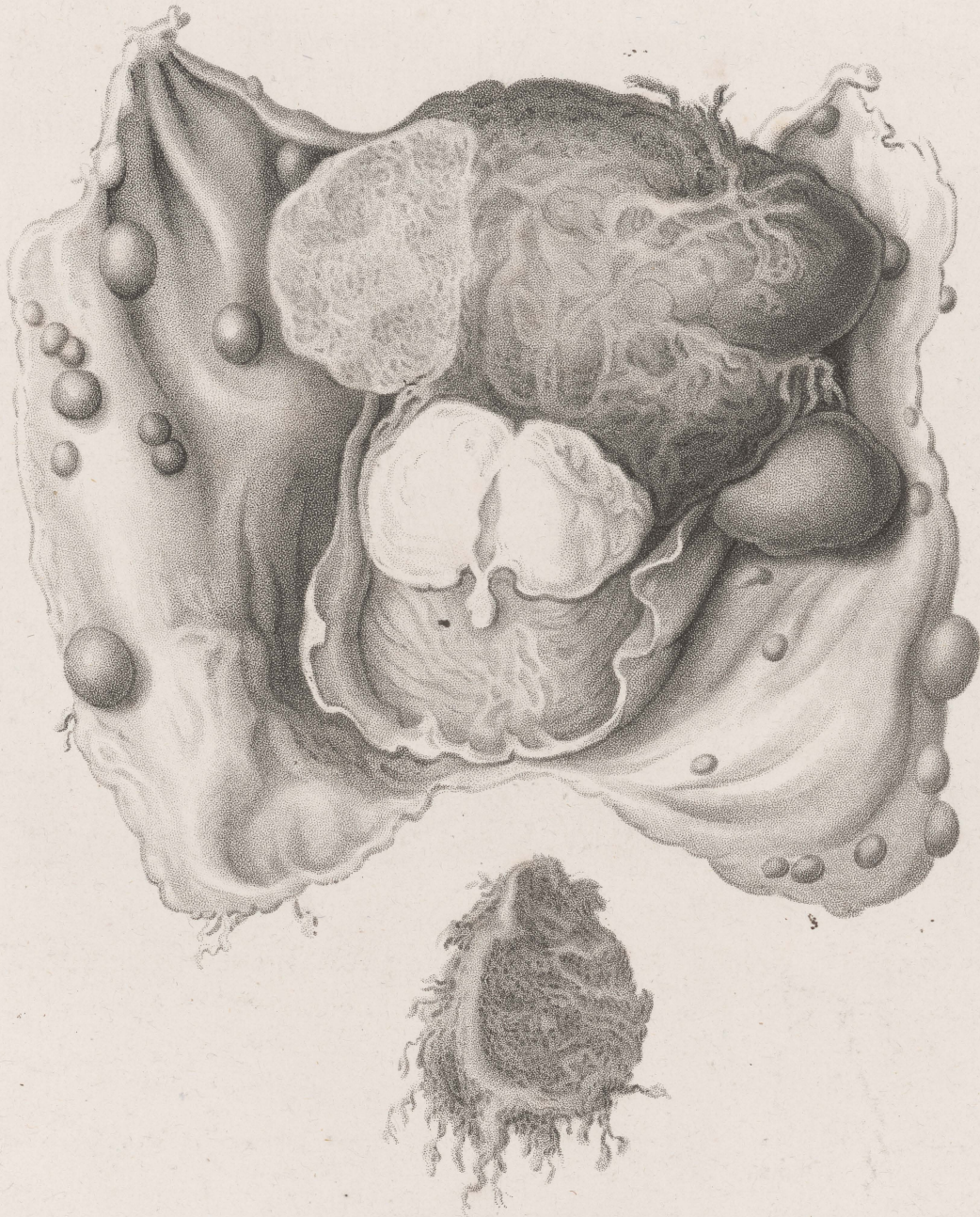

G.Kirtland. del^t

J.Wedgewood. sculpt

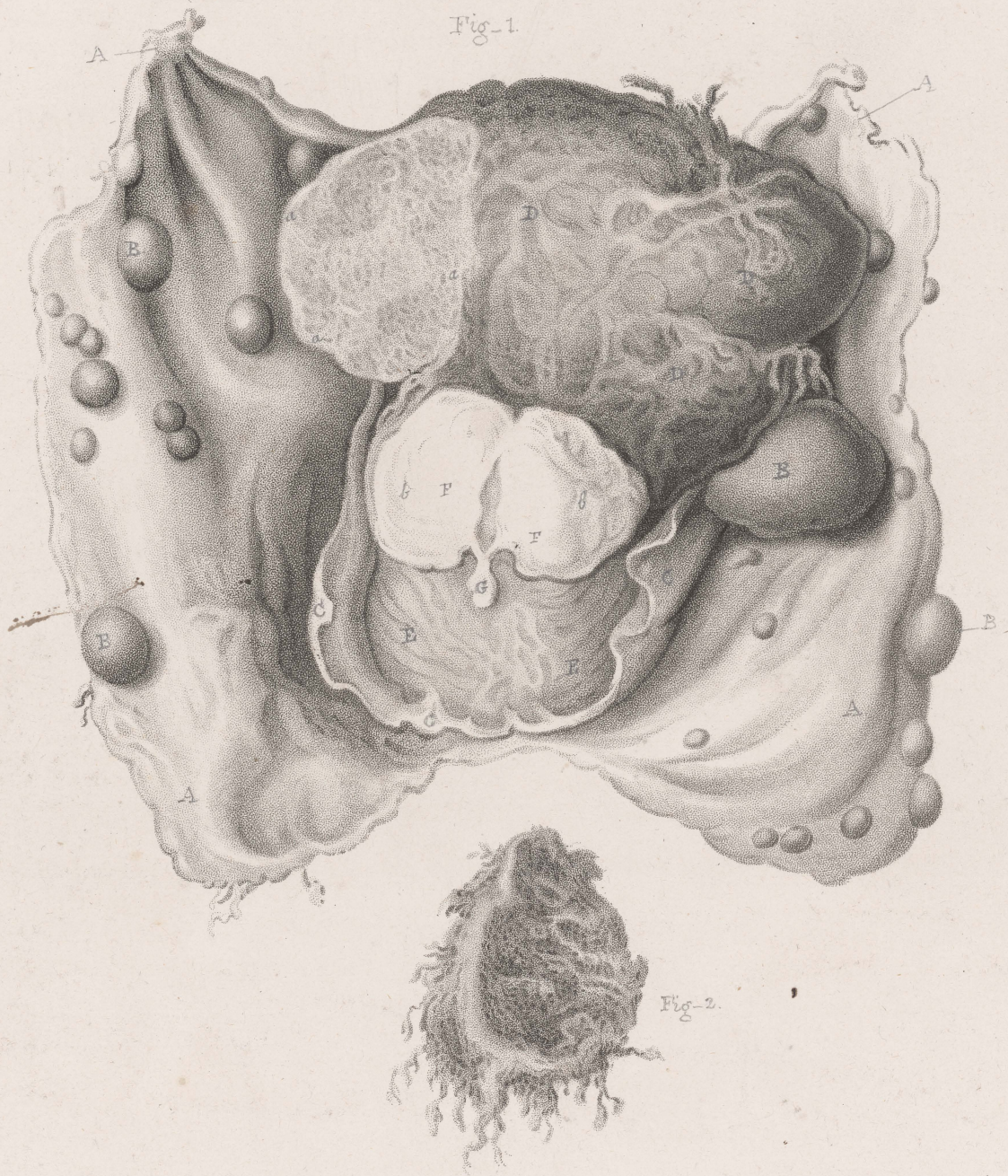FUNGOID TUMOUR OF THE DURA MATER.

VII



EXCRESCENCE OF THE DURA MATER.

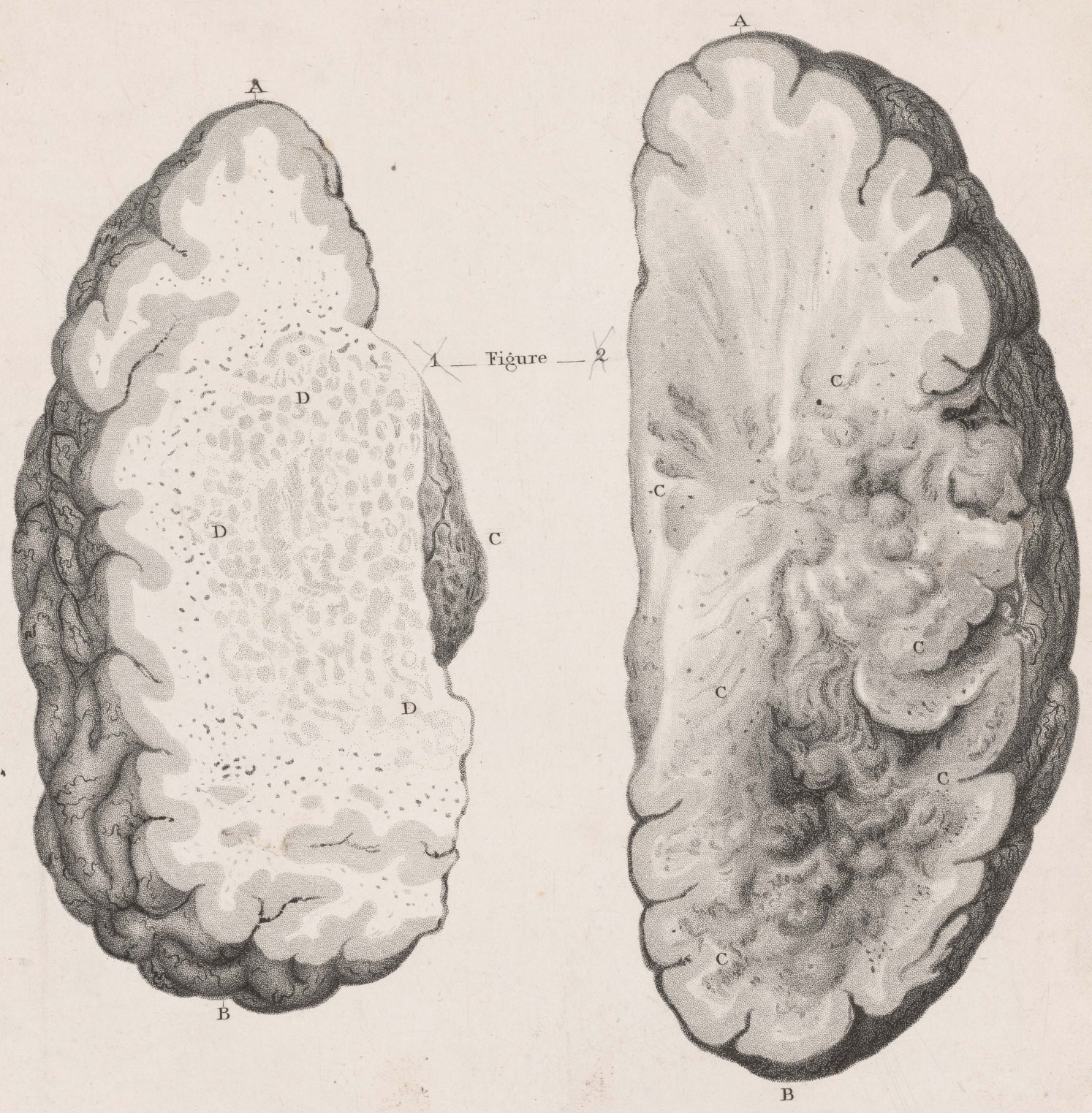Plate 7.



G. Kirlland del^t

FUNGOID TUMOURS OF THE DURA MATER.

PLATE VIII.

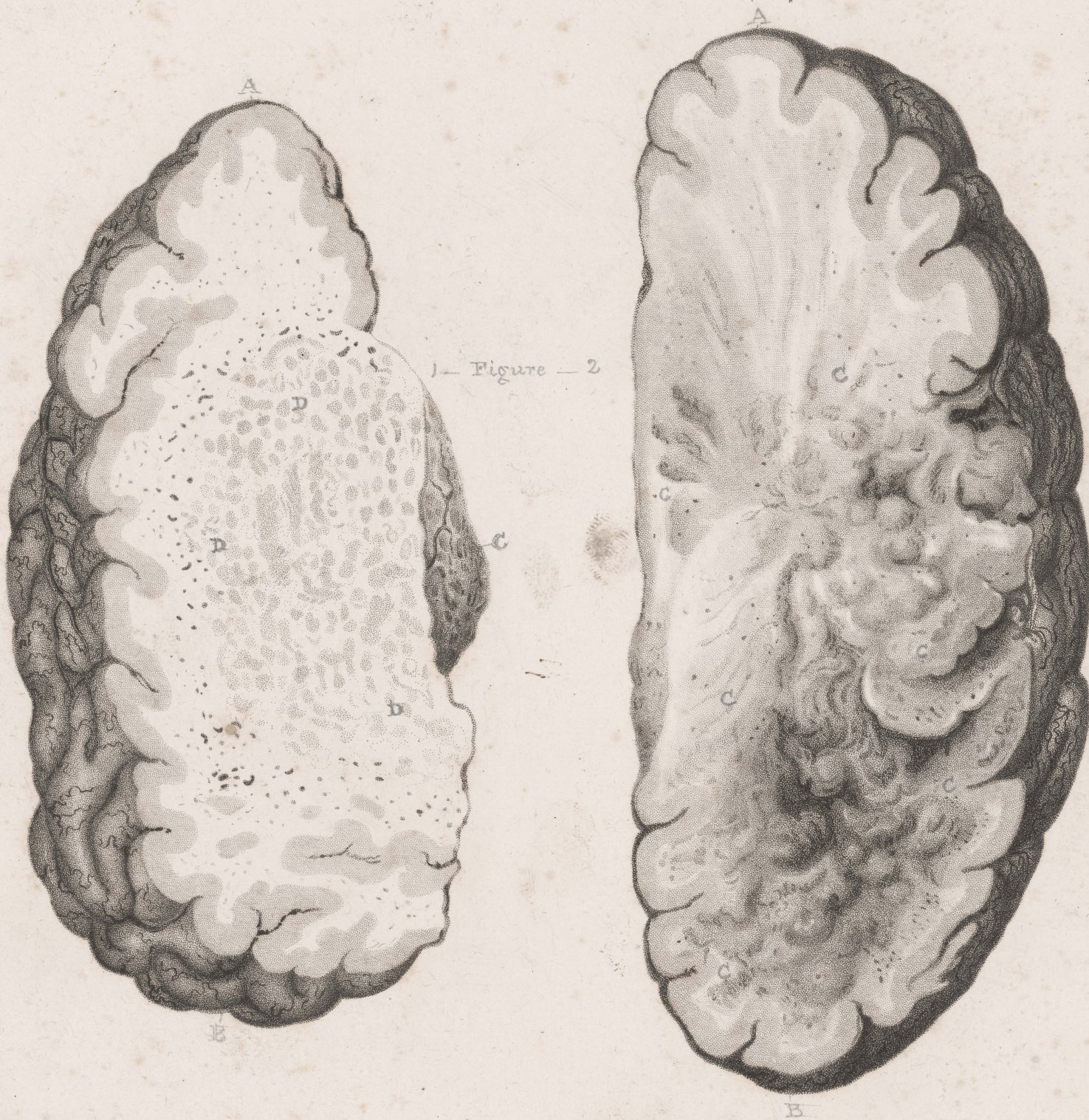

C. Kirland del^t

J. Wedgwood. sculp^t

DISEASED APPEARANCES SUBSEQUENT
TO INFLAMMATION.

Plate D.



1— Figure — 2

G. Kirtland del^t

DISEASED APPEARANCES SUBSEQUENT
TO INFLAMMATION.

VIII

