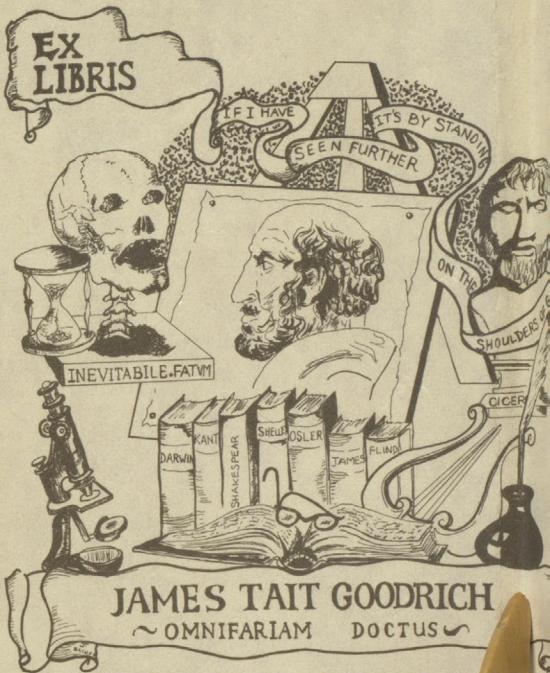


DLRS Klin

Sole Edition
13 coloured plates





PATHOLOGICAL ANATOMY
OF THE
BRAIN, SPINAL CORD, AND THEIR
MEMBRANES.

THEOLOGICAL LIBRARY

THEOLOGICAL LIBRARY

THEOLOGICAL LIBRARY

PATHOLOGICAL
ANATOMY

OF THE

Brain, Spinal Cord, and their Membranes;

BEING

A CONDENSED DESCRIPTION

OF THE

MORBID APPEARANCES GENERALLY MET WITH AFTER DEATH:

WITH CASES.

Illustrated by 13 coloured Plates.

BY W. P. COCKS, SURGEON.

LONDON :

PUBLISHED BY S. HIGHLEY,
174, FLEET STREET, AND WEBB STREET, ST. THOMAS'S
HOSPITAL.

1831.

1d/

H. S.
Feb. 24, 1892

HARJETTE AND SAVILL, PRINTERS,
107, ST. MARTIN'S LANE, CHARING CROSS.

P R E F A C E.

THERE are already so many excellent works on Pathology and Morbid Anatomy, that some apology seems due for the obtrusion of the present volume, and if the author could have found a work answering all the purposes it is presumed to answer, he would have bestowed his labours on some other subject. The scope of the Pocket Companion is, however, too limited to justify any

pretensions to rivalry with the talented productions which have so honourably distinguished the present age, and its design is to illustrate and exhibit the most approved opinions on all subjects that come under notice, rather than to indulge in novelties, which have not received the sanction of the profession generally, and the test of personal experience; there are, however, some cases not noticed by others, and many original drawings from diseased parts in the author's possession.

A comprehensive inquiry into the subject treated of must not be expected in so small a work as this: the author has desired to keep it within a certain bulk, and his language will be found, on many occasions, more concise than elegant.

The motive which led to this undertaking, was the great expense of coloured drawings on subjects essentially necessary for the student, and it is hoped that these plates, coloured after nature, may be refreshing to the memory even of the more ad-

vanced inquirer. It frequently happens, that the best written descriptions fall short of that power to identify which the pencil conveys, and with this feeling, the author, in the prosecution of his pathological researches, has made it his practice, for years past, not only to take written notes of all his post mortem examinations, but sketches also of every change in structure that has appeared at all remarkable or unusual. In this twofold character, he solicits the indulgence of the profession: he is aware

that his claims to consideration, as an artist, are too slight to merit any praise, except it be for that fidelity which he has always preferred to elaborate finishing, and in this respect, he almost doubts the possibility of finding a non-medical artist, who possesses the power to seize those points in a morbid specimen, to the nice portraiture of which the sketch owes all its value in the eye of the discriminating anatomist.

London, 1831.

The following is a list of the
names of the persons who
were present at the meeting
held at the residence of
Mr. J. W. [unclear] on
the 1st day of [unclear] 18[unclear].

[The remainder of the text is illegible due to fading.]

CONTENTS.

	PAGE
Arachnoid membrane	11
inflammation	38
Morbid Anatomy	39
of the spinal cord	125
Morbid Anatomy	126
Case	127
of the spinal cord ossified	135
Brain to prepare for dissection	6
healthy appearance	14
fœtus	<i>ib.</i>
infant	<i>ib.</i>
child	<i>ib.</i>
adult	<i>ib.</i>
method of examining	<i>ib.</i>
ventricles	16
corpus callosum	<i>ib.</i>
fornix	<i>ib.</i>
corpora striata	<i>ib.</i>
optic thalami	<i>ib.</i>
pons varolii	<i>ib.</i>
analysis	17

	PAGE
Brain, fluid on its surface	17
nerves	19
inflammation	59
Morbid Anatomy	60
abscesses	62
Morbid Anatomy	<i>ib.</i>
Case	64
ulceration	<i>ib.</i>
Morbid Anatomy	65
Case	<i>ib.</i>
softening	66
Morbid Anatomy	67
Case	70
ditto	<i>ib.</i>
induration	<i>ib.</i>
Morbid Anatomy	72
tumours	74
Morbid Anatomy	<i>ib.</i>
scrofulous	75
Case	77
flesh-like	78
Case	79
adipose	80
Case	81
scirrhus	<i>ib.</i>
Case	82
encysted	83
encephaloid	84
fungus melanodes	85

	PAGE
Brain, melanosis	86
analysis	87
bone	88
Case	89
cavities	90
Case	91
blood cyst	92
Case	93
hydatids	94
Case	97
ditto	<i>ib.</i>
fluid in the ventricles	98
analysis	100
Morbid Anatomy of hydroce- phalus	<i>ib.</i>
Case	103
ditto	104
apoplexy	106
meningeal	<i>ib.</i>
cerebral	<i>ib.</i>
Morbid Anatomy	108
Case	111
arteries ossified	113
Case	115
change of colour	116
hypertrophy	118
Case	<i>ib.</i>
Cholera morbus	42
Cranium	6

	PAGE
Cranium, method of sawing	7
dura mater, adhesion to	8
fracture	28
Cases of insanity	146
Death from arsenic	48
sulphuric acid	<i>ib.</i>
sulphurated hydrogen	49
carbonic acid	<i>ib.</i>
Prussic acid	51
by hanging	50
drowning	<i>ib.</i>
strangulation	<i>ib.</i>
Delirium tremens	41
Dementia	71
Dura mater	8
inflammation	30
Morbid Anatomy	31
Case	32
ditto	43
adhesions	33
softening	<i>ib.</i>
ulceration	34
scrofulous tumours adhering to	<i>ib.</i>
thickened	<i>ib.</i>
cartilaginous, analysis of	35
fungoid tumours adhering to	36
ossified	37

	PAGE
Dura mater, analysis	37
Case	38
Explanation of the plates	146
Erysipelas	47
Form for facilitating the record of post mortem appearances	21
Ganglionic nerves	140
Gangrene	3
Hydrophobia	44
Hydatids	136
Hydatids, Case	136
Insanity	71
Idiotism	72
Mania	71
Monomania	<i>ib.</i>
Nerves within the cranium	121
inflammation	122
injuries	123
heal when wounded	124
ganglionic	140
Pia mater	12
distinction between inflam- mation and congestion	12
inflammation	38
Morbid Anatomy	43
veins inflammation	47
Morbid Anatomy	48
Case	54
air in the veins	56

	PAGE
Pia mater, serofulous tumours	57
water on the surface of the	
brain	<i>ib.</i>
cysts adhering to	58
ossified	59
Plexus choroides	128
Pineal gland	120
Pituitary gland	121
Pericranium	23
Phthisis pulmonalis	51
Putrefaction	4
Spinal column, method of opening	21
canal, an effusion in	131
Case	<i>ib.</i>
apoplexy	132
Spine fracture	138
Spina bifida	132
Morbid Anatomy	133
Typhus fever	41
Wounds before and after death	2

MORBID ANATOMY,

&c.

THE following will be found the most convenient method of examining the external parts of the head and contents of the cranium.

On viewing the head and face, particular attention is to be paid to the integuments and the various appearances they present, such as inflammation, spots, œdema, wounds, or sphacelus.

Spots.—When the discolouration is the consequence of external violence, a conges-

tion of thick concrete blood will be found; but in the spontaneous spots or suggillation, the blood, on incision, will be seen fluid.

Wounds.—Wounds received before death are marked by red bloody and separated edges. Those inflicted afterwards are livid, and their edges close to each other. Similar appearances characterize contusions or blows, in which there has been no solution of continuity; and on dissection they are, if inflicted on the living, found to be subcutaneous wounds; vessels are seen torn, and fluids extravasated, and the whole exhibits the marks of tumour in its elasticity and circumscribed shape. Violence on the dead body can only produce livid flaccid spots, unattended with infiltration or tumour.

Sphacelus.—Gangrene also is surrounded with a red edge: putrefaction is not; and the spots, caused by the latter, are of various colours. Dry gangrene cannot take place on the dead body, since there is no heat or action of vessels to produce it, but the disorganization observed is of a humid nature.

There are circumstances, however, which invalidate the importance of this sign, and render it somewhat doubtful. Thus, for example, a man may die of a wound, before inflammation commences. Others are so debilitated, that wounds on them have livid and dry edges, and, after death, can scarcely be distinguished from those inflicted on the dead.

Putrefaction commences gradually when

the vital principle is extinguished, and after a certain period, which however differs in different bodies, according to the previous diseases, the season of the year, its temperature, &c., it produces an extensive disorganization, confounding the cause of death, and rendering it dangerous for any one to examine the body.

Taking these facts into consideration, it will be found useful to attend to the following statement of the progress of putrefaction, and the comparative utility of dissection in each :

First stage.—A tendency to putrefaction. It consists in a slight alteration of the body, a softness of the flesh, and a disagreeable odour. Dissection is practicable, and still useful

Second stage.—Commencing putrefaction. A fœtid odour is present, the fleshy parts become light, and assume a dark colour. Dissection is already dangerous, and can be of no use except in particular cases.

Third stage.—Advanced putrefaction. The parts exhale an ammoniacal odour, mixed with a putrid smell. They fall into dissolution, and their colour is constantly altering. Dissection is impracticable and useless.

Fourth stage.—Complete putrefaction. This is known by the complete dissipation of the ammoniacal odour, and also by the putrid smell losing its strength. The volume and weight of the parts are much diminished, and they separate into a gelatinous mucus, which

gradually dries, and at last becomes an earthy and friable mass.

To prepare for the dissection of the brain, an incision is to be carried from ear to ear through the scalp.

The skin is then dissected off the cranium,* and drawn over the face and occi-

* *Cranium*.—When the bones of the cranium are laid bare, search is to be made if there be no fissures or fractures, taking care at the same time not to mistake irregular sutures for them; and for this purpose, they should be rubbed over with ink.

Caries and all other diseases of the bones, with the state of the pericranium, are to be carefully noted in the report. The brain is sometimes pressed upon by bony tumours growing from the cranium. A general increase of the thickness of the bones of the skull encroaches upon the brain, and sub-

put. In cutting through the skull some nicety is required. On the anterior part the cut should not be made lower than half an inch above the frontal sinuses, but it may be carried to a lower level behind. Before the saw is applied, a piece of whip-cord may be tied firmly round the skull as a mark for the circular incision. The saw should not be carried through all the tables of the skull; but after having cut through the external

jects it to all the effects of continued pressure. A nodule of ossific matter, resembling ivory in hardness and appearance, has been found growing from the cranium. Bony ridges and spiculæ of bone occasionally grow from the cranium and its processes.

and middle tables, we should endeavour to break the vitreous table with the chisel and mallet.

In some cases, the dura mater adheres so firmly to the parietal bones, that it is impossible to raise the scull-cap without using great force, or the scalpel. After the roof of the skull is removed, the chin must be supported on a tripod or block.

The dura mater should be minutely examined, in order to ascertain whether there is any fungous production upon it, or depression in the corresponding part of the bony arch. When adhesion exists, and when the sinuses are gorged with blood, the fact should be stated in the

report. When pus or blood is effused between the membrane and bone we should ascertain its source.

The dura mater should be washed, to enable us to determine whether any change of colour has taken place, and if the discolouration be owing to a fluid effused on its surface, or produced by inflammation. The scissors may now be run along the longitudinal sinus, and the manner of the opening of the veins into it noticed, and the glandulæ Pacchioni, carefully examined. (I imagine that an enlarged state of these glands is frequently the cause of diseases of the head, preventing, as it does, the free

egress of the blood from the veins of the cere brum into the longitudinal sinus.)

The dura mater is now to be divided by a horizontal incision carried opposite to the ear on both sides, continuing the division forwards nearly to the perpendicular ridge of the occipital bone. The lateral parts of the dura mater may then be turned up towards the longitudinal sinus ; this will expose the surface of the brain, the falx cerebri, and the fissure between the hemispheres. The falx must be cut from the crista galli, raised out of the fissure between the hemispheres, and the dura mater turned backwards.

We now see the whole of the upper surface of the cerebrum. The removal of the dura mater should be done gently, and it will then be seen whether any adhesions exist between it and the arachnoid membrane.

If there be no effusion of serum on the surface of the brain, it will be difficult to see the arachnoid membrane, on account of its transparency; but when there is effusion, it is apparent without any difficulty, as it is a little thickened. After minutely examining the arachnoid membrane, inspect the convolutions of the hemispheres: if they are flattened in any considerable degree, it

indicates an effusion of fluid into the lateral ventricles.

It is difficult to trace the arachnoid membrane to all the parts of the brain to which it is said to go. It may, however, be easily traced over the surface passing from one convolution to another without descending between them. The ventricles are lined with this membrane, which is thickest at the base of the brain. The next membrane is the delicate, but vascular pia mater,* loaded with arteries

* *Pia Mater*.—The bright red, and especially when the redness is diffused in the interstices of the vessels, denotes inflammation; while the retarded circulation produces only turgidity of the vessels.

and veins; and when we pull a portion of it, we find it passing down into the substance of the brain, and between the convolutions. We also find it prolonged into the ventricles, assuming the name of the plexus choroides. Its inner surface is in close contact with the cerebral substance; its external with the arachnoid membrane on the surface of the convolutions, but loses all connexion with it after passing into the sulci. At its entrance into the ventricle, the plexus is drawn together, so as to resemble a small vascular bundle, and becomes invested by the arachnoid membrane, which, by its reflection from the sides

of the ventricles to the plexus, maintains the integrity of the cavity.

*The hemispheres being uncovered

* *Hemispheres.*—The brain when in a very recent state is of a purplish brown colour, and somewhat elastic; it is firm to the touch, and may be divided into thin slices without any part of it adhering to the knife, and may be stretched to a certain degree without tearing. But when it has been exposed to the air for an hour or an hour and a half, or when examined after the lapse of twenty-four or thirty hours after death, even although death has not been occasioned by disorders which affect the nervous system, the brain is soft, readily torn, and a portion of it adheres to the knife, unless the knife has been previously dipped in oil or water, and it falls to pieces on being slightly stretched. A slice of recent brain, put into water, does not render the water turbid for ten or twelve hours.

may be drawn aside, so as to expose the corpus callosum, and its substance may be cut through* by passing down

Brain of the fœtus and of the child just born, appears to consist almost entirely of a cineritious pulp, to such a degree, that the medullary substance is difficult to perceive in it. During infancy the brain is redder and much softer than during the meridian of life; and it gradually becomes harder upon the approach of old age.

* *Cut through.*—The best way is to slice the brain off by several horizontal incisions, and let any change, either of colour or consistence, be carefully examined.

The appearance of the grey substance should be noted; it may be of a slightly rosy tinge, or may present a sort of dotted redness, particularly when the pia mater is much injected; in other cases the texture of the convolutions is altered, being rendered soft or almost diffuent by inflammation and

a scalpel to a level with the corpus callosum, and then directing its edge outwards and upwards, so as to avoid entering the ventricle.* The ventricle

suppuration. It is generally stated, that the superficial cineritious substance of the brain presides over intellectual functions, and its white and deep-seated grey mass over locomotion.

* *The Ventricles.*—We should never fail to examine very carefully the state of the serous membrane which lines them, and the colour and quantity of fluid found in them.

The state of the corpus callosum, fornix, corpora striata, optic thalami, and pons varolii should be fully stated, taking care with regard to this last to indicate the side of it which is particularly affected.

The white substance in the deeper parts of the brain, as that around the ventricles and corpus striatum, is in the healthy state softer than that towards the surface.

may be opened by making an incision through the corpus callosum, pa-

M. Magendie states, that there exists round the brain and spinal marrow a liquid mass, varying in density according to the parts in which it is found, and occupying the space between the surface of these organs and their membranous coverings. He says, "I have proved, by a sufficient number of examinations, that this fluid constantly exists in man; that it is a sign of the healthy and not diseased state, as some medical men, who seeing it only or by chance have been led to believe. The quantity of this fluid, which I call cephalo-spinal, is never less in the adult than two ounces, and sometimes amounts to five in tall persons, and those whose skulls are large.

Analysis of the brain, of the cerebellum, and spinal marrow :

Water	80.00
White fatty matter	4.53

rallel with the raphe, and everting the external portion of it. The parts within the body and interior and posterior horn of the ventricle being examined, the descending horn may be traced by following the plexus choroides downwards into it, after which it can be fully exposed by making an incision through the substance of the optic thalamus down to the cornu.

Red fatty matter	0.70
Osmazome	1.12
Albumen	7.00
Phosphorus	1.50
Sulphur and salts, such as—	
Phosphate of Potass	} 5.15
Lime	
Magnesia	

If the cornua ammonis be drawn outwards, the point at which the plexus enters will distinctly appear; and also the change presented by the pia mater where it enters the ventricle.

The greater part of the substance of the hemisphere may now be removed, and the tentorium cerebelli at the same time detached from the pars petrosa, and reflected backwards.

This will expose the greater number of the cerebral nerves, with their course and relations within the cranium.

METHOD OF OPENING THE VERTEBRAL
COLUMN.

The easiest way to open the spinal canal is to cut through the roots of the spinous processes with a saw, or, what is still better, with a large knife (a plumber's hacking knife) and a mallet, and then tear up the processes with a pair of pincers.

This will expose the sheath of the spinal marrow, which is a continuation of the dura mater. The membranes and substance of the spinal marrow should then be examined, with those precautions which have been recommended in examining the brain.

A form for facilitating the record of post mortem appearances, in the order in which they present themselves. The blank spaces are to be filled up with the appearances of the parts facing which they stand.

Post Mortem examination of

	<i>Age</i>	<i>Disease</i>
<i>Date</i>	<i>By whom performed.</i>	

External appearance of the head,
face, eyes, and ears

Pericranium

Bones of the head

Dura mater

Longitudinal sinuses

Sinuses and veins	
Arachnoid membrane	
Pia mater	
Convolutions and substance of the cerebrum	
Ventricles	
Fornix	
Plexus choroides	
Corpora striata	
Thalami nervorum opticorum	
Pineal gland	
Foramina	
Commissures	
Infundibulum and pituitary gland	
Corpus olivare	

Corpus pyramidale	
Corpus restiformes	
Medulla oblongata	
—— spinalis	
Nerves	
Arteries	
Substance of the cerebellum ..	

DISEASE OF THE PERICRANIUM.

(PERIOSTITIS.)

Symptoms. — Head-ach, with various uneasy feelings about the head; painful tenderness of the scalp in some particular part, with some degree of swelling or thickening of the integuments there.

MORBID ANATOMY.

The pericranium is generally found thickened, and firmly attached to the bones of the head. In some cases it presents quite a cartilaginous texture, nearly three-quarters of an inch in thickness. When removed from the skull, the bone or bones are found to be very much destroyed by absorption, particularly the outer table and its texture resembles that of coarse sponge, but very white. In such cases, you generally find some organic derangement within the cranium.

Case.—A boy, aged fourteen years, had a small angry tumour on one side of the nose,

which extended to the forehead, with erysipelas and fever. He suddenly became comatose, then convulsed, and soon died.

Dissection.—The pericranium of the frontal bone was found red, thickened, and detached from the bone, there being much purulent matter lying between them. The dura mater was detached from a corresponding space of bone internally, and a greenish fluid was effused between them.

The following are some of the recognized alterations of structure of the brain and its membranes.

CONCUSSION OF THE BRAIN.

Symptoms.—Slight cases of concussion are marked by giddiness, dimness

of sight, weakness of the limbs, trembling, and nausea. In severe cases the person becomes insensible, face pale, skin cold, with relaxation of the limbs, low and weak breathing, feeble pulse, and the pupils fixed and insensible, stertorous breathing—death. When the effects of concussion subside the sensibility gradually returns, the pupils contract, the pulse rises, the skin becomes warmer, the patient can be roused from the comatose state as from a sleep; or sensibility returns at intervals, he awakes, answers questions, and again relapses; on reviving, there is confusion of intellect or delirium.

MORBID ANATOMY.

With respect to the state of the brain under concussion, when the injury has not been excessively severe, it seems that the symptoms are merely the effects of a disturbance of the natural course of the blood through the brain. It seldom happens that this state of the brain destroys; but when it does so, nothing is found upon examination which will account for the symptoms. It is, therefore, an alteration of function, but not a disorganization. When concussion is very violent, it is attended with lesion of the brain, which is generally attended with slight extravasation.

When fracture * of the skull has immediately preceded the patient's death, there will be coagulated blood found upon the bone and in the fissures; if the patient has survived for some time, there will be marks of inflammation, and perhaps pus, in contact with the skull; but

* *Fracture*.—A fracture may be as distinctly observed, and is as good a proof two months after death as one day; and this, notwithstanding the putrefaction that may be present.

In severe cases of concussion or fractures of the skull, where compression of the brain is apparent, the extravasated blood is generally met with in three different situations:—first, between the dura mater and pia mater; secondly, between the pia mater and brain; thirdly, within the substance of the brain.

if fracture has been produced in making the examination, the blood in the fracture will not be coagulated, nor will there be any effusion around the portions of bone. When there has been a blow received, though there be no fissures externally discernible on the skull, yet we examine whether there is a breaking in of the tabula vitrea. Although no fracture may exist, there is often an extravasation of blood under the cranium; owing to the shock and consequent separation of the dura mater.

INFLAMMATION OF THE DURA MATER.

Inflammation of this membrane arises from injuries done to the skull, and the symptoms are—nausea, vomiting, thirst, head-ach, vertigo, confusion of sight, quick, full, and hard pulse, restlessness, pain and tense feel of the head. The symptoms indicating suppuration within the cranium, never appear at an earlier period than the sixth day; generally between the eighth and twentieth days.

MORBID ANATOMY.

There is generally found a small quantity of purulent matter lying (at the site of the injury) on the surface of the dura

mater. When this membrane is raised, it presents a degree of redness more or less intense, and its vessels are surcharged with crimson-coloured blood. At the same time we find the entire surface of the hemisphere covered by a yellow purulent fluid, which adheres so tenaciously to the pia mater that very little of it will flow off; indeed, the colour and consistence of this fluid would lead us to suppose, that it was formed of a commixture of pus and coagulated lymph. Sometimes matter has been formed within the cranium so early as the third and fourth days.

A CASE OF IDIOPATHIC INFLAMMATION OF
THE DURA MATER.

The symptoms were—irregular attacks of fever, want of sleep, loss of appetite, nausea, and severe headach, delirium, coma—death.

DISSECTION.

On raising the calvarium, a good deal of purulent matter escaped, which had been collected betwixt the bone and the dura mater. The space, in which it had been contained, was defined by an irregular elevated margin of adventitious membrane, by which the dura mater had adhered to the bone, the included space being about the size of a crown piece; it was on the anterior part of the right hemisphere. The dura

mater included within this space was depressed, its surface was in some places ulcerated, and in others black; but the membrane was quite entire, and the bone was sound. On raising the dura mater, the inner surface of this portion had the same irregular ulcerated appearance as the outer surface, and when held up to the light, the membrane at the part appeared to be in some places considerably thickened, in others very thin.

When the dura mater is inflamed, adhesions are frequently formed between it and the other membranes.

In softening of the dura mater its laminae are separated, and present at cer-

tain points a flocculent appearance, as if it had undergone maceration for some time in a weak solution of acetic acid. There are seldom or never any vessels to be seen in the neighbourhood of the softened parts.

Ulceration of this membrane is of very rare occurrence.

Scrofulous tumours are found adhering and sometimes passing through the texture of the dura mater. They are generally indurated and regular in their formation. They receive a covering from the arachnoid.

They present, when sliced, a smooth omogenous substance of a pale straw

colour, similar in appearance to the kernel of a horse-chesnut. Sometimes the centre of these tumours undergoes the softening process, and presents a curdly matter.

The dura mater is frequently found thickened and more opaque than natural. At some points the deposition of cartilaginous matter* is very great, and pre-

* *Cartilaginous matter*.—Cartilage, when divided, seems to be homogenous, and without any appearance of fibres, vessels, or nerves; but, when carefully macerated in a weak solution of acetic acid for a few months, a fibrous texture becomes apparent, and the phenomena, which they exhibit in health and disease, prove the existence of a vascular and nervous structure.

sents a nodosity of some thickness. I have met with tumours of this kind which equalled in size a large orange.

Fungoid tumours are fibrous in their texture, sometimes crossed by enlarged blood-vessels. In some points they become softened and broken down, and contain blood effused into their substance. In some cases we find only one of them, in others several; which may be encysted, circumscribed, and more or less irregular. At first they are flattened before the escape beyond the skull, and afterwards assume the form of a mushroom, the pedicle corresponding to the aperture in the cranium.

A deposition of bony matter* into the texture of the dura mater, and between it and the arachnoid membrane, is frequently met with. The patches are small, irregular, and scaly; the falx cerebri and tentorium have been found completely ossified.

* *Chemical Analysis of the Bone.*

Cartilage	32.17
Blood-vessels	1.13
Fluate of lime	2
Phosphate	51.09
Carbonate of lime.....	11.30
Phosphate of magnesia	1.16
Soda, muriate of soda and water ..	1.20

100

Bony matter.—A CASE.—On opening the head, and slitting up the dura mater, there was found on the inner surface of the part of that membrane corresponding to the middle of the left temple, a solid mass of bone, upwards of an inch in length, and about half an inch in breadth, with very irregular sharp edges, and as thick as a crown piece. Two small pieces of bone, each the size of a barley-corn, were also found attached to the duramater, and situated at small distances from the larger ossification.

INFLAMMATION OF THE ARACHNOID MEM-
BRANE AND PIA MATER.

It is very difficult to distinguish inflammation of the arachnoid membrane

from that of the pia mater. The symptoms are—head-ach, nausea, vomiting, fever, impatience of light, want of sleep, delirium.

The attack is most commonly preceded by sudden and long-continued paroxysms of convulsion, and, in some cases, by head-ach and vomiting.

MORBID ANATOMY.

When meningitis has existed for some time, the arachnoid membrane acquires a real increase, both of thickness and density; it loses its transparency, and presents somewhat of a milky appearance. It has sometimes acquired the

thickness of the pleura, pericardium, and even of the dura mater.

The arachnoid is sometimes covered with a false membrane, more or less thick, and more or less extensive; but it is rare to find adhesions between the two layers of the membrane.

This membrane may lose its polished appearance, become rough, and covered with small granulations, which, when very minute, give it an appearance as if covered with down. This is generally observed in the ventricles.

Cartilaginous depositions and chalk-like spots have been found in that part of the arachnoid membrane which covers

the spinal marrow. Bone has been found in the same situation, but this last is a rare occurrence.

Delirium tremens seems to differ from all other mental derangements. It comes on gradually, and several days elapse before it arrives at the stage of its greatest violence. It is attended by tremors of the whole body, but particularly of the hands, with profuse sweating, and almost insuperable watchfulness.

In delirium tremens the veins of the pia mater are very much loaded, and generally there is an effusion of serum between the pia mater and arachnoid membrane.

Typhus Fever.—The pia mater is considerably surcharged with a dark fluid blood, the

arachnoid is milky or opaque in some places, and a serous fluid, and sometimes spots of lymph, are effused between the two membranes, while the substance of the brain itself, when sliced, exhibits more bloody points than natural.

The appearance of the brain generally met with in those who die of cholera in the East Indies—the sinuses and veins of the brain and its membranes are always distended with black, thick, and viscid blood; the tunica arachnoidea is frequently opaque and somewhat thickened, and adherent to the adjoining membranes. The brain is sometimes soft and pulpy; but it seldom presents any very decided marks of increased action.

PIA MATER.

In inflammation of the pia mater, the vessels are much more numerous than in its natural state; they are filled with a florid blood, and form, by their anastomosis, a beautiful net-work. It does not frequently occur, when the pia mater is inflamed, that it becomes so uniformly red as to shew no interstices between its vessels—a circumstance which happens in the inflammation of some other membranes. When the pia mater is inflamed in a high degree, pus is generally formed, and sometimes diffused over the whole upper surface of the brain.

Dura mater.—CASE.—A young gentleman

had experienced for twelve or fifteen days an intense head-ach, principally at the bottoms of the orbits, and then was seized with delirium, fever, agitation, and occasional vomitings.

Dissection.—The internal surface of the dura mater was found in some places covered with a layer of nearly fluid pus; the membrane itself was highly injected. A great portion of the superior surface of the hemispheres presented the appearance of pus, being soft, yellow, and nearly liquid. The same was seen in the fissura magna, and several other parts of the brain's superficies. The pia mater was every where intensely injected.

Case of Hydrophobia.—Upon dissecting

back the scalp, it did not exhibit any undue degree of vascularity. The inner surface of the calvaria was turgid with blood.

The dura mater presented a general scarlet blush; and upon raising it from the surface of the tunica arachnoidea, a preternatural adhesion was observed parallel to the course of the longitudinal sinus upon the left hemisphere of the cerebrum. The tunica arachnoidea was observed to be opaque in patches; but this appearance was not general. There was not any effusion beneath it, between it and the pia mater. The pia mater manifested a great degree of vascularity; a general vivid redness pervaded its whole surface. The vessels upon the surface of the cerebrum were gorged with blood.

Several horizontal sections of the substance of the cerebrum, displaying its medullary structure, exposed numerous bloody points, from which blood afterwards oozed; in fact, the substance of the cerebrum appeared injected with blood. Nothing remarkable was observed in the lateral ventricles, nor was there any deviation from the usual appearance in the plexus choroides of each side, or the velum interpositum connecting them.

In the commissura mollis no deviation from its usual consistency was noticed.

The pia mater investing the cerebellum was particularly vascular; but the substance of the cerebellum did not partake of the vascularity; its consistence was softer than usual. The medulla oblongata was natural; the theca vertebralis very vascular.

The bones of the skull were remarkably thin.

Erysipelas.—The brain always exhibits traces of excessive vascular action. Its vessels are over distended with blood; lymph and serum are deposited upon and between the arachnoid coat and dura mater, and at the basis of the brain; and sometimes the lateral ventricles are filled with serum.

CONGESTION OF BLOOD IN THE VEINS OF
THE PIA MATER.

Symptoms.—Giddiness, confusion of intellect, heaviness approaching to sleepiness, and sometimes complete stupor.

MORBID ANATOMY.

The most common morbid appearance of the pia mater is that of the veins being surcharged with blood. The larger vessels are distended to their utmost extent, and the capillary vessels are empty.

Congestion.—Congestion of blood in the veins of the head is a very common appearance after death, particularly so in persons who have been subject to chronic disease.

Death from Arsenic.—The brain has seldom been examined. It is generally natural; but, in one case, it is stated to have been unusually turgid on its external surface, and the plexus choroides very vascular.

Death from Sulphuric Acid.—The patient survived two months after taking the acid.

INFLAMMATION OF THE VEINS.

Symptoms. — Severe head-ach, fever, nausea, convulsions, rigors, delirium, coma, death.

Head. — Clear lymph beneath the dura mater, diffused over the whole brain. The same coagulated beneath the tunica arachnoidea, and all the cerebral vessels much gorged. Small quantity of fluid in the lateral ventricles. Basis of brain natural.

Death from Carbonic Acid.—The vessels of the head and brain are filled with a dark fluid blood, which flows freely from the slightest incision. Effusion of serum, tinged with blood, is found, particularly in the ventricles.

Death from Sulphurated Hydrogen.—The head was putrid within forty hours after death; the skin bluish and elevated by gas.

MORBID ANATOMY.

When the internal tunic of a vein presents any traces of inflammation, the

The blood in the sinuses of the brain was black and fluid. The substance of the brain softened, and of a greenish hue.

Death by Hanging.—The principal vessels of the neck and head are generally filled with blood, and those of the brain sometimes ruptured.

Death by Drowning.—A great accumulation of blood in the cerebral vessels and jugular vein.

Death by Strangulation.—In the case of a woman who had been strangled *per manum*, the tympanum of the left ear was lacerated, and from it flowed about an ounce of blood; the vessels of the brain were unusually turgid; red blood was extravasated in the ventricles, and also on the base of the cranium.

cellular texture, which is situated at the exterior of the tunic, is observed to be much injected, and that injection is limited to the inflamed part; but if the inflammation be more advanced, the internal tunic is reddened all over, and there are no interspaces of white appear-

Death from Prussic Acid.—The pia mater and vessels of the brain are generally found surcharged with blood, and it emits the smell of bitter almonds.

Subacute meningeal Inflammation in the Phthisical, during the last Days or Weeks of Existence.—The pia mater and the choroid plexus are more or less injected; the arachnoid is dull, opaque, and lustreless; the sub-arachnoid tissue is infiltrated, especially in the vicinity of the vessels; and serum is effused in the ventricles.

ance; in proportion to the degree of inflammation, is the colour more intense. This colour is very different from that which is produced by the mere absorption of the blood; for it may be easily seen, that the colour in cases of inflammation depends upon the quantity of blood contained in the small vessels, which are spread out on the internal surface of the vein. These vessels have a reticular disposition; and it is in this sort of network that the inflammation is principally seated. Afterwards the other tunics become implicated, and the coats of the vein then look like a homogenous mass. In these cases the internal tunic is more

or less thickened; the sides of the vein become sometimes so much enlarged, that, on making a transverse section of it, the cavity remains of a circular figure like the section of an artery. The veins having been, or being, thus affected, present some varieties of appearance; sometimes their sides are smooth, and shining; at other times uneven; sometimes in a state of suppuration, with small ulcerated surfaces; and when such veins float in water their surface has a villous appearance.

It sometimes happens, that, in consequence of inflammation, an exudation of albuminous matter takes place, as in croup, which lines the internal tunic

completely, or partially, varying also in its consistency, in proportion to the degree of inflammation. Sometimes the separation of it from the sides of the vein is easily effected, and at other times it adheres with great tenacity, so that it is impossible completely to detach it.

Case.—Inflammation of the Veins of the Brain.—After removing the calvarium, a longitudinal incision of the dura mater on the right side of the falx, shewed that the middle vein of the cerebrum was very much swollen and tortuous, especially on approaching the falx, where it was about to open into the superior longitudinal sinus ; it was of the size of a common pen. It was found filled with a

yellow puriform matter which obliterated its cavity. In the course of this vein, the arachnoid was of a transparent white colour. The corresponding vein on the opposite side was in the same state. In detaching the falx, a tumour was remarked along its surface, from two to three inches in length, and from ten to twelve lines in thickness. This tumour, on which could be distinguished the tissue of the arachnoid and dura mater in the healthy state, occupied the course and situation of the superior longitudinal sinus. On dissection, it appeared to be formed of a greyish cellular tissue, and was filled with pus. The whole cavity of the sinus was thus degenerated.

1 The lateral ventricles were empty. On

making a longitudinal section of the left hemisphere, considerable disorganization was discovered in all the posterior, and in a great part of the middle lobe, on the outer side of the lateral ventricle. This was formed by the entrance of yellow pus into the cerebral substance. There was also an effusion of serum at the base of the cranium.

AIR IN THE VEINS OF THE PIA MATER

Is of very unusual occurrence, although the contrary has been stated by some pathological writers. Two cases out of several hundreds of patients who died of malignant fever, and who were examined twenty hours after death, did exhibit bubbles of air in the larger veins; and

the blood in the heart apparently contained a quantity of gas mixed up with it, and it was in a fluid state, and of a rich purple colour.

SCROFULOUS TUMOURS

Are sometimes met with adhering firmly to the cerebral surface of the pia mater. In texture, they are similar to the glands when afflicted with scrofula.

WATER ON THE SURFACE OF THE BRAIN BETWEEN THE MEMBRANES.

Water is sometimes poured out between the pia mater and brain. There is in these cases generally a greater quantity than natural in the lateral ventricles.

A more common situation for fluid, than the last, is between the pia mater and arachnoid membrane, either in separate portions, or effused over a large extent. In such cases, the vessels of the pia mater are more than ordinarily distended with blood.

The arachnoid membrane is genenally thickened and opaque. When effusion in this situation is considerable, there is frequently fluid in the theca vertebralis.

CYSTS.

Small cysts have been found attached to the posterior cerebral surface of the brain. They contain a small quantity of

a limped fluid, and in the generality of cases are produced by a separation and an elongation of the arachnoid membrane from the pia mater.

A PART OF THE PIA MATER BONY.

Case.—An individual, forty-nine years of age, who died from softening of the brain.

A portion of the pia mater was converted into bone. The ossified part consisted of two flat pieces, about the size of an inch, which adhered to the brain by one of their sides, and the other to the arachnoid.

INFLAMMATION OF THE SUBSTANCE OF
THE BRAIN.

Symptoms.—Sense of weight in the head, tinglings in the ears, deception of

vision, irritability of the retina, numbness of one side of the body, pain or prickling of the limbs, convulsions, paralysis, coma.

MORBID ANATOMY.

The medullary matter is in most cases altered, though not in a very striking degree. It loses something of the usual pearly whiteness which it exhibits in healthy adults, and acquires a faint tint of red, somewhat approaching the colour of peach blossom, or the tinge of redness which belongs to it in the infantile state.

The cineritious portion also becoming redder at the same time, there is an ap-

proach to each other in the colour of the two substances, which greatly lessens the distinction between them. The venous trunks, which traverse the medullary substance, and which are hardly seen in health, become numerous and conspicuous, and acquire unusual firmness, so as to admit of being drawn out with the forceps to the extent of perhaps half an inch; at the same time, numerous minute drops of blood are seen to issue, when the substance is divided, so as to give it a speckled appearance, or as if sprinkled over with brick-dust. There is also an increase of firmness in the general substance of the organ, produced

by recent inflammation, and which tends to preserve it longer than usual from decay.

ABSCESSSES.

Symptoms. — Of suppuration of the brain, violent and constant pain in the head, disturbed sleep, rigors, convulsions of the extremities, involuntary piercing cries, dejected countenance, accompanied with a lemon tint of skin.

MORBID ANATOMY.

The red colour of the cerebral matter gradually disappears, the blood is replaced by a sero-purulent fluid which

enters into the substance of the brain, combines with it, and gives to it, according to the extent of the admixture, a greyish dull white, or yellowish green colour.

Sometimes pus is formed in distinct abscesses lined by a soft cyst, or an extensive portion of the cerebral substance is found in a broken-down corrupted state, in which, without any well-defined cavity, pus is found mixed with the disorganized cerebral matter. When abscesses are small, there is an ulcerated appearance of the cavity in which the pus is contained.

ABSCESS OF THE CEREBELLUM.

CASE.—The surface of the brain was natural, the substance shewed marks of increased vascularity, and the ventricles were distended with colourless fluid. The left lobe of the cerebellum was entirely converted into a bag of purulent matter of a greenish colour and intolerable fœtor. The sac was soft and organized, and appeared to be of recent formation. Symptoms were—pain in the left ear, violent head-ach, dilatation of the pupils, squinting, coma, death.

ULCERATION OF THE BRAIN.

Examples of ulceration of the brain are very rare, and when they have been found, they have generally been seated

in the interior of the ventricles, the results of chronic irritation. The symptoms are, violent head-ach, with a sense of tightness, nausea, vomiting, great prostration of strength, giddiness, convulsive motions of the limbs, paralysis.

MORBID ANATOMY.

Ulceration or solution of part of either of the surfaces or middle portion of the brain, so as to present a hollow or depressed surface, rough, irregular, and covered partially with bloody or albuminous exudations.

CASE.—*Ulceration of the Brain.*—It presented on the lower part of the right anterior

lobe an ulcer, measuring seven lines by three, of a yellowish appearance, having its surface hard and dry, and its edges unequal and ragged; the cerebral substance lying beneath it was healthy; the portions of dura and pia mater, which covered that part of the brain, were destroyed by erosion. The rest of the organ presented no alteration. The pia mater was acutely inflamed, and the sinuses were gorged with blood.

SOFTENING OF THE BRAIN.

Symptoms. — Dull pain or sense of weight in the head, impaired memory, somnolence, deafness, loss of vision, and the power of utterance, paralytic affections of the face, head, and members, coma.

MORBID ANATOMY.

Softness in a greater or less degree of the cerebral matter, but without any change of the natural colour.

This is, however, different from the suppurative process, having neither the colour nor the fœtor of pus; but the medullary portion of the brain in which it is most commonly observed, retains its pure milky whiteness and homogeneous quality, whilst the grey substance remains in its natural state, whatever be the degree of softening.

It may be found in any part of the brain, but most commonly in the dense

white matter forming the corpus callosum, fornix, and septum lucidum. The septum is generally found in such cases perforated by a ragged irregular opening, and the fornix has either entirely lost both its figure and its consistence, or retains its figure while it is left untouched, but falls down into a soft mass when the slightest attempt is made to raise it.

It has been stated that no vessels can be traced into the diseased portions of brain altered by softening; and several writers consider this degeneration to be disease of the nervous system, altogether independent of inflammation.

It is true that this morbid alteration

has been observed in cases in which no trace of local congestion could be found ; but, in general, the membranes in the neighbourhood are found red and thickened, and their vessels injected with blood, and sometimes those which penetrate into the substance of the medulla, though not visible in the healthy state, become so by being injected, and give to the part a more or less deep tinge of red. These circumstances tend to shew that softening is produced by inflammation, which is further confirmed by the fact, that it is constantly seated in those parts of the brain which are most vascular in their structure, such as the corpora striata,

optic thalami, and convolutions of the brain.

Case.—The patient just prior to death was the subject of hemiplegia of the right side; sensation and power of motion were nearly gone, particularly of the right leg.

On examination after death no lesion could be discovered, excepting in the left corpus striatum, which was red and very soft; and in the thalamus opticus of the same side, which had undergone a similar change.

Case.—In a patient who died of disease of the brain and had hemiplegia, the optic thalamus and corpus striatum of the side opposite to that on which the paralysis existed were found completely softened.

INDURATION OF THE BRAIN.

Symptoms.—This state of brain occasions loss of memory and derangement of

the mental faculties, and its long endurance is calculated to induce that complete obliteration of the intellect which constitutes fatuity.*

* Insanity, in its ordinary acceptation, is usually divided into mania, melancholia, and idiocy. The following is the order pursued by Esquirol, which is certainly better calculated to illustrate the varied appearances of the disease:—

1. Mania—in which the hallucination extends to all kinds of objects, and is accompanied with some excitements.

2. Monomania, or melancholy—in which the hallucination is confined to a single object, or to a small number of objects.

3. Dementia—wherein the person is rendered incapable of reasoning, in consequence

MORBID ANATOMY.

Instead of the usual compressible elastic character which it presents in the sound state, the brain may become like coagulated or boiled albumen, or like a portion of brain which has been immersed in strong alcohol or dilute acid. It will bear to be pulled out with some force, and will readily re-act so as to restore itself; or when pressed, will recover its former shape. The medullary matter is almost invariably penetrated

of functional disorder of the brain not congenital.

4. Idiotism — congenital, from original malconformation in the organ of thought.

with numerous loaded capillaries, and more or less effusion of serous fluid is found beneath the arachnoid membrane and in the ventricles. The latter are sometimes much dilated.

In an extreme state of atrophy and hardening found in the brains of idiots, the induration differs from that already described, chiefly in degree. A portion of brain, so changed, becomes a compact inorganic-looking mass, resembling in colour, consistency, and density, indurated egg or even cheese. The cerebral substance is depressed, shrunk, and condensed, and seems utterly void of vessels or capillaries. This hardening affects the white matter more than the grey.

TUMOURS IN THE SUBSTANCE AND ON THE
SURFACE OF THE BRAIN.

Symptoms.—Severe head-achs, continued or intermittent, with twitching of one or more of the extremities, pallid countenance, convulsions, loss of memory, paralysis, epilepsy, coma, hydrocephalus.

MORBID ANATOMY.

INDURATION OF SOME PORTIONS OF THE
SUBSTANCE OF THE BRAIN.

It is very common to meet with an indurated portion of brain, of an uniform smooth texture, and possessing a considerable degree of firmness, approaching

the consistence of coagulated albumen ; but little change takes place in its colour, unless it assume a pale-yellow or orange-grey tint.

The surrounding cerebral matter is almost invariably softened. Generally a quantity of fluid is found in the ventricles.

SCROFULOUS TUMOURS.*

These tumours, which are various both in size and density, are found embedded in

* Common tubercles may be formed, attain a considerable size, and long exist in the various parts of the brain and its membranes, without producing much trouble or sensible disturbance of function.

But, when they become excited, inflamed,

the cerebral or cortical substance of the brain. They are of a pale-straw or deep yellow colour. In texture they resemble a lymphatic gland. The brain adheres to them, and around their edges it appears often more vascular than usual. Some of the tumours are at times of a

or suppurated, they begin their work of disorganization in the contiguous parts, and produce trains of symptoms.

Tubercles have been found, of the size of a garden pea, hanging pendulous from the tentorium. Similar masses have been met with in the medullary substance of the right hemisphere.

An oblong tubercle, the size of an almond, was found in a state of suppuration, and embedded in the centre of the pons varolii.

pultaceous consistency; they vary from one to two, three, four, five, or six, and in size from that of a hemp seed to a walnut. They sometimes pass on to ulceration, and then have all the characters of scrofulous ulcers.

Case.—A child, *ætat.* two, was affected with general anasarca, but apparently without pain: he died with symptoms of hydrocephalus.

Small quantities of lymph were found here and there between the tunica arachnoid and pia mater; the former membrane was slightly thickened in some places over the posterior part of the brain; and where it covered the *tuber annulare*, it was thickened

to a very extraordinary degree. On the inferior part of the left hemisphere of the cerebellum was a scrofulous tumour, of about the size of a pigeon's egg, containing soft curdy matter. The cerebellum below was softened, the sheath of the optic nerves was inflamed, and the ventricles were distended with fluid.

FLESH-LIKE TUMOURS.

Fleshy tumours are met with sometimes embedded in the substance of the cerebral mass; at other times attached to its external or cortical texture. They are of a light rose or pale flesh colour, indurated, and, when sliced, present a smooth surface, and a homogeneous texture.

Case. — A boy, two years and nine months old. Dilated pupil, palsy of lower extremities and sphincters, followed by convulsions of the face, and palsy of the upper extremities and trunk; death by paralytic asphyxia.

In the anterior lobe of the right hemisphere a large dusky red tumour, rather rough. In the posterior lobe of the same hemisphere, and in that of the left, a tumour each. In the cerebral substance on a level with the mesolobe, four more tumours; the largest the size of an orange; the smallest not less than a chestnut. They were very firm, of a dusky red colour, and with streaks of white interposed.

ADIPOSE TUMOUR.

This tumour has a smooth and solid appearance, and when divided is found to be composed of an aggregation of small lobules, which have a yellow colour and lardaceous consistence : no vessels can be seen passing through it.

Case.—A woman of seventy-seven, with convulsive motions of the left arm, followed by palsy of that and the left leg, impaired speech, complete hemiplegia, and death.

A firm, yellowish, lardaceous, bulky, many-lobed mass, occupying the greater part of the posterior lobe, almost the whole of the middle lobe, and part of the anterior lobe of the right hemisphere. Contiguous to the optic thalamus, which was entirely softened, a lobule

penetrated below the striated body and reached the exterior of the middle lobe, where it was connected with the membranes and bone. The surrounding parts were all softened.

SCIRRHOUS TUMOUR.

This tumour is hard, but in consistence varies from that of cartilage, or bacon-rind, to that of the intervertebral ligaments. It creaks under the point of the scalpel when scraped. It is white, bluish-grey, but slightly coloured; sometimes colourless and semi-transparent. It forms irregular masses, rarely lobulated, and commonly homogenous. It is sometimes divided internally by fibrous or

cellular intersections, and this internal tissue is regularly radiated like a turnip, sometimes alveolar, and sometimes irregular. Distinct vessels are rarely seen in it. At an advanced period, cavities begin to be formed, in which is contained a fluid or semi-fluid matter, sometimes jelly-like, at other times thinner, and occasionally tinged with blood.

Case.—A woman of forty, who had been in a state of idiocy for six months after severe mental distress. In the right hemisphere, beneath the mesolobe, corresponding to the striated body on the outside, and projecting into both ventricles, was found a hard tumour of a triangular shape, the posterior

angle elongated, the right anterior angle advancing to the anterior extremity of the right lobe. It consisted of two sorts of structure; one in the centre, as large as a pigeon's egg, had the consistence of fibro-cartilage, and resembled fibrous substances proceeding to the cartilaginous state; the other, exterior, greyish, was confounded with the cerebral substance, from which it appeared to be formed.

ENCYSTED TUMOURS.

These tumours, consisting of cartilage, or a mixture of cartilage and bone, are occasionally lodged within the brain; and these sometimes have attained a considerable size. They are covered by a

dense membrane, like the pleura, and are very irregular on their surface, owing to a number of nodules of different sizes ; and when a section is made of the tumour, it is found to contain cells.

ENCEPHALOID TUMOUR.

In the state of crudity it forms masses of various sizes : each mass is lobed and lobulated. Numerous very minute vessels ramify in the cellular tissue, and in the cerebriform substance itself.

The coats of these blood-vessels are very fine, and easily ruptured ; and this accident gives rise to clots of extravasated blood in the interior of the tumours. In

its perfect state it is homogeneous, and of a milky-white appearance. In different parts it has commonly a slight rose tint. It is opaque when examined in masses; but, in thin slices, it is in a slight degree semi-transparent. In consistence it is like the human brain, but is commonly less coherent, being more easily broken and comminuted by the fingers.

Case.—Fungus Melanodes of the Brain.

—The substance of both hemispheres of the brain at their posterior part was unusually soft, and readily yielded to a slight pressure of the finger. On cutting into the left hemisphere, on a level with the corpus callosum, a large dark blood-coloured mass pre-

sented itself; which at first had the appearance of coagulated blood; but, on examining it minutely, it was found to be of a firm consistence, having numerous small vessels passing through its substance. This mass seemed to have no connexion with the surrounding brain, which was quite healthy, and formed a sort of bed for it. In the substance of the right hemisphere, there were also several dark-coloured masses, of the size of a pigeon's egg, very similar to the texture of that found in the left side.

MELANOSIS OF THE BRAIN

Is extremely rare, although cases are now and then met with. The masses of

melanotic matter vary in size from the point of a needle to that of an orange.

They are sometimes pretty regular, sometimes lobulated. These parts are connected, and the masses surrounded by the cellular tissue of the organ. The vessels follow this tissue, but do not penetrate into the black substance.*

* A French chemist states, that the substance of the tumours in melanosis is a deposition of the colouring matter of the blood, and of fibrine, each under a particular modification, and forming three different fatty substances. The first soluble in alcohol, at a moderate temperature, and disposed to crystallize in brilliant scales; the second is soluble in alcohol at a boiling heat only;

BONE IN THE SUBSTANCE OF THE BRAIN.

Ossific matter is a very unusual product in the substance of the brain. The left corpus striatum has been found osseous; and in one of the corpora quadrigemina, a mass of chalk was found. Calcareous matter has been taken from the base of the brain at the union of the optic nerves. In the cerebellum (left lobe) was found a body, one inch long, and ten lines broad, consisting of alternate layers of chalky matter, fluid albumen, and solid

the third is a fatty substance, in a fluid state, at the ordinary temperature of the air; of a reddish colour, containing a large portion of the phosphates of lime and iron.

albumen. In the substance of the brain of an old man, who died from apoplexy, was an encysted bony tumour, very irregular in its form and surface: it weighed one ounce and two scruples.

Case.—Osseous tumour in the brain of a maniac. The arachnoid membrane was in some parts opaque, having a milky appearance, and thickened, the effects of previous inflammatory attacks. A portion of this membrane, covering the middle lobe of the left hemisphere of the cerebrum, was of uneven surface, seeming as though some calcareous matter were deposited beneath it, which on examination proved to be an osseous tumour, of the size of a hazel-nut, embedded in the

substance of the brain, its upper surface only being visible.

CAVITIES IN THE BRAIN

Are sometimes found separated from the substance of the brain by a new membrane, formed of the remains of the cellular tissue, and vessels which had escaped the effects of suppuration, and which, when compressed towards the circumference of the cavity, interlace mutually, become organized, gradually increase, and are changed into a membrane, whose thickness and density are progressively augmented. The internal surface of these cysts are then smooth;

the pus which they contain assumes more and more the character of pus formed in cellular tissue. Sometimes cavities, found in the substance of the brain, containing a serous fluid, are supposed to be the remains of cavities formed by extravasated blood, in which cases the patients have lived for months or years after their formation.

Case.—Man, aged fifty—Symptoms, severe head-ach, impaired vision, speech indistinct, and sometimes inarticulate, strabismus, general weakness, impaired intellect, coma.

In the substance of the left hemisphere of the brain, towards the posterior part, there was a soft and vascular cyst, containing about

two ounces of a thick, colourless, albuminous fluid, coagulable by heat, and exactly resembling the albumen of an egg. The cerebral substance around the cyst was softened; the brain in other respects was healthy. The ventricles contained a small quantity of serous fluid, and had no communication with the cyst.

THE BLOOD CYST,

Although not common, has been observed. It consists of a membranous cyst, sometimes containing small cysts, the inner surface of which is composed of a vascular tissue, from which blood or bloody fluid exude, forming a mass resembling layers of coagulated blood.

Case.—Symptoms—nausea, head-ach, particularly above the eyebrows, vision impaired, pupils dilated, convulsions, coma, death.

The skull very thin and diseased, dura mater unusually vascular, the brain hard; half an ounce of limped fluid was found in the ventricles; the choroid plexus very pale; tumour, of about the size of an orange, grew from the middle lobe of the right hemisphere, and the brain around it was as soft as pulp; the part of the skull on which the middle lobe rests was carious. The tumour had a vascular coat, and was divided into cysts, lined by very vascular membranes. The tumour was in some places cartilaginous, but in others as soft as custard.

HYDATIDS

Have been found embedded in the substance of the cerebrum and cerebellum. In one case, there were numerous hydatids, one of them of the size of an egg, and containing three small hydatids within it.

Acephalocyst, formerly called hydatids, and long confounded with cysts, properly so called, have the form of simple vesicles, of a spheroid or oval shape, very variable in size, soft, and in consistence and appearance exactly like that of half-boiled white of egg. Their coats are diaphanous or semi-transparent, colourless, or of a milky colour, varying

sometimes towards reddish, yellowish, greenish, or greyish. Sometimes they are of an unequal thickness, but frequently they are uniform in this respect. These vesicles contain more or less of a fluid, which is commonly serous and limpid, sometimes turbid, and tinged with a yellowish or sanguine hue. Sometimes a large vesicle includes several smaller ones; at other times still smaller ones are found adherent to the internal or external surface of their parent, from which they only appear to be separated when they have attained a certain size.

Acephalocyst present no distinguishable organ, and offer the simplest ex-

ample of an animal that can be imagined. They are always inclosed in a cyst which completely separate them from the surrounding parts. The cysts are commonly of a fibrous nature, but frequently portions of a cartilaginous or bony character are found in them. Their internal surface is rarely smooth, and frequently it is so unequal as to have the appearance of being lacerated. Sometimes it is lined by an opaque albuminous matter, semi-concrete, and partially reduced to detritus, of a yellow ochre or tawny colour. When there are several hydatids in one cyst, this also contains a fluid, in which they float, which is sometimes limped, some-

times turbid, yellowish, or sanguineous. When the cyst contains only one hydatid, this sometimes fills it completely, and lines, as it were, its internal parietes.

Case 1.—The patient, aged twenty-seven, laboured constantly under an affection of the head; one day the pains increased, and he suddenly died. There were found under the dura mater several oviform hydatids, some adhering to the arachnoid, others being only contiguous to it, and sunk in a depression in the brain. There were also several in the cerebral veins, in the corpus callosum and left middle lobe, and the right optic thalamus.

Case 2.—A man, aged sixty, epileptic

for six years, with loss of memory; died suddenly.

An hydatid of the size of a pigeon's egg was found in the posterior part of the right hemisphere. It contained a yellowish fluid, which was partly gelatinous. The substance of the brain under it was hardened.

FLUID IN THE VENTRICLES.*

Symptoms.—Languor, inactivity, loss of appetite, nausea, vomiting, pain in the

* The sub-inflammatory state of the nervous central mass frequently produces a secretion of serum in the ventricles of the brain. This is called acute hydrocephalus, a disease which differs from chronic hydrocephalus, inasmuch as the latter, which is

head, stupor, convulsive motions, picking of the nose, grinding of the teeth during sleep, occasional flushings of the face, a motion of the head occasionally upon the pillow from one side to the other, occasional sighing, and towards the latter end of the disease, a dilatation of the pupils and squinting.

most generally congenital, is not accompanied by an inflammatory process.

When this affection attacks the spinal marrow and its coverings, it is termed hydro-rachitis, of which the disease termed spina-bifida is a remarkable variety.

MORBID ANATOMY.

An accumulation of water* in the ventricles of the brain, is one of the most

* Analysis of the fluid found within the ventricles of the brain in hydrocephalus:—

The solid contents of 1000 grains of the fluid appear to consist of,

Water	990.80
Muco-extractive matter, with a vestige of albumen	1.12
Muriate of soda	6.64
Sub-carbonate of soda, with ves- tige of an alkaline sulphate,....	1.24
Phosphates of lime, with traces of phosphates of magnesia and iron	20

1000.00

common appearances. In some cases this amounts only to a few ounces, but occasionally to some pints. When the quantity of water is considerable, the fornix is raised at its anterior extremity in consequence of its accumulation, and an immediate opening or communication is thereby formed between the lateral ventricles. The water is limpid. In some instances, the water in hydrocephalus contains a very small proportion of coagulable matter; and in others it is entirely free from it. When the water is accumulated to a very large quantity in the ventricles, the substance of the brain appears to be a sort of pulpy bag, con-

taining a fluid. The skull, upon such occasions, is very much enlarged, altered in its shape, and exceedingly large in proportion to the face. On removing the scalp, the bones are found to be very thin, and there are frequently broad spots of membrane in them. These appearances are, however, only to be observed where the disease has been of long continuance. We frequently find the veins of the membranes of the brain, and those in the ventricles, gorged with dark blood. Sometimes the ventricles are so much enlarged that the cerebrum resembles two vessicles lying on the cerebellum.

Case—An Anasarcaous serous collection in the Brain.—The patient had complained of no pain, nor had he exhibited any symptoms of cerebral disturbance. He exhibited a dulness of apprehension, and general sluggishness of intellect, which were supposed natural to him, but which probably arose from the morbid changes in the brain.

Dissection.—The arachnoid membrane was thickened, opaque, and tough over the whole convexities of the cerebral hemispheres, and the cellular texture of the pia mater loaded with serum. On taking off the membranes, the surface of the brain was drenched with water, and a large quantity ran down. The cerebral convolutions were separated by considerable intervals, which had been occupied by the

anasarcous pia mater. Each ventricle contained about two ounces of the clearest and most transparent fluid; the increased secretion had raised the fornix, so as to make the communication between the lateral ventricles direct. All the vessels of the brain were turgid, and the bloody points innumerable and large, wherever the cerebral substance was cut into.

Case.—*Hydrocephalus, with a protrusion of the Brain of a Child nine months old.*—Symptoms, uneasiness and fretfulness, frequent moaning and sighing, retching and vomiting, tossing of the hands and arms, diminished appetite, stupor occasionally, irregular fever, irregular state of bowels, wasting of flesh, convulsions.

Dissection.—Dura mater remarkably ad-

herent to the internal cranium. Fontanelle-ossification, very deficient. Serous effusion between the arachnoid coat and pia mater. Venous turgesence in the vessels of the surface of the brain. Lateral ventricles contain about two ounces of watery fluid. Plexus choroides, highly vascular. There is an aperture, of the size of a sixpence, between the lower portion of the frontal bone and the nasal bone, through which a protrusion of cortical substance of the brain occurred, and formed a tumour externally of the size of a gooseberry. This tumour was formed by a morbid growth of the cortical substance of the brain, and was covered with the arachnoid membrane, the pia mater, and a prolongation of the dura mater; it existed from the birth

of the child ; was removeable by pressure ; would disappear on yawning, and be violently protruded by crying or coughing.

BLOOD EFFUSED OR EXTRAVASATED.

(*Apoplexy.*)*

Symptoms.—Abolition of all the powers of sense and motion, accompanied with

* Dr. Serres has divided those cases of apoplexy which are accompanied by an effusion of blood, from the bursting of aneurisms of the cerebral arteries, into two genera.

The first he calls meningeal apoplexy ; the second, cerebral apoplexy. Both of these forms of the disease may be the consequence of the rupture of a vein, of an artery, or of an aneurismal tumour evolved on one or other of the arteries of the encephalon. The first

noisy or stertorous breathing, flushed, and sometimes livid countenance, prominence

species of the disease affects the membranes of the brain or spinal marrow; the second, the substance of the cerebro-spinal axis of the nervous system.

Meningeal apoplexy, the voluntary motions are not interrupted by palsy. In the cerebral form of the complaint, the voluntary motion is always paralysed in a greater or less degree, and is differently affected, according to the situation in which the fibres of the cerebro-spinal axis are ruptured.

In both cases the effused blood occurs in clots or coagula; in the cerebral, it is circumscribed, and lodged in excavations of the encephalon, whilst in the meningeal apoplexy, it is diffused, and may extend over the entire outer surface of the brain, and even into the anterior of the ventricles;

and immobility of the eye, with dilated pupil; foaming at the mouth; grinding of the teeth; the strength of the circulation remaining unimpaired.

MORBID ANATOMY.

Effusion of blood to a greater or less extent in the hemisphere of the brain, opposite to the side in which the para-

this difference in the nature of the extravasation is quite characteristic; for, in the first case, the blood is collected within a circumscribed cavity; and in the second, as the fluid issues from the ruptured vessel, it makes its way between the arachnoid and pia mater, and gains ever point penetrated by these membranes.

lysis has occurred. The fluid is found either in several small cavities, or accumulated in one mass.

Effusion of blood is very often the termination of softening, in the immediate neighbourhood of which disease the vessels give way, occasionally mingling their fluid with the softened mass. When blood is found on the surface of the brain, or on some of its membranes, it is in many cases the consequence of external violence.

It is generally observed, that the arteries of the brain are diseased in other situations beside the one from which the effusion takes place. The trunks of the

internal carotid afford frequent examples of it.

Some writers state that the period of effusion of blood can be occasionally determined upon by the appearance of the extravasated fluid. When death ensues quickly, at the end of three or four days, for example, it is found in the form of soft blackish clots; after a month or six weeks it becomes firmer, assumes a deep brown colour, and resembles the blood of aneurismal tumours; at a more remote period it becomes still more compact, and of a pale red colour, bordering on an ochreous yellow; lastly, it is entirely absorbed. Although no restora-

tion of cerebral matter takes place after cases of recovery from extravasation, yet the sides of the cavern may be converted, by a slow process of adhesive inflammation, into a membranous substance harder than the surrounding one.

Case.—A gentleman, aged fifty, was for several years subject to an affection of the head. At first, he was subject to attacks of giddiness and head-ach, with loss of recollection, and impaired speech. These symptoms were followed by violent paroxysms of pain, bordering on mania, with loss of recollection. Afterwards he had epileptic attacks, alternating with maniacal paroxysms, stupor, and apoplexy.

Dissection.—Connected with the fatal attack, there was a coagulum of blood, of the size of an egg, in the substance of the right hemisphere. The only other morbid appearance was a remarkably diseased state of the whole arterial system of the brain. It was most extensively ossified, with a thickened and very diseased state of the inner coat of the arteries, and, in many places, partial separation of it from the other coats. Scarcely any arterial branch could be traced through the whole brain entirely free from disease. The vertebral arteries were also much affected, especially the left, which was much enlarged, and its coats were thickened, ossified in spots, and brittle.

OSSIFICATION OF THE ARTERIES OF THE
BRAIN.

The internal carotids on the side of the cella turcica, are apt to become ossified in persons of advanced age, and a similar change is observed in their branches. Aneurisms of these arteries rarely occur.

Cartilaginous, ossific, and calcareous incrustations of arteries are, generally speaking, of an irregularly flattened form, and when they are of unequal thickness they project rather towards the outside than the inside of the vessel.

They are situated between the internal and middle coat, and being as it were

enchased in the latter, they sometimes retain the impression of its circular fibres on their outer surface. Their inner surface is sometimes smooth, and evidently covered by the internal coat of the vessel; in other cases, it is rough, and seems to have partially destroyed this tunic by its asperities. In examining cases of this kind minutely, we can perceive many points of ossification, which, extending themselves in their superficial diameter, reunite and form incrustations of a larger size. In some instances, these involve nearly the whole circumference of the vessel, and thus form a fourth tunic of a bony character.

The cartilaginous are the rudiments of the bony incrustations: their situation and mode of growth are the same.

In becoming ossified, small specks of calcareous phosphate are first deposited, and these, by their gradual extension and union, finally convert the whole into a homogeneous mass.

Case.—A female, *Æt.* sixty-four.—Attacks of head-ach, giddiness, and imperfect vision, occurring at uncertain intervals; afterwards mania; at last, after five years, death, with fever and delirium.

Dissection.—Two small aneurisms, each about five-eighths of an inch in diameter,

formed by dilatation of the internal carotid arteries, at the side of the cella turcica, and containing laminæ of coagulated blood.

CHANGE OF COLOUR OF THE CORTICAL PART
OF THE BRAIN.

Several cases are recorded of an alteration in the colour of the cortical substance of the brain. In one example, the usual ash colour was altered to a dark slate blue, with a slight tinge of green.

Case.—Symptoms—Violent pains in the head, partial amaurosis, wasting of flesh, impaired intellect, general sensibility very obscure, obstinate taciturnity, and profound coma.

Dissection.—The membranes of the head

were found injected, the pia mater infiltrated with serum, and the convolutions of the brain appeared closely packed together. The cortical substance had a very remarkable slate-grey colour, firm in its texture, and when cut, was immediately covered with bloody points of a very bright colour. The white substance was not like the cineritious, altered in its colour; but, like it, was much loaded with blood. The ventricles contained a large quantity of serum. The cortical substance of the cerebellum was also of a slate colour, and the cerebral masses generally had more consistence than usual.

HYPERTROPHY OF THE BRAIN.

If, in this state, the cranium be not prepared for it, in consequence of ossification having advanced too far, this development of size must necessarily be attended with considerable pressure, and give rise to all the symptoms usually attending acute hydrocephalus.

Case.—Cranium: it was from a line to a line and half in thickness, and the ossification of the fontanelles was not less thick than any other part.

The dura mater adhered firmly to the cranium, but did not present any alteration in its tissue. The pia mater was very red, and

slight sanguineous exudations were very observable in several places. There were also several white spots on it. The plexus choroïdes was also very much injected. The brain itself was exceedingly voluminous, and was firmer throughout than is usual in children of this age, (6 years.) Its substance was also slightly tinted with red.

Its principal development was on the upper and back part of the hemispheres; as a proof of which, it was necessary to make a perpendicular incision of nearly three inches, to reach the ventricles, which contained only a small quantity of reddish serum.

PLEXUS CHOROIDES.

Little bags occasionally adhere to the plexus choroides, and are sometimes described as hydatids, although they are more transparent in their coats.

It is conjectured, that they are formed by distention of the vein which runs along the edge of the plexus choroides. Round tumours of a scrofulous nature are sometimes found adhering to the plexus choroides.

PINEAL GLAND.

A little phosphate of lime, varying in quantity, and easily separable by slight pressure, is very often found in the gland.

Pus has been found in the substance of the gland, and so have hydatids.

There are several cases on record of the gland degenerating into a large cyst, filled with a limped fluid.

PITUITARY GLAND.

This gland is rarely diseased.

NERVES WITHIN THE CRANIUM.

It seldom happens that any of the nerves within the cranium appear diseased, although sometimes they are found increased in volume, in consequence of serous, gelatinous, or fatty depositions in their tissue. At other times they are compressed, flattened, or displaced, in

consequence of the development of tumours in the surrounding parts; and their atrophy, which sometimes depends upon the same cause, may also be the result of the cessation of their functions (paralysis).

* Inflammation of the nerves (neuritis) appears to be a more common disease than is generally believed. It is often observed in cases of neuralgia, a disease which, however, frequently presents no appreciable alteration of the nervous tissue. It is in part to a sub-inflammatory state of nerves, that we must attribute their softening, and the tuberculous and scirrhus tumours, designated collectively by the name neuroma. To the same cause may also be referred the cartilaginous and osseous metamorphosis of the nerves; a kind of alteration, which is sometimes, though rarely, observed, and is

Most of the diseased alterations of the cerebral structure, and its investing membranes, produce much less intellectual derangement, than might be expected. The sensorial derangement may sometimes indicate, although obscurely, the site of the disorganization; as,

I. Injury or disease of the anterior lobes of the brain affect the speech in some degree.

confined to some insulated points of these organs. The volume of the nerves is much greater, in proportion to that of the encephalo-rachidian centre, when they are examined near the period of conception. In old age, they are smaller, more dry and firm than in the adult life, at the same time that their vitality is less energetic.

II. When the corpus striatum, that is, the anterior part of the striated nucleus, is injured, the motions of the legs are disordered and impaired; and when the optic thalamus, or the posterior region of the striated nucleus is injured, the motions of the arms are impaired.

III. It is very much doubted, whether lesions of the middle lobe of the cerebellum have a particular influence on the organs of generation; but disease of the cerebellum often impairs the memory, and also voluntary motion.*

* The solutions of continuity of the brain and spinal marrow, when they do not ter-

INFLAMMATION OF THE ARACHNOID MEM-
BRANE AND PIA MATER OF THE SPINAL
CORD.

Symptoms.—Pain, more or less violent, extending along the vertebral column; tetanic contraction of the muscles of the back and neck, accompanied with soreness of the integuments covering the vertebræ.

minate fatally, heal like those of the other organs, either by immediate re-union, or by the formation of a brain-like substance, which is deposited upon the points that have been left open from the loss of substance, or by the simple separation of the lips of the wound.

MORBID ANATOMY.

Appearances similar to those already enumerated under the head of Meningitis of the Brain.

SOFTENING OF THE MEDULLA OBLONGATA
AND SPINALIS.

When softening is seated in the pons varolii, and particularly when the affection extends to the crura cerebri, the power of utterance is lost, the paralysis becomes general, and death takes place at a very early period.

When softening appears to be in some

part of the medulla spinalis, and that part can be assigned by considering the functions of the nerves which arise from it, the effects are such as are known to be produced by injuries of them. For instance, the transmission of feeling takes place by means of the posterior part of the spinal marrow, and that of motion by means of its anterior part.

Case.—Inflammation and softening of the spinal cord.

Symptoms.—Pain in the left side of the neck, weakness and flying pain in the arms, pain in the head, a diffused swelling in the

neck, paralysis of the arms, but their sensibility retained, the lower extremities in a similar state, embarrassed speech, dyspnœ, emaciation, delirium, death.

Dissection.—After removing the integuments, and raising the sterno-cleido muscle, and pneumo-gastric nerve, an abscess was discovered opposite the transverse processes of the cervical vertebræ, of the size of an egg, containing yellow and thick matter. When a probe was passed into the abscess, it penetrated into the spinal canal. The vertebral column was then laid open throughout its whole extent. The posterior columns of the medulla spinalis were found softened to the consistence of cream, from the first

cervical vertebra to the third or fourth dorsal. This softening or diffuence was greatest at the surface, and gradually diminished as the centre of the chord was approached. The anterior portion of the spinal marrow was slightly softened also, but infinitely less so than the posterior. About the middle of the cervical region, two small holes were found in the bodies of the vertebræ, leading to the external abscess. The transverse processes were here carious. In the head, the arachnoid was found greatly injected, and adherent in some places to the pia mater, as was the latter to the substance of the brain.

Case.—A man, forty-five years old, of a weak constitution, having remained sixty days on his back, was attacked with a large

eschar on the sacrum, which destroyed the spinous process of this bone, and exposed the vertebral canal, into which pus had insinuated itself.

On opening him, liquid was found, not only between the two folds of the arachnoid, and beneath the pia mater, the whole length of the medulla spinalis, but even in the fourth ventricle, the aqueduct of sylvius, the third and lateral ventricles. During life, however, the patient had never manifested the slightest symptom of inflammation of the covering of the spinal marrow, the brain, or medulla spinalis; and he had had neither paralysis, nor convulsions, nor disorder in his intellectual functions.

SEROUS EFFUSION IN THE SPINAL CANAL.

Case.—Child, *Ætat* twelve, after appearing to be in much pain, lost the use of the inferior extremities, and died in three days. The spinal canal was found full of bloody serum.

Case.—Paralysis of the upper and lower extremities. This patient died of gradual exhaustion, a year after the first appearance of the paralysis. Through the whole extent of the spinal cord, there was a space betwixt its dura and pia mater full of serous fluid. There was also some effusion on the brain.

SPINAL APOPLEXY.

Case.—A young lady, aged fourteen, had head-ach, and pain in the back, with a tendency to sickness on sitting up. At the end of a week, there was a sudden and violent aggravation of the pain, followed by general convulsions, which were fatal in five or six hours.

The spinal canal was found filled with extravasated blood in the lumbar region, which had been the seat of the pain. The brain and all the other viscera were sound.

SPINA BIFIDA.

This consists of a watery tumour, of the colour of the skin, situated within the

sheath of the spinal marrow, and protruding in the course of the spine. Where it protrudes, there is a considerable vacancy betwixt the two vertebræ immediately above and below it. This disorder is congenital, and it usually occurs at the lower part of the spine, but occasionally take place at the cervical vertebræ, where the tumour has the same characteristic marks as those presented by it, when it occurs near the sacrum.

MORBID ANATOMY.

On opening the tumour, a transparent fluid escapes, like serum, or the fluid of

dropsy. This fluid is contained in a cyst, ordinarily formed of the spinal membranes or arachnoid, and dura mater, the vascularity of which is increased, and they are mostly covered with common integuments. One or more of the spinous processes, and sometimes some of the lateral bridges or processes are wanting from original defective formation. The tumour is often local, but an opening or cavity may be sometimes traced from the tumour, along the course of the spinal marrow to the head. There is an opening into the spinal canal, the size of which depends upon the number of spinous and lateral processes deficient; or upon the size of

the division or cleft in the posterior part of the spine; but there may be a considerable tumour when the spinal opening is very small. When spina bifida is combined with hydrocephalus, the cavity, containing the fluid of the former disease, can be traced from the spine to the ventricles, or to the anterior fontanelle.

OSSIFICATION OF THE MEMBRANES.

In a woman, who had been subject to epileptic fits for five years, and who died suddenly, osseous scales, from one to two lines in diameter, were found on the sheath of the spinal cord, completely covering it through its whole extent.

HYDATIDS.

Hydatids have been found imbedded in the substance of the spinal cord.

Case.—Inflammation and ulceration of the spinal marrow.

Symptoms.—Pain in the back, paralysis of the lower extremities, retention of urine and involuntary discharge of fæces, uneasiness and sense of distention at the upper part of the abdomen; loss of appetite, fever, quick pulse, and profuse perspiration.

Dissection.— Upon opening the spinal sheath, a milky fluid was found within it, just above the cauda equina, and higher than this, for the space of three inches, the spinal

marrow was ulcerated to a considerable depth, and was in the softened state, which the brain assumes when it is rendered semi-fluid by putrefaction.

ATROPHY OF THE SPINAL MARROW,

Occasionally occurs in old age when the canal is of its natural calibre. The lumbar portion of the spinal marrow, as well as the lumbar nerves, has been found withered in patients who have died affected with paraplegia. Atrophy of the spinal marrow and loss of continuity occur in epileptic, idiotic, hemiplegic, and paraplegic subjects, and in those affected with spinal distortions from the ulcera-

tive or progressive absorption of the vertebræ.

FRACTURE OF THE SPINE.

Case.—A man, *Ætat* sixty-three, fell from a load of hay backwards, and struck the back of his neck violently against the ground.

Symptoms.—When the head was elevated, he complained of excruciating pain; indistinct speech, paralysis of the upper and lower extremities which were destitute of sensation, suppression of urine.—Death.

Dissection.—Upon making an incision along the spinous processes of the cervical vertebræ, blood in considerable quantities was observed to be extravasated. The spi-

nous process of the fourth cervical vertebra (reckoning from the atlas), with that portion of the vertebra constituting the back part of the medullary canal, was broken off from the body of the vertebra. It was quite loose, and only required to be dissected from the surrounding muscular substance to be removed. Its inferior edge was advantageously situated for making compression upon the medulla spinalis, and probably was driven upon it at the time the blow was inflicted. The medulla was not at all lacerated, nor did it exhibit any mark of long continued compression. Upon puncturing its investing membrane, a quantity of serous fluid escaped. It could not be discovered that the body of the vertebra was injured.

GANGLIONIC NERVES.

They have been known to be inflamed in cases of neuroses of the abdominal organs, and in subjects who have died from pertussis ; they are also sometimes affected with atrophica and hypertrophica, especially when the organs to which they are distributed, present the same pathological condition.

Bichat once found the semi-lunar ganglion more dense, and in another instance more voluminous than natural ; this last anomaly was accompanied by the presence of a cartilaginous substance in

the centre of it: the subject that presented it had died in consequence of a periodical mania.

*Pathological appearances presented in the
Brain and its membranes of the insane
dead.**

1. Case of cheerful monomania.—The dura mater much injected, and adhering in many places to the pia mater, the latter softened, the brain pale, and rather softer than natural; cerebral convolutions effaced; right ventricle full of water; cerebellum and spinal marrow sound.

* Lunatic Hospital of Turin. Med. Chir. Review, 1831.

2. Melancholic monomania, with tendency to suicide.—Membranes of the brain gorged with blood; no other unusual appearance in the head.

3. Mania with chorea.—Effusion under the arachnoid; cerebral substance hard and much injected; sanguineous effusion into the spinal canal, with traces of inflammation along the spinal marrow.

4. Mania which terminated in idiocy.—Brain very much softened, with much serum in the ventricles.

5. Suicidal mania.—Meninges and cerebral substance highly injected.

6. Mania with pride.—Meninges thickened and injected, having the appearance

of parchment; strong adhesions between the two hemispheres; brain itself much injected.

7. General mania.—Much effusion between the membranes of the brain; pia mater inflamed even to suppuration; cerebellum sound.

8. Melancholia.—Cerebral meninges injected.

of the ...
 the ...
 ...
 ...
 ...
 ...
 ...
 ...




Plate 1.



EXPLANATION OF THE PLATES.

PLATE I.

This plate represents a fracture of the right parietal bone.

- a.* A portion of the parietal bone depressed.
- b.* Integuments of the head thrown back.


PLATE II.

Inflammation of the dura mater.

- a.* An injected and arborescent appearance of the capillary vessels of the dura mater.
- b.b.* Pus and coagulable lymph.
- c.* Integuments of the head thrown back.
- d.* Cut surface of the skull.

Plate 2.

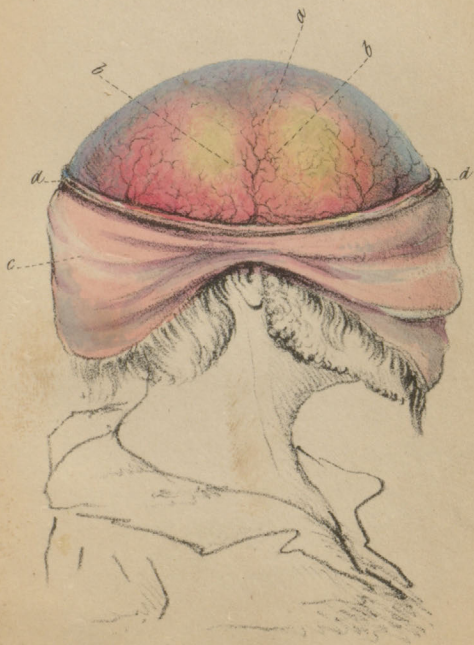






Plate 3.



PLATE III.

Inflammation of the arachnoid membrane.

The skull cap is removed, and the integuments are thrown over the occiput.

a. The arachnoid membrane thickened, and opaque, and the convolutions of the brain are imperfectly seen through it.

Lymph is also observed lying between it and the pia mater.

PLATE IV.

These sketches are intended to represent acute inflammation of the pia mater, and softening of the medullary substance of the brain.

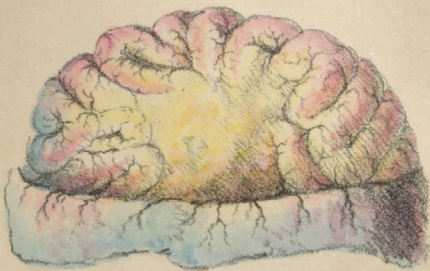Fig. 1.

The dura mater is reflected, and the bright red colour of the pia mater is beautifully seen as well as the lymph which is deposited on the surface of the hemisphere, and between the convolutions of the brain.

Fig. 2.


Softened state of the medullary matter of the brain.

Fig. 1.



2








Plate 5.

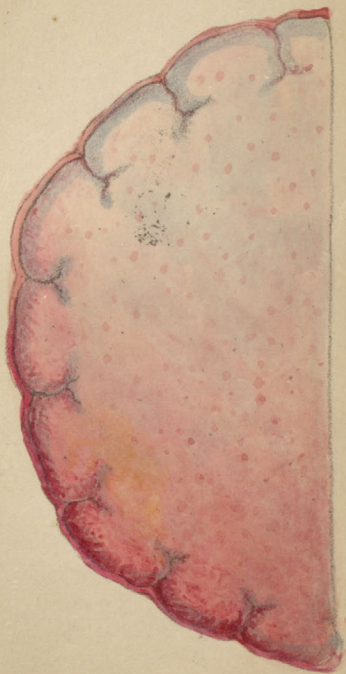

PLATE V.

An intense inflammation of the substance of the brain.

The pia mater, covering the posterior and lateral portions of the hemisphere of the brain, was highly injected, and of a bright scarlet colour.

The medullary substance was also very red and soft, and in the centre of this disorganized mass was deposited a quantity of pus.

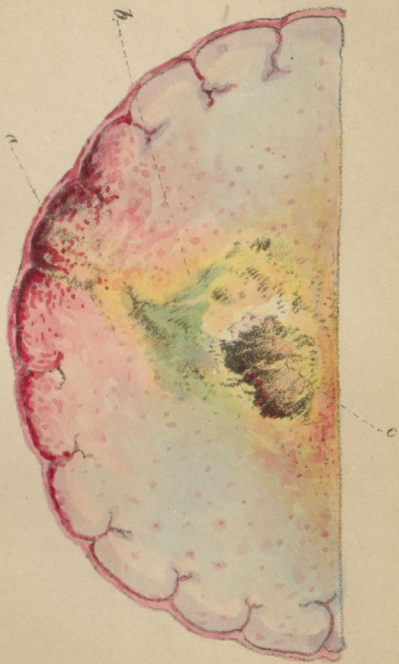
The vessels of the substance of the hemispheres were surecharged with blood, and when sliced their surfaces presented numerous bloody points.

PLATE VI.

An abscess in the substance of the left hemisphere of the brain.

- a.* Inflammation of the pia mater, accompanied with a softened state of the cortical substance of the brain.
- b.* A quantity of pus incorporated with the medullary matter of the brain.
- c.* An abscess in the substance of the brain just above the corpus callosum.

Plate 6.








Plate 7.

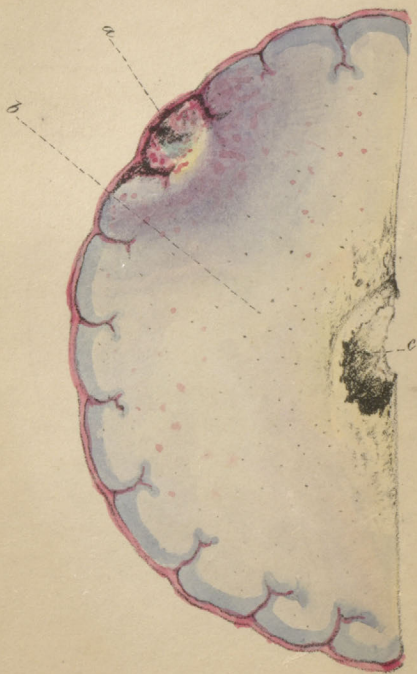

PLATE VII.

Ulceration of the cortical and medullary substance of the left hemisphere.

a. Ulceration of the cortical substance of the brain, with an injected state of the pia mater covering the diseased portion.

b. The surrounding cerebral matter rather firmer than natural, and very much dotted with red points.

c. A deep excavation at the inner and lower part of the hemisphere.

The bottom of the wound was parallel with the corpus callosum. Its edges were elevated and irregular.

PLATE VIII.

This plate represents some of the morbid appearances generally met with in apoplexy.

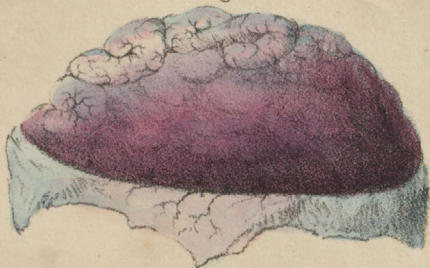
Fig. 1.

An extravasation of blood between the pia and dura mater; the latter membrane is reflected so as to expose the coagula lying on the convolutions of the brain.

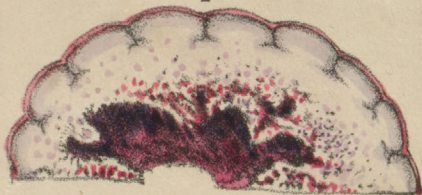
Fig. 2.

An apoplectic cavity formed in the centre of the medullary substance of the hemisphere of the cerebrum. The internal surface of the cavity was irregular and

Figl.




2



3





flocculent; and the cerebral matter, surrounding it, was softened, and very much injected with blood.

Fig. 3.

In this case the optic thalamus was softened, and in its centre were several apoplectic cells containing coagula.

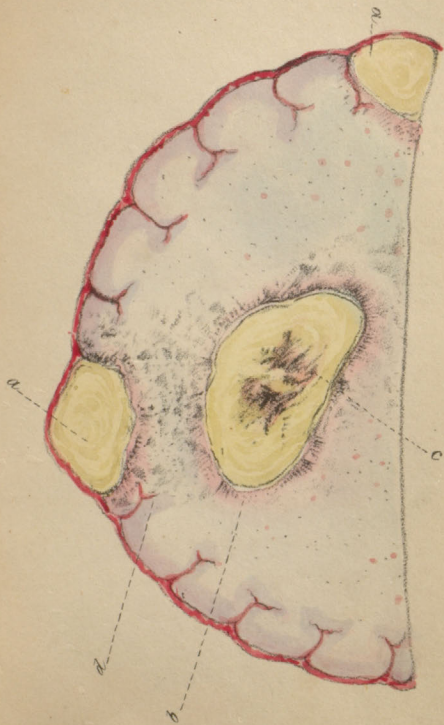PLATE IX.


Scrofulous tubercles in the substance of the brain.


- a.* An indurated tubercle situated in the cortical substance of the brain.
- b.* Condensed cellular tissue forming the capsule of the tubercle.
- c.* Softening of the centre of the tubercle.
- d.* Cerebral matter, surrounding the tumours, in a softened state.

When these tumours are sliced, their surfaces present a yellowish-white appearance, resembling the interior of a horse-chestnut, and are generally of a caseous consistence.

Plate 9.







Figl.



2.



3.

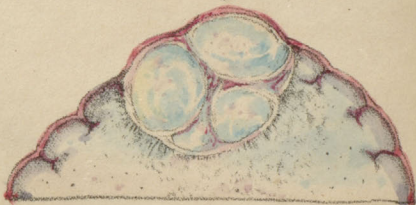


PLATE X.

Partial induration of the brain, scirrhus and encephaloid tumours embedded in the substance of the cerebrum.

Fig. 1.


A portion of the medullary matter of the left hemisphere was found indurated, and when sliced presented a greyish-yellow surface. The surrounding texture was softened, but not discoloured.

Fig. 2.

A tumour of a greyish-white colour, intersected by fibrous septa, embedded in the centre of the medullary matter.

Fig. 3.

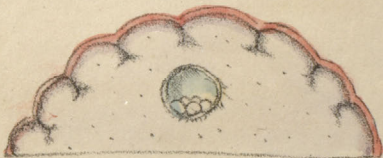An encephaloid tumour in the substance of the brain ; it was lobulated, indurated, intersected by cellular bands, and of a greyish-white colour.



1



2



3

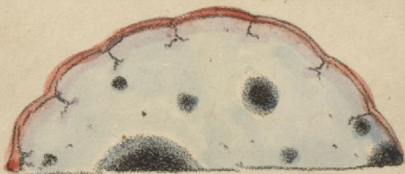

PLATE XI.

These sketches represent calcareous matter ;
hydatids and melanotic matter in the
substance of the brain.

Fig. 1.

Calcareous deposition in the substance of
the cerebral matter.

Fig. 2.

One large hydatid, containing numerous
smaller ones within it, situated in the
cerebral substance.

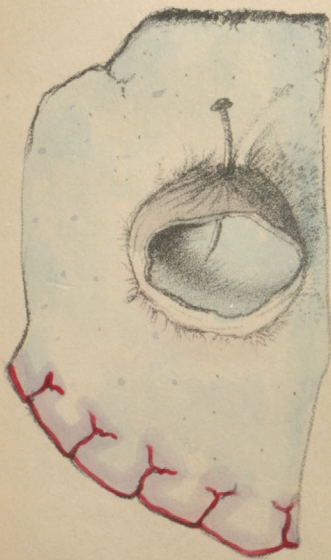
Fig. 3.

Deposition of melanotic matter in the sub-
stance of the cerebrum.

PLATE XII.

A very large cyst embedded in the substance
of the cerebrum.

Plate 12.








Fig 1.

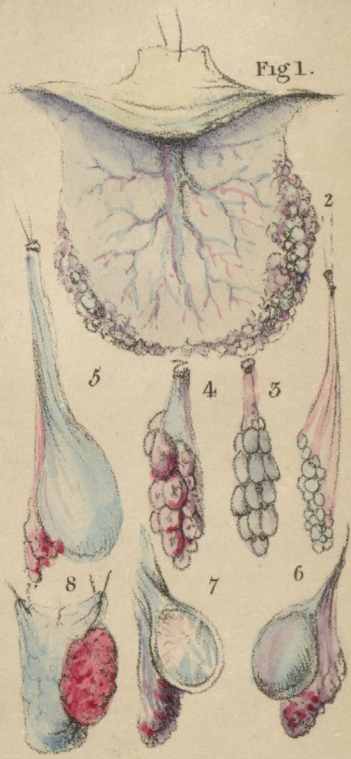


PLATE XIII.

Fig. 1.

Vesiculated state of the plexus choroides.

Fig. 2.

Grey semi-transparent tubercles, of the size described in the sketch, and perfectly globular, situated in the plexus choroides.

Fig. 3.

Distinct vesicles adhering to the plexus choroides, with vessels seen on the surface.

Fig. 4.

Small fleshy tumours arising from the plexus choroides.

Fig. 5.

A large cyst arising from the velum interpositum.

Fig. 6.

Fibro-cartilaginous tumour arising from the plexus choroides.

Fig. 7.

Perpendicular section of a fibro-cartilaginous tumour.

Fig. 8.

Fungus on the under surface of the velum interpositum,

INDEX.

	PAGE
ADHESION of the dura mater to the bones	8
to the membranes	33
Adipose tumours in the brain	80
Air in the veins	56
Abscess in the brain	62
cerebellum	64
Anasarcaous state of the brain	103
Apoplexy symptoms	106
Morbid Anatomy	108
meningeal	106
cerebral	<i>ib.</i>
blood effused in clots in the cerebral substance	107
blood effused over the surface of the brain	<i>ib.</i>
blood in the ventricles	<i>ib.</i>
blood effused from softening	109
blood effused at different pe- riods	110

	PAGE
Apoplexy, Case	111
spinal	132
Analysis of the brain	17
cartilage	35
bone	37
melanotic matter	87
the fluid in hydrocephalus	100
Aneurisms of the carotid arteries	115
Arteries diseased	109
ossification	113
cartilaginous	<i>ib.</i>
calcareous depositions	<i>ib.</i>
Case	115
Arachnoid membrane	11
its course	12
inflammation	38
Morbid Anatomy	39
thickened	40
milky	39
covered with a false membrane	40
rough and granu- lated	<i>ib.</i>
cartilaginous	<i>ib.</i>
ossification of	41
of the spinal mar- row	125
Arsenic, death from	48
Atrophy of the brain	73
nerves	123

	PAGE
Atrophy of the spinal marrow	137
Arms impaired from lesion of the optic thalamus	124
Bones of the skull increased in thickness	6
Bone of the skull resembling ivory	7
spiculæ of	<i>ib.</i>
fractures and fissures	6
deposite between the laminæ of the dura mater	37
analysis	<i>ib.</i>
deposite between the laminæ of the arachnoid membrane	40
pia mater	59
in the substance of the brain	88
in the membranes of the spinal marrow	135
to prepare for dissection	6
Brain, the mode of examining	14
healthy appearance	<i>ib.</i>
of the fœtus, child, infant, and in old age	<i>ib.</i>
slicing the better way of examin- ing it	15
grey substance	<i>ib.</i>
presides over in- tellectual power	16
white, and the deep-seated grey mass over locomotion	<i>ib.</i>
white substance softer around the	

ventricles than towards the surface	16
Brain removed from the skull . . .	19
concussion	25
Morbid Anatomy	27
with fracture	28
with extravasation of blood	<i>ib.</i>
inflammation of its substance . . .	59
Morbid Anatomy	60
abscess	62
Morbid Anatomy	<i>ib.</i>
cerebellum	64
ulceration	<i>ib.</i>
Morbid Anatomy	65
Case	<i>ib.</i>
softening	66
Morbid Anatomy	67
Case	70
ditto	<i>ib.</i>
induration	<i>ib.</i>
Morbid Anatomy	72
atrophy	73
tumours on its surfaces	74
partial induration	<i>ib.</i>
serofulous tumours	75
exist in various parts of the Brain	<i>ib.</i>
tubercles the size of a pea, &c. . . .	76

	PAGE
Brain, Case	77
flesh-like tumours	78
Case	79
adipose tumours	80
Case	<i>ib.</i>
scirrhus tumours	81
Case	82
encephaloid tumours	84
encysted tumours	83
fungus melanodes	85
melanosis	86
analysis of	87
bone in its substance	88
Case	89
cavities	90
Case	91
blood cyst	92
Case	93
hydatids	94
Case	97
fluid in the ventricles	98
change of colour	116
Case	<i>ib.</i>
hypertrophy	118
Case	<i>ib.</i>
an injury of the anterior lobes	
affect the speech	123
and spinal marrow heal like other	
organs	125

	PAGE
Caries of the bones of the skull	6
Carbonic acid, death from	49
Cerebral nerves	19
Child's brain	15
Cholera morbus	42
Concussion of the brain	25
Morbid Anatomy	27
with fracture	28
extravasation of blood	<i>ib.</i>
Cornua ammonis	19
Contusions before death	2
after death	<i>ib.</i>
Corpora striata	16
Corpus callosum	<i>ib.</i>
Death from arsenic	48
carbonic acid	49
sulphuric acid	48
sulphurated hydrogen	49
by hanging	50
strangulation	<i>ib.</i>
drowning	<i>ib.</i>
from Prussic acid	51
Delirium tremens	41
Dementia	71
Dura mater	8
sinuses gorged with blood	<i>ib.</i>
pus or blood effused	9
colour	<i>ib.</i>

	PAGE
Dura mater, division	9, 10
inflammation	30
Morbid Anatomy	31
Idiopathic case of inflammation	32
Case	43
adhesions	33
softening	<i>ib.</i>
ulceration	34
scrofulous tumours	<i>ib.</i>
thickened	35
of a fibro-cartilaginous texture	<i>ib.</i>
fungoid tumours	36
ossified	37
Case	38
Ecchymosis	2
Effusion of blood after the termination	
of softening	109
into the substance of the brain	107
on the surface of the brain	<i>ib.</i>
into the ventricles	<i>ib.</i>
of fluid into the ventricles	98
between the pia mater and brain	57
of water between the pia mater	
and arachnoid membrane	58
Encephaloid tumours	83
Encysted tumours	84

	PAGE
Erysipelas	47
Explanation of the plates	145
External appearance of the head and face	1
Falx cerebri	10
Fissures and fractures of the bones of the head	6
Flesh-like tumours in the brain	78
Fluid in the ventricles	98
in the skull and spinal canal	17
Fornix	16
Fractures easily distinguished	28
of the bones during life	<i>ib.</i>
after death	<i>ib.</i>
of the spine	138
Fungus melanodes	85
of the velum interpositum	160
of the dura mater	36
Ganglionic nerves	140
Gangrene on the living body	3
dead	<i>ib.</i>
dry	<i>ib.</i>
Gland, Pacchionian	9
pineal	120
pituitary	121
Hanging, death by	50

	PAGE
Hemispheres flattened	11
mode of examining	14
Hydatids	94
in the brain	97
in the substance of the spinal cord	136
in the pineal gland	121
Hydrophobia	44
Hydrocephalus, acute	98
chronic	<i>ib.</i>
Morbid Anatomy	100
fluid analysis	<i>ib.</i>
with protrusion of the brain	104
Hypertrophy of the brain	118
nerves	121
Idiopathic inflammation of the dura mater	32
Idiotism	72
Induration of the brain	70
partial	74
Inflammation of the pericranium	23
dura mater	30
idiopathic	32
arachnoid mem- brane	38
pia mater	43
veins	49

	PAGE
Inflammation of the veins	54
brain	59
ventricles	98
nerves	122
Insanity	71
Mania	<i>ib.</i>
Medulla oblongata and spinalis softening	126
Meningeal apoplexy	106
Monomania	71
Morbid anatomy of the pericranium	23
of abscesses	62
of apoplexy	108
of the arachnoid mem- brane	39
of the arteries	113
of the brain	60
of concussion	27
of congestion	48
of the choroïd plexus	120
of cholera morbus	42
of delirium tremens	41
of the dura mater	31
of erysipelas	47
of hydrophobia	44
of hydrocephalus	100
of induration of the brain	72
of the pineal gland	120


	PAGE
Morbid Anatomy of the pia mater . . .	43
of softening of the	
brain	67
of the spinal sheath	125
of spina bifida	133
of typhus fever	41
of ulceration of the	
brain	65
of the veins	49
 Nerves within the cranium	 121
increased in volume	<i>ib.</i>
flattened	<i>ib.</i>
inflammation	122
softening	<i>ib.</i>
scirrhus tumours of	<i>ib.</i>
ganglionic	140
small in old age	123
large in the foetus	<i>ib.</i>
 Optic thalami	 16
 Putrefaction	 3
first stage	4
second ditto	5
third ditto	<i>ib.</i>
fourth ditto	<i>ib.</i>
 Pia mater	 12
distinction between conges- tion and inflammation	 <i>ib.</i>


	PAGE
Pia mater between the convolutions . . .	13
in the ventricles	<i>ib.</i>
of the medulla spinalis . . .	125
inflammation	43
veins, congestion of	47
Morbid Anatomy	48
congestion of vessels	<i>ib.</i>
veins containing air	56
water under it	57
scrofulous tumours	<i>ib.</i>
water between it and the arachnoid membrane . . .	58
cysts adhering to the . . .	<i>ib.</i>
ossification of	59
Pineal gland	120
degenerated into a cyst . . .	121
Pachionian gland	9
Pituitary gland	121
Phosphate of lime in the pineal gland	120
Pus in the gland	121
effused on the dura mater . . .	9
in the substance of the brain . . .	62
Plexus choroides	120
vesiculated state of . . .	159
large cyst adhering to . . .	<i>ib.</i>
Post mortem examination, a form for facilitating the record of	21
Pericranium, inflammation of	23
Morbid Anatomy	24

	PAGE
Pericranium, inflammation, Case . . .	25
Prussic acid, death by	51
Phthisis pulmonalis	51
Pons varolii	16
Sinuses of the dura mater gorged with blood	8
Softening of the dura mater	33
brain	66
nerves	122
medulla oblongata and spinal marrow	126
Spinal marrow, its sheath	20
atrophy	137
canal, serous effusion in	131
Case	<i>ib.</i>
apoplexy	135
Spinal marrow, ossification of its mem- branes	<i>ib.</i>
Spine fracture	138
Spina bifida	132
Spots on the head and face	1
Sugillation	2
Scrofulous tumours of the dura mater	34
pia mater	57
brain	76
plexus choroides	120
Strangulation	50
Sulphuric acid, death from	48


	PAGE
Sulphurated hydrogen, death from . . .	49
Suppuration of the veins	53
of the dura mater	9
of the brain	62
Typhus fever	41
Tumours, scrofulous	34
fungoid	36
cartilaginous	35
scrofulous	57
indurated tubercles	74
scrofulous	75
flesh-like	78
adipose	80
scirrhus	81
encysted	83
fleshy	159
fibro-cartilaginous	160
Vitreous table of the skull	8
Ventricles	16
parts within	18
containing blood	107
containing a serous fluid	101
Vertebral column, method of opening	20
Veins, inflammation	49
distinction between absorption and inflammation	52
coats thickened	53

	PAGE
Veins, suppuration of	53
ulceration of	<i>ib.</i>
exudation of albumen	<i>ib.</i>
Case	54
containing air	56
Velum interpositum	160
fungus arising from it	<i>ib.</i>
Ulceration of the dura mater	34
veins	53
brain	64
Wounds before death	2
after	<i>ib.</i>
death before inflammation	
commences	3





#1293801182



d

